

## A Rare but Life-threatening Condition: Spontaneous Rupture of the Spleen

Yassine Zerhari\*, Hajar Zebbakh, Asaad El Bakkari, Hatim Essaber, Soukaina Alloui, Hounayda Jerguigue, Youssef Omor, and Rachid Latib

Radiology Department of national institute of oncology of Rabat. Morocco

\*Corresponding author: Yassine Zerhari, Radiology Department of national institute of oncology of Rabat. Morocco.

Submitted: 24 September 2024 Accepted: 01 October 2024 Published: 02 December 2024

Citation: Yassine Zerhari, Hajar Zebbakh, Asaad El Bakkari, Hatim Essaber, Soukaina Alloui, et al. (2024) A Rare but Life-Threatening Condition: Spontaneous Rupture of the Spleen Sci Set Jour Radiology 1(4), 01-03.

### Abstract

Spontaneous rupture of the spleen is a rare but serious medical condition that can lead to life-threatening internal bleeding. Prompt diagnosis and treatment are essential for a successful recovery. In this article, we present a case of spontaneous rupture of the spleen and discuss the imaging features that aided in the diagnosis, as well as the differential diagnosis, treatment, and prevention of this condition.

**Keywords:** Spontaneous Rupture of the Spleen, Internal Bleeding, CT, Ultrasound, Differential Diagnosis.

### Case Presentation

A 45-year-old male with a history of cirrhosis presented to the emergency department with sudden onset of severe left upper abdominal pain. He had no history of trauma or recent infection. On physical examination, his blood pressure was 80/50 mmHg, and his heart rate was 120 beats per minute. Abdominal examination revealed tenderness in the left upper quadrant, and he had a positive Murphy's sign.

Laboratory studies showed a hemoglobin level of 9 g/dL and a platelet count of 80,000/mm<sup>3</sup>. An abdominal ultrasound (Figure 1) than a CT scan of the abdomen was performed (Figure 2) showed an enlarged spleen with a large amount of peri-splenic fluid consistent with splenic rupture. Emergency surgery was performed, and the patient underwent a splenectomy with a transfusion of two units of packed red blood cells.

### Figure and Relevant Captions:

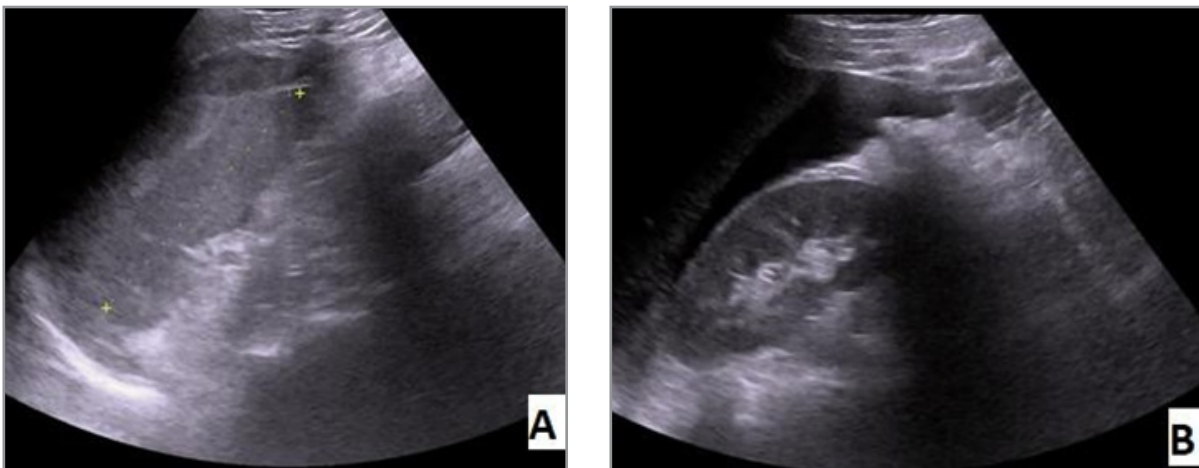
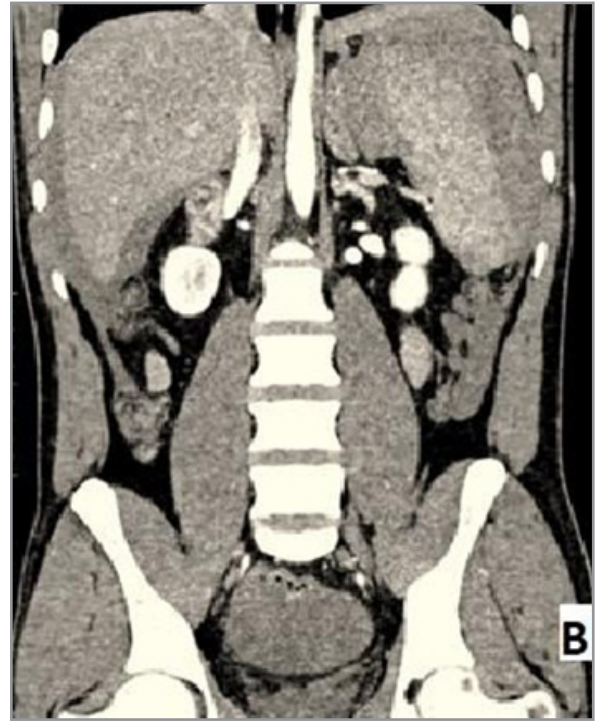
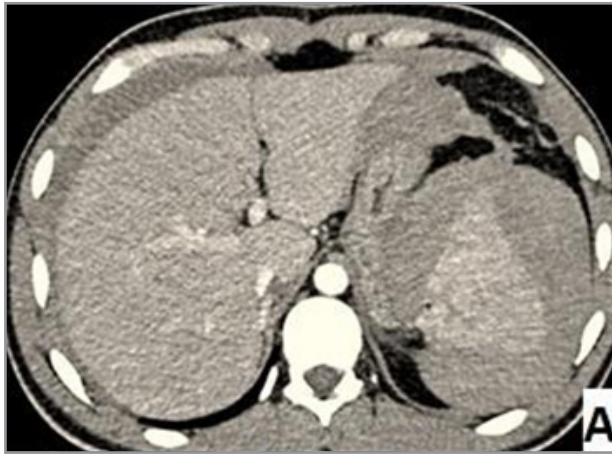

Figure 1 (A, B): an ultrasound abdominal showing heterogeneous spleen with peri- splenic fluid



**Figure 2:** CT in Axial Section (A), and Coronal Section (B) after injection of contrast agent showed an enlarged spleen with a large amount of peri-splenic fluid

### Discussion

Spontaneous rupture of the spleen is a rare condition that can be caused by various underlying medical conditions. Differential diagnosis of spontaneous rupture of the spleen can be challenging because the symptoms can be similar to those of other medical conditions that present with acute abdominal pain [1].

Acute pancreatitis, acute cholecystitis, and aortic aneurysm are among the conditions that should be considered when evaluating a patient with abdominal pain. Acute pancreatitis typically presents with upper abdominal pain that radiates to the back and is associated with nausea, vomiting, and fever. Acute cholecystitis, on the other hand, presents with right upper abdominal pain that may be accompanied by nausea and vomiting.

Aortic aneurysm is a potentially life-threatening condition that presents with sudden onset of severe abdominal pain that radiates to the back. Imaging studies such as ultrasound and CT are critical in distinguishing between these conditions and splenic rupture [2].

Surgical removal of the damaged spleen is the most common treatment for splenic rupture. The surgery is usually performed as an emergency procedure and involves removing the spleen and stopping the bleeding. Blood transfusions may also be necessary to replace the lost blood [1, 2].

In some cases, conservative management with close monitoring and supportive care may be an option. However, this approach carries a significant risk of complications such as delayed rupture or recurrent bleeding.

Prevention of spontaneous rupture of the spleen involves managing underlying medical conditions that can increase the risk of rupture [3]. Infections such as mononucleosis, bacterial endocarditis, and malaria can all lead to an enlarged spleen and increase the risk of rupture [4].

It is important to treat these infections promptly and effectively to prevent complications such as splenic rupture. Blood disorders such as leukemia and lymphoma can also lead to an enlarged spleen and increase the risk of rupture. Treatment for these conditions may involve chemotherapy or radiation therapy to shrink the spleen and reduce the risk of rupture. Liver disease such as cirrhosis can also lead to an enlarged spleen and increase the risk of rupture. Managing liver disease and avoiding alcohol and other substances that can cause liver damage can help reduce the risk of splenic rupture.

In conclusion, spontaneous rupture of the spleen is a rare but serious medical condition that requires prompt medical attention. Imaging studies such as CT and ultrasound play a critical role in diagnosing splenic rupture. Treatment typically involves surgical removal of the damaged spleen and blood transfusions. Managing underlying medical conditions and avoiding activities that can cause trauma to the abdomen can help prevent spontaneous rupture of the spleen.

### Funding Information

No funding was given

### Conflict of Interest

All authors declare no conflict of interest relevant to this article.

---

## References

1. Rhee SJ, Sheena Y, Imber C (2008) Spontaneous rupture of the spleen: a rare but important differential of an acute abdomen. *Am J Emerg Med* 26: 733-735.
2. Lieberman ME, Levitt MA (1989) Spontaneous rupture of the spleen: a case report and literature review. *Am J Emerg Med* 7: 28-31.
3. Gorg C, Colle J, Gorg K (2003) Spontaneous rupture of the spleen: ultrasound patterns, diagnosis and follow-up. *Br J Radiol* 76: 704-711.
4. Farley DR, Zietlow SP, Bannon MP (1992) Spontaneous rupture of the spleen due to infectious mononucleosis. *Mayo Clin Proc* 67: 846-853.