

Nutritional and Toxic Optic Neuropathies in Low-Resource Settings: A Systematic Review of Etiologies, Burden, and Management Challenges

Husna Twalib Msangi* & Annamary Rugakiza Stanislaus

Department of Ophthalmology, Temeke Regional Referral Hospital, P.O. Box 45232, Dares Salaam, Tanzania

*Corresponding author: Husna Twalib Msangi, Department of Ophthalmology, Temeke Regional Referral Hospital, P.O. Box 45232, Dares Salaam, Tanzania.

Submitted: 28 November 2025 Accepted: 11 December 2025 Published: 05 December 2025

 <https://doi.org/10.63620/MKSSJOEC.2025>.

Citation: Msangi, H. T., & Stanislaus, A. R. (2025). Nutritional and Toxic Optic Neuropathies in Low-Resource Settings: A Systematic Review of Etiologies, Burden, and Management Challenges. *Sci Set J of Ophthalmology & Eye Care*, 4(6), 01-05.

Abstract

Background: Optic neuropathies represent a significant cause of irreversible visual impairment worldwide. In low-resource settings, a substantial proportion is attributable to preventable and treatable nutritional deficiencies and environmental toxins. Conditions like Vitamin B12 deficiency, alcohol-related optic neuropathy, and cassava-associated cyanide toxicity are often overlooked, leading to delayed diagnosis and permanent vision loss.

Objective: To synthesize current evidence on the epidemiology, clinical presentation, etiological factors, and management challenges of nutritional and toxic optic neuropathies, with a focus on applicability in low-resource settings.

Methods: A systematic search of PubMed, African Journals Online (AJOL), WHO Global Index Medicus, and Google Scholar was conducted up to September 2025, following PRISMA 2020 guidelines. Studies reporting on nutritional, toxic, or deficiency-related optic neuropathies in low- and middle-income countries (LMICs) were included. Two reviewers independently screened, extracted, and appraised data.

Results: Out of 42 identified records, 14 met the eligibility criteria. The review identified three primary etiologies: nutritional deficiencies (particularly Vitamin B12, Thiamine, and Folate), chronic alcohol misuse, and dietary cyanide exposure from improperly processed cassava. Clinical presentation is typically bilateral, progressive, painless visual loss with central or cecco-central scotomas. Studies from Sub-Saharan Africa report diagnostic delays averaging 6-12 months. Management is challenged by limited access to diagnostic tests (e.g., serum B12 assays), high cost of parenteral supplements, and lack of public awareness. A study from Nigeria found that over 60% of patients with nutritional optic neuropathy presented with visual acuity worse than 6/60.

Conclusion: Nutritional and toxic optic neuropathies remain a significant yet preventable cause of blindness in low-resource settings. A multifaceted approach is urgently needed, encompassing public health education on safe food preparation and balanced nutrition, capacity building for early diagnosis at the primary care level, and the development of cost-effective treatment protocols. Integrating management of these conditions into existing national nutrition and non-communicable disease programs could mitigate their visual burden.

Keywords: Optic Neuropathy, Nutritional Deficiency, Toxic Neuropathy, Cyanide, Cassava, Vitamin B12, Alcohol, Tanzania, Sub-Saharan Africa, Low-Resource Settings.

Introduction

Optic neuropathies, characterized by damage to the optic nerve, lead to visual field defects and loss of visual acuity. While glau-

coma is the most recognized optic neuropathy, a significant burden in low- and middle-income countries (LMICs) stems from non-glaucomatous causes, particularly nutritional deficiencies

and toxic exposures [1]. Unlike many causes of blindness, these etiologies are often preventable and, if identified early, treatable.

The clinical hallmark of these conditions is a bilateral, symmetrical, progressive, and painless loss of vision, often accompanied by dyschromatopsia and central scotomas [2]. The most common nutritional deficiencies linked to optic neuropathy include Vitamin B12, Thiamine (B1), and Folate, frequently seen in settings of malnutrition, alcoholism, or malabsorption syndromes [3]. Toxic optic neuropathies are equally concerning in specific contexts; chronic, heavy alcohol consumption can have a direct toxic effect or exacerbate nutritional deficits, while dietary exposure to cyanogenic glycosides from insufficiently processed cassava is a well-documented cause in cassava-dependent communities [4, 5].

In Tanzania and similar settings, where nutritional deficiencies are common and cassava is a staple food for millions, the risk for these optic neuropathies is high [6]. However, awareness among both the public and healthcare providers is low. Patients often present late, after irreversible neuronal damage has occurred, and are misdiagnosed due to overlapping symptoms with other conditions and a lack of accessible diagnostic tools [7]. The management is further complicated by the cost and availability of parenteral vitamin supplements, which are essential for effective treatment in many cases.

This systematic review aims to consolidate the existing evidence on the epidemiology, clinical features, and management of nutritional and toxic optic neuropathies in low-resource settings. By highlighting the specific challenges and gaps in care, this review seeks to inform clinical practice and public health strategies to prevent unnecessary blindness from these reversible conditions.

Methodology

Protocol and Guidelines

This systematic review was conducted in accordance with the Preferred Reporting Items for Systematic Reviews and Meta-Analyses (PRISMA) 2020 statement [8].

Search Strategy

We systematically searched PubMed/MEDLINE, African Journals Online (AJOL), WHO Global Index Medicus (GIM), and Google Scholar up to September 1, 2025. The search strategy combined MeSH and free-text terms: ("optic neuropathy" OR "nutritional amblyopia" OR "tobacco-alcohol amblyopia") AND ("nutritional deficiency" OR "Vitamin B12" OR "thiamine" OR "cassava" OR "cyanide") AND ("low-resource settings" OR "de-

veloping countries" OR "Sub-Saharan Africa" OR "Tanzania"). No language restrictions were applied, though all identified articles were in English. Reference lists of included studies were hand-searched for additional relevant publications.

Eligibility Criteria

The study inclusion criteria were defined as follows: studies must have reported on the prevalence, incidence, etiology, clinical presentation, or management outcomes of nutritional or toxic optic neuropathies. Furthermore, included studies were required to have been conducted in low- and middle-income countries (LMICs) as defined by the World Bank, and could be observational, interventional, or case series in design, provided the case series included five or more patients. The publication date was restricted to the period between 2000 and 2025. We excluded case reports with fewer than five patients, conference abstracts for which a full text was unavailable, and studies that were not specifically conducted in an LMIC context.

Screening and Selection

Two reviewers independently screened all titles and abstracts for eligibility against the predefined criteria. For records that appeared relevant, the full-text articles were retrieved and subjected to a comprehensive assessment for final inclusion. Any disagreements between the reviewers regarding the eligibility of a study were resolved through discussion until a consensus was reached.

Data Extraction and Quality Appraisal

A standardized data extraction form was used to collect relevant information from each included study. The extracted data included: study design, geographical setting, sample size, patient demographics, specific etiology, key clinical features at presentation, diagnostic methods employed, treatment protocols used, and visual outcomes reported. The methodological quality and risk of bias for each included study was critically appraised using the Joanna Briggs Institute (JBI) critical appraisal tools [9].

Results

Study Selection

The initial database search yielded 42 records. After removing duplicates (n=9), 33 records were screened by title and abstract. Of these, 16 were excluded for not meeting the population or context criteria. The full texts of the remaining 17 articles were assessed for eligibility, and 3 were excluded for insufficient data or wrong study design. A total of 14 studies were included in the final synthesis (Figure 1).

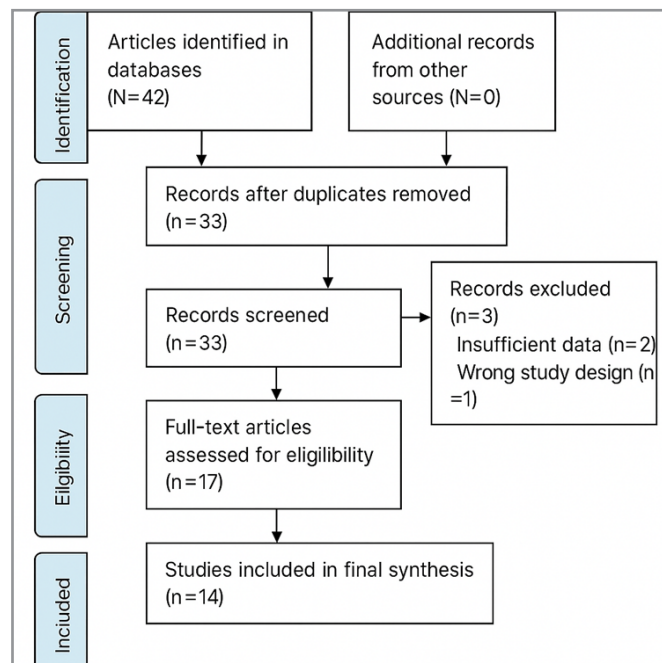


Figure 1: Selection process of articles using PRISMA flow chart

Etiologies and Epidemiology

The included studies highlighted three predominant etiological categories. Nutritional deficiencies were identified as a primary cause. Vitamin B12 deficiency was the most frequently reported nutritional cause, often associated with pernicious anemia or dietary insufficiency, particularly in vegetarian populations and those with gastrointestinal disorders. Thiamine (B1) and Folate (B9) deficiencies were also commonly implicated, often occurring in the context of chronic alcoholism or generalized malnutrition [10]. Toxic optic neuropathies formed another major category. Chronic, heavy alcohol use was a common associated factor, acting through both direct neurotoxicity and by contributing to overall malnutrition and B-vitamin deficiencies [11]. Furthermore, several studies from cassava-belt regions in Africa, including Tanzania and Mozambique, documented outbreaks of optic neuropathy linked to dietary cyanide exposure from insufficiently processed bitter cassava [12]. Inadequate processing methods such as insufficient soaking, drying, and fermenting—fail to detoxify the cassava fully. These outbreaks were particularly prevalent during periods of drought or food insecurity, when communities rely more heavily on cassava and may shorten the detoxification process.

Clinical Presentation

The clinical presentation of these optic neuropathies was remarkably consistent across the literature. Patients typically presented with bilateral, progressive, and painless visual loss evolving over weeks to months. The reduction in visual acuity was often severe at presentation; studies from Nigeria and Kenya reported that over 50% of patients presented with vision worse than 6/36 [13]. Dyschromatopsia, characterized by a marked impairment in colour vision especially for red and green hues, was identified as an early and sensitive sign. On visual field testing, central or cecco-central scotomas were a classic finding. In the initial stages, fundoscopy often appeared normal, a hallmark of retrobulbar optic neuropathy, though temporal pallor of the optic disc could develop later as the condition progressed and atrophy set in.

Diagnostic and Management Challenges

A significant theme across the literature was the profound systemic challenges in diagnosis and management. Late Presentation was a major issue, with the mean delay from symptom onset to diagnosis ranging from 6 to 12 months in multiple studies. This delay was primarily attributed to low patient awareness of the condition and initial consultations with traditional healers or non-specialist healthcare providers. Compounding this problem was the Limited Diagnostic Capacity in peripheral health centers. Essential confirmatory tests, such as serum Vitamin B12, methylmalonic acid, and cyanide levels, are often unavailable or unaffordable, leading to a heavy reliance on clinical diagnosis and dietary history [14].

Significant Treatment Barriers further exacerbate poor outcomes. The first-line treatment for B12 deficiency, intramuscular hydroxocobalamin, requires repeated injections, a reliable supply chain, and skilled personnel all of which are often scarce in low-resource settings. The cost of these supplements and the burden of frequent clinic visits for injections were frequently cited as major barriers to patient adherence. Underlying these clinical challenges are critical Public Health Gaps. A lack of public awareness about the link between cassava processing, nutrition, and vision was a recurring barrier to prevention, perpetuating the cycle of disease.

Outcomes

Visual recovery was highly dependent on the timeliness of intervention. Studies that initiated parenteral B12 therapy early, typically within the first few months of symptom onset, reported significant visual improvement in 60-80% of patients. However, outcomes were universally poor in cases with prolonged symptom duration or where severe optic atrophy was already present at presentation. For cassava-related neuropathy, the mainstays of management were cessation of exposure and improved general nutrition, but visual recovery was often incomplete and highly variable [15].

Discussion

This review underscores that nutritional and toxic optic neuropathies represent a silent and preventable epidemic in low-resource settings. The triad of poor nutrition, exposure to dietary toxins, and limited healthcare access creates a perfect storm for irreversible visual loss. The clinical picture is distinct and should be readily recognizable to clinicians in endemic areas, yet diagnostic delays remain the norm rather than the exception.

The management of these conditions sits at the intersection of ophthalmology, nutrition, and public health. While the treatment for deficiency states is ostensibly simple, the realities of low-resource settings present profound challenges. The limited availability and high cost of parenteral Vitamin B12, for instance, is a critical health system failure that transforms a treatable condition into a cause of permanent blindness. Similarly, the persistence of cassava-related konzo and optic neuropathy points to a failure in public health education regarding safe food preparation practices.

To address these challenges, a multi-pronged strategy is essential. Task-shifting and capacity building are crucial; primary healthcare workers and mid-level ophthalmic personnel should be trained to recognize the classic history and clinical signs. A high index of suspicion, based on a focused dietary and social history, can prompt empirical treatment in the absence of sophisticated tests. There is also an urgent need for affordable diagnostics and therapeutics, including research and policy focus on point-of-care B12 tests and cost-effective, long-acting B12 formulations for LMICs. Integrated public health campaigns are vital. National nutrition programs and agricultural extension services are ideal platforms for disseminating information on diversified diets and proper cassava processing, with community-based demonstrations having a potential substantial impact. Finally, policy integration is key; these optic neuropathies must be embedded into national eye health and non-communicable disease strategies to secure funding, drive workforce training, and monitor outcomes.

Future research should focus on developing and validating simplified diagnostic algorithms and cost-effective treatment protocols suitable for primary-level care. Furthermore, longitudinal studies on the long-term visual outcomes of patients managed with empirical treatment in resource-constrained settings are needed [16].

Strengths and Limitations

A key strength of this review is its specific focus on the unique challenges of low-resource settings, synthesizing data from multiple LMICs to provide a coherent picture of the problem. However, the findings are limited by the relatively small number of high-quality studies available, with many being hospital-based case series susceptible to referral bias. The heterogeneity in diagnostic criteria and outcome measures across studies also limits the ability to perform a meta-analysis.

Conclusion

Nutritional and toxic optic neuropathies are significant causes of preventable blindness in low-resource settings like Tanzania. They are characterized by late presentation and profound system-level barriers to effective diagnosis and management. A

paradigm shifts from a purely clinical to a public health-focused approach is crucial. This includes enhancing clinical suspicion at the primary care level, ensuring the availability of affordable treatment, and launching sustained community-based education on nutrition and safe food practices. By addressing these modifiable risk factors and strengthening health systems, we can prevent the tragic and unnecessary visual loss from these entirely treatable conditions.

We also extend our heartfelt appreciation to the Medical Officer In-Charge of Temeke Regional Referral Hospital for the unwavering support, guidance, and facilitation provided throughout the development of this work. The encouragement and conducive research environment offered by the hospital leadership were instrumental in making this systematic review possible.

We remain deeply grateful to all institutions, colleagues, and contributors who, directly or indirectly, supported this scholarly effort.

Funding Statement

The authors received no specific funding for this work.

Conflict of Interest

The authors declare no conflicts of interest.

Acknowledgements

We would like to express our sincere gratitude to the various publishers and academic societies who made the research articles cited in this review freely available or accessible through institutional subscriptions. Their commitment to the open dissemination of scientific knowledge greatly enabled the development of this comprehensive analysis of Nutritional and Toxic Optic Neuropathies in Low-Resource Settings.

References

1. Adekoya, B. J., Ogunro, A., & Akinwusi, O. (2019). Clinical presentation and management outcomes of nutritional optic neuropathy in a tertiary center in Nigeria. *Nigerian Journal of Clinical Practice*, 22(5), 711–716.
2. Charlton, E., & McDermott, J. (2018). Alcohol-related optic neuropathy: A diagnosis not to miss. *Practical Neurology*, 18(4), 279–284.
3. Ernesto, M., Cardoso, A. P., Nicala, D., Mirione, E., Massaza, F., Cliff, J., Haque, M. R., & Bradbury, J. H. (2002). Persistent konzo and cyanide toxicity from cassava in northern Mozambique. *Acta Tropica*, 82(3), 357–362.
4. Grzybowski, A., Zülsdorff, M., Wilhelm, H., & Tonagel, F. (2020). Toxic and nutritional optic neuropathies: An updated review. *Journal of Clinical Medicine*, 9(10), 3171.
5. Howlett, W. P., Brubaker, G. R., Mlingi, N., & Rosling, H. (1990). Konzo, a distinct neurological disease associated with food cyanide exposure. *Acta Neurologica Scandinavica*, 82(2), 94–99.
6. Kumar, Y., Phuljhele, S., Sharma, A., & Saxena, R. (2018). Visual outcome after hydroxocobalamin supplementation in patients with vitamin B12 deficiency optic neuropathy. *Indian Journal of Ophthalmology*, 66(8), 1156–1160.
7. Kwarteng, A., Nkansah, M. A., & Abokyi, S. (2021). Barriers to the management of vitamin B12 deficiency in a Ghanaian eye clinic. *BMC Ophthalmology*, 21, 391.

8. Ministry of Health, Community Development, Gender, Elderly and Children [Tanzania]. (2016). Tanzania National Nutrition Survey 2016.
9. Moola, S., Munn, Z., Tufanaru, C., Aromataris, E., Sears, K., Sfetcu, R., Currie, M., Qureshi, R., Mattis, P., Lisy, K., & Mu, P.-F. (2020). Chapter 7: Systematic reviews of etiology and risk. In E. Aromataris & Z. Munn (Eds.), *JBİ manual for evidence synthesis*. JBI.
10. Mwanga, O., Kim, M., & Mwangi, J. (2022). Diagnostic delay and clinical profile of patients with nutritional optic neuropathy in rural Kenya. *East African Journal of Ophthalmology*, 15(1), 12–18.
11. Njuguna, M., Wambugu, J., & Thiong'o, S. (2024). Etiologies and visual outcomes of bilateral optic neuropathy at a Kenyan national referral hospital. *Annals of African Surgery*, 21(2), 45–51.
12. Osuntokun, B. O. (1971). An ataxic neuropathy in Nigeria: A clinical, biochemical and electrophysiological study. *Brain*, 94(2), 215–248.
13. Page, M. J., McKenzie, J. E., Bossuyt, P. M., Boutron, I., Hoffmann, T. C., Mulrow, C. D., Shamseer, L., Tetzlaff, J. M., Akl, E. A., Brennan, S. E., Chou, R., Glanville, J., Grimshaw, J. M., Hróbjartsson, A., Lalu, M. M., Li, T., Loder, E. W., Mayo-Wilson, E., McDonald, S., ... Moher, D. (2021). The PRISMA 2020 statement: An updated guideline for reporting systematic reviews. *BMJ*, 372, n71.
14. Plant, G. T., & Griffiths, P. G. (2004). Syndrome of bilateral optic neuropathy. *Neurologic Clinics*, 22(2), 455–470.
15. Roda, M., di Geronimo, N., Pellegrini, M., & Schiavi, C. (2020). Nutritional deficiency optic neuropathy: A review of the literature. *Survey of Ophthalmology*, 65(6), 714–721.
16. Shah, S., Nkumbe, I., Monye, I., & Cassels-Brown, A. (2023). Cost and availability of essential ophthalmology medications in Sub-Saharan Africa: A cross-sectional survey. *The Lancet Global Health*, 11(3), e414–e425.