

Comparison Tap Bloc + Pararectal with ESP Bloc for Laparoscopic Gallbladder Surgery

Tommaso Di Ieso*

Clinical Vesuvius Naples

*Corresponding author: Dr. Tommaso Di Ieso, Clinical Vesuvius Naples.

Submitted: 20 May 2024 Accepted: 27 May 2024 Published: 03 June 2024

Citation: Tommaso Di Ieso (2024) Comparison Tap Bloc + Pararectal with ESP Bloc for Laparoscopic Gallbladder Surgery. J Clin surg Care Res 3(3), 01-04.

Introduction

Laparoscopic gallbladder surgery has now become a consolidated technique that allows the performance of the surgery in day surgery [1, 2]. Laparoscopic techniques allow to congratulate the recovery of the patient allowing much faster recovery times: in particular the cholecystectomy performed by laparotomy involved recovery times of about a month while the execution of the same surgery by laparoscopic route allows the recovery of the patient in ten to fifteen days.

The main problem to be addressed has always been related to the management of post-operative pain.

Pain, in fact, can result in slowing down the resumption of movement and, consequently, slower recovery times.

The use of opioid analgesics also slows down the recovery because, while giving excellent analgesia, they still cause a slowdown of intestinal transit and can give nausea that prevents the resumption of feeding [3].

Following the introduction of the ultrasound under anesthesia, wall blocks began to be performed for post-operative analgesia with medium-long duration. It has been seen that the learning curve of such blocks is relatively low and allows, with a few precautions, to reduce or eliminate opioids altogether in the post-operative.

For laparoscopic cholecystectomy, in particular, the use of the TAP bloc has been introduced with various methods to which to flank the pararectal block to cover the pain of the subcostal breach [4, 5].

The introduction, then, of the ESP bloc opened up new horizons of comparison for its ease of execution and security [6-8].

Tap Bloc

The TAP bloc is a wall block that is intended to ensure analgesia and/or anesthesia for wall surgery. It has little or no effect on visceral pain [9-11].

It is performed at a patient lying down and, the traditional method involves feeling the loss of resistance to the passage of the band between internal oblique muscle and transverse muscle. Thanks to the ultrasound it is possible to perform the TAP block by looking exactly at the route of the needle and observing the separation of the band between the two muscles while injecting the anesthetic. The echo-guided method can be performed either anteriorly, or laterally or by introducing the needle from the anterior route going down the fascia until it reaches the square muscle of the loins: they inject part of the anesthetic in this place it is possible to practice the block of the square muscle of the loin II which allows, therefore, to obtain partial reduction of visceral pain.

Pararectal Block

The pararectal block was born as a wall block to perform umbilical hernia interventions in case of small hernias [12].

The traditional method involves the perpendicular introduction of a needle into the skin that must be raised and pulled at about 3-4 cm laterally to the navel. Loss of resistance during introduction indicates reaching the space to inject.

With the use of the ultrasound, on the other hand, it is possible to view the fascia that lines the muscles of the abdomen and allows you to introduce the needle under vision under both the upper and lower band and to inject the anesthetic under vision.

ESP Bloc

The ESP bloc is a newly introduced anesthetic block that involves the detection, under ultrasound guidance, of the fascia below the elevator muscle of the spine. The ultrasound technique involves placing a linear probe on the spine in the longitudinal direction and moving laterally to it, to the right and left, following the shadow of the transverse processes and then the ribs (if at the thoracic level): the point of passage from the transverse process to the rib is the point where the injection of local anesthetic is performed. The spread of the anesthetic, as demonstrated by studies on corpses with methylene blue, makes it possible to cover from two metamers above up to four below the injection site.

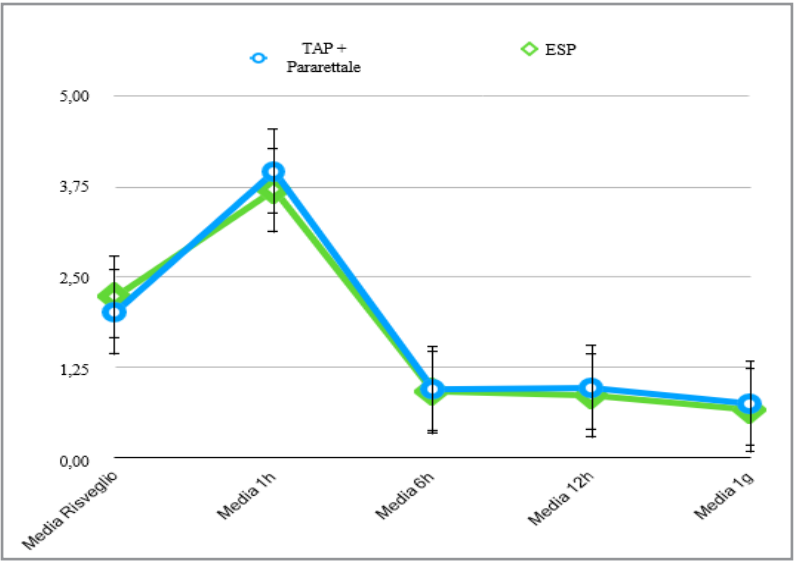
This block also partly covers visceral pain.

Materials and Methods

In the facility where I am now responsible for the anesthesia service, until 2022 about fifteen - twenty gallbladders were operated per year with traditional methods for the management of post- operative pain (continuous infusion and/or intravenous and/or orous infusion drugs).

Since March 2023 I have introduced the execution of wall blocks for the management of post- operative pain and we have increased the number of cholecystectomies performed to about sixty- eighty a year.

The increase in the number of interventions has grown thanks to the collaboration between the surgical and anesthesiological team and thanks to the reduction in the patient's recovery time: the



NRS

	TAP + Pararettale	ESP
Numero casi	55,00	35,00
Media Risveglio	2,02	2,23
D.S.	1,31	0,81
E.S.	0,18	0,14
Media 1h	3,96	3,71
D.S.	0,94	0,96
E.S.	0,13	0,16
Media 6h	0,95	0,91
D.S.	0,40	0,45
E.S.	0,06	0,08
Media 12h	0,96	0,86
D.S.	0,58	0,60
E.S.	0,08	0,10
Media 1g	0,75	0,66
D.S.	0,52	0,54
E.S.	0,07	0,09

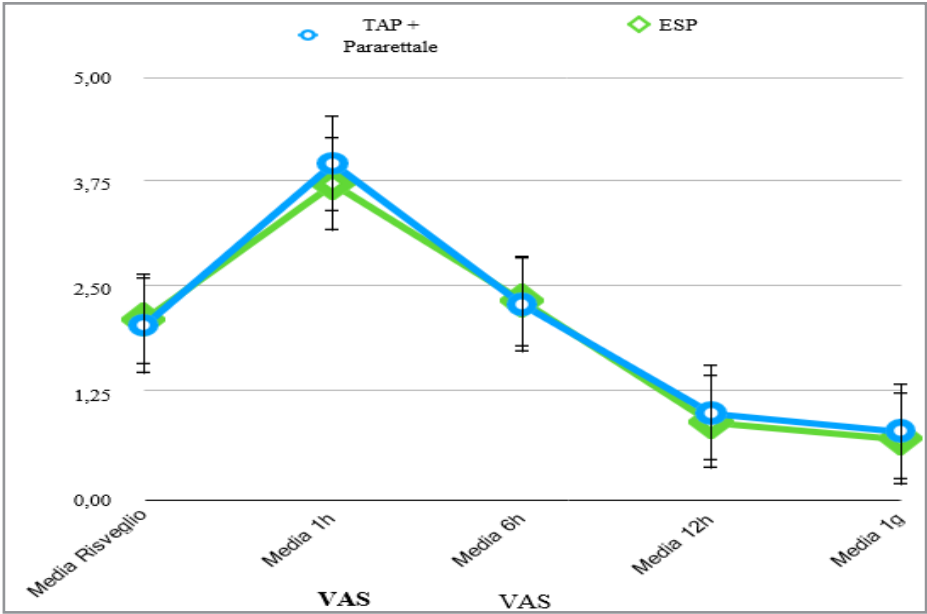
NRS
execution of wall blocks makes it possible not to use opioid analgesics in the management of post- operative pain.

To demonstrate the validity of our assertions, we divided the patients into two groups named TAP + Para and ESP, male and female in equal distribution, aged 25 to 80 years, and assessed pain on the NRS and VAS scale upon awakening, one hour, six hours and twelve hours after surgery. Each patient underwent general anaesthesia induced with propofol at 2.5 mg/kg, remifentanyl at 0.25 mcg/kg/min and cis-Atracurium at 0.2 mg/kg. During the surgical procedure, then, remifentanyl was reduced to 0.075 mcg/kg/min and anaesthesia was maintained with Sevoflurane at 1%, O2 at 35% and N2O at 65%.

In the TAP + Pararectal group, after inducing anaesthesia, TAP block was performed on the subcostal and bisiliac line with 20 ml of 0.25% ropivacaine per injection site. Pararectal anesthesia was also performed with 6 ml of ropivacaine 0.25% per side.

In the ESP group, however, before inducing anaesthesia, a patient seated, bilateral ESP block was performed at T11-T12 with 20 ml of Ropivacaine 0.25% per side.

The differences were studied with Fisher's test.



VAS

	TAP + Pararettale	ESP
Numero casi	55,00	35,00
Media Risveglio	2,02	2,09
D.S.	1,31	0,74
E.S.	0,18	0,13
Media 1h	3,96	3,71
D.S.	0,94	0,96
E.S.	0,13	0,16
Media 6h	2,27	2,31
D.S.	0,78	0,87
E.S.	0,11	0,15
Media 12h	0,96	0,86
D.S.	0,58	0,60
E.S.	0,08	0,10
Media 1g	0,75	0,66
D.S.	0,52	0,54
E.S.	0,07	0,09

Results

The first difficulty was to make it clear that the time lost at the beginning of the operation (initially about 20 min, then reduced to 12 min) allowed a greater speed in waking up.

The second difficulty was that of the learning curve: faster that for the TAP block and the Pararectal, a little slower that of the EPS.

The third difficulty is to get the patient to accept two stings in the back before general anesthesia: often the patient rejects the pain and that is why there are fewer patients in the ESP group.

In any case, as can be seen in the graphs and data collected, there is no statistically significant difference between the two groups.

The only difference, not constant, is the possibility of reducing the pain from irritation of the frenic nerve with the ESP block.

The TAP block, arriving at the square block of the loins II by the anterior route also covers, only in part, visceral pain. However, it does not act on the phrenic.

Conclusion

The use of wall blocks has proved to be an excellent analgesic method that, without the use of opioids, allows good control of post-operative pain.

From the published data it can be concluded that both methods have the same success rate and both would allow day-day discharge from the patient undergoing laparoscopic cholecystectomy. However, surgeons are still reluctant to this practice so, at the moment, discharge takes place 24-36 hours after the surgery.

Although not shown in the graph, 'traditional' analgesia was performed by elastomer loaded for 24 hours at 2 ml/h with 90 mg of Ketorolac, 300 mg of Tramadol and 16 mg of Ondansetron with nausea and difficulty getting out of bed until the day after surgery.

References

1. Vaughan J, Nagendran M, Cooper J, Davidson BR, Gurusamy KS (2014) Anaesthetic regimens for day-procedure laparoscopic cholecystectomy. *Cochrane Database Syst Rev* 24: CD009784.
2. Gurusamy K, Junnarkar S, Farouk M, Davidson BR (2008) Meta-analysis of randomized controlled trials on the safety and effectiveness of day-case laparoscopic cholecystectomy. *Br J Surg* 95: 161-168.
3. E. Aziz, Nathan B, McKeever J (2000) Avicenna, Anesthetic and analgesic practices in Avicenna's Canon of Medicine. *Am J Chin Med* 28: 147-151.
4. Dubost, Blot R.-M, Hérliche C. Transversus abdominis plane block (TAP block).
5. Theissen A, Niccolai P, Waqas Sultan, Michel Carles (2014) Blockages and infiltrations of the abdominal wall and perineum. *EMC - Anesthesia-Resuscitation* 19: 1-15.
6. De Cassai A, Geraldini F, Costa F, Tulgar S (2022) Local anesthetics and erector spinae plane blocks a spotlight on pharmacokinetic considerations and toxicity risks. *Expert Opin Drug Metab Toxicol* 18: 537-539.
7. Chin KJ, El-Boghdadly K (2021) Mechanisms of action of the erector spinae plane (ESP) block a narrative review. *Can J Anaesth* 68: 387-408.
8. Liang X, Zhou W, Fan Y (2021) Erector spinae plane block for spinal surgery: a systematic review and meta-analysis. *Korean J Pain* 34: 487-500.
9. Abdallah FW, Laffey JG, Halpern SH, Brull R (2013) Duration of analgesic effectiveness after the posterior and lateral transversus abdominis plane block techniques for transverse lower abdominal incisions: a meta-analysis. *British Journal of Anaesthesia* 111: 721-735.
10. Baciarello M, Migliavacca G (2016) TAP block and chronic abdominal pain. In: Fusco P, Marinangeli
11. F. Ultrasound-guided nerve blocks of the trunk and abdominal wall, Edizioni Edra, Milan 87-92.
12. Mukhtar K Singh S (2007) Transversus adbominis plane block for laparoscopic surgery. *British Journal of Anaesthesia* 104: 193-197.