

Ceramic Implants - The Best Aesthetic and Reliable Solution for Root Fractures (Clinical Case)

Dovgerd AA^{1,2*}

¹LLC "Stoma", Kemerovo, Assistant of the Department of Maxillofacial Surgery and General Dentistry of the NSUU FSBEI DPO RMANPO of the Ministry of Health of the Russian Federation, Novokuznetsk, Russia

²Novokuznetsk State Institute of Advanced Medical Training-Branch of the Federal State Budgetary, Institution of Advanced Medical Training of the Ministry of Health of the Russian Federation, Novokuznetsk, Russia

*Corresponding author: Alexander A DOVGHERD, LLC "Stoma", Kemerovo, Russia. Tel: +7 (913) 402302.

Submitted: 15 March 2024 Accepted: 21 March 2024 Published: 05 April 2024

Citation: Alexander A DOVGHERD (2024) Ceramic Implants - The Best Aesthetic and Reliable Solution for Root Fractures (Clinical Case). *J Clin Den & Oral Care* 2(2), 01-05.

Annotation

The subject of the study is the prospects of introducing an endossal all-ceramic immediate implant in the clinical practice of orthopedic rehabilitation of patients with dental root fractures in the aesthetic zone.

Objective: to conduct a comparative analysis of changes in the state of bone and soft tissue according to the data of targeted visio-graphic examination and clinical observation after the installation of a developed bio-implant made of zirconium dioxide in the area of the removed tooth root of the frontal group during trauma.

Methodology: The paper presents 2-month clinical results of monitoring the condition of bone and soft tissue in the area of tooth root fracture 1.1 after the installation of the developed bioimplant and simultaneous temporary prosthetics of the patient.

Results: Trauma to the anterior group of upper jaw teeth is not only functional, but also has a huge psychological impact on patients, especially on young and successful people. This group of patients does not have the opportunity to spend a lot of time on orthopedic rehabilitation; long, complex and traumatic surgical treatment with a large number of difficult to predict results and the use of various bone-plastic materials. The development of new dental implants, new technological solutions for manufacturing, new protocols with predictable clinical results — these are the tasks that we, dentists, need to solve. This is what modern society demands of us, and what patients expect of us. The development of new biocompatible materials and the improvement of technologies for obtaining surfaces with a given micro-roughness, new technologies for applying bio-coatings to the surface of a dental implant made of zirconium dioxide, and the improvement of clinical protocols made it possible to use such zirconium dioxide implants not only as a reliable support point for orthopedic restorations, but also as a "therapeutic tool" for the regeneration of bone defects.

The article presents 3-month clinical results on the restoration of bone tissue and preservation of soft gum tissues in the area of broken tooth 1.1, without the use of bone substitutes and soft gum tissue plasty, using a developed all-ceramic bio-implant and immediate prosthetics.

The new endosomal all-ceramic screw single-stage immediate implant developed by the author of the study (RF Patent for invention No. 2651052; Eurasian patent No. 035482) is distinguished by its design (rough active two-component thread that turns into a polished neck by switching the platform and then into the superstructure with the possibility of its individualization in the oral cavity) and the method of surface treatment exclusively of the threaded part of the implant with hydroxyapatite of calcium.

The development of the dental implant was carried out jointly with the technological production company MOJE Kераmик - Implant LLC.

The possibility of using the developed implant will meet the needs of patients for minimally invasive implantation procedures, ensuring its economic efficiency in relation to analog imported dental implant systems used in combination with bone substitutes. In addition, due to specialized surface treatment, the developed implant does not require the use of bone replacement drugs, and the presence of a bio-coating allows expanding its use in groups of patients with somatic pathologies.

Conclusions: *The presented case shows that the developed system of all-ceramic immediate implants is not only a reliable support for orthopedic restoration, but also restores bone tissue without the use of bone substitutes. This clinical observation allows us to recommend the use of the developed bio-implant in clinical dentistry.*

Keywords: Ceramic Implants, Zirconium Implants, Implant logical Treatment, New Developments, Bio-Implant, Trauma, Tooth Fracture

Introduction

At present, the current pace and standard of living of society requires fast, reliable and predictable solutions. A tooth root fracture is always an unpredictable situation and it is impossible to predict the injury. Modern, educated, active, young and successful patients are not ready to spend a lot of time on complex and long-term treatment in dentistry, they require reliable and predictable results "here and now". Attempts to stabilize the wreckage during a fracture tend to fail both early and in the long run. Which is expressed in patients' dissatisfaction with the demand and expectation. And the more perseverance is shown in an unsuccessful attempt to preserve the root of the tooth, the deeper trophic disorders occur in the surrounding bone tissue with subsequent destruction. It is the long-term trophic changes in bone tissue and, as a result, the resulting bone defects that are the main problem for one-stage implantation and require additional, complex, expensive and not always predictable reconstructive surgery. Timely removal of a broken tooth root and installation of a dental implant helps not only to prevent further spread of the infectious process, but also to conduct early orthopedic rehabilitation of the patient. Thanks to this, dental implantation has become the main method of rehabilitation in orthopedic dentistry. Therefore, the requirements for dental implants are increasing every day, both on the part of patients and dentists. Existing complications that occur during dental implantation require research and development to improve the effectiveness of orthopedic rehabilitation [1, 2].

Taking into account the disadvantages of titanium alloys and the growing needs of patients for safe and reliable dental implantation, in metal-free solutions for orthopedic rehabilitation, the development of new biocompatible materials, new technologies for obtaining surfaces with a given micro-roughness, new technologies for applying bio-coatings to the surface of a dental implant made of zirconium dioxide and improving clinical protocols made it possible to use such zirconium dioxide implants as alternatives to their titanium counterparts [3-6]. The integration of the ceramic implant into bone and soft tissues was tested and confirmed. We should also mention the rapid growth of soft gum tissue on the surface of the ceramic dental implant [7-11].

With the technological support of the production company MOJE Keramik - Implant LLC, taking into account all the advantages of using zirconium dioxide as a material for manufacturing, I, A. A. Dovgerd, developed and implemented a new endosseal all-ceramic screw one-stage immediate implant (RF Patent for invention No. 2651052; Eurasian Patent No. 035482).

Objective

To conduct a comparative analysis of changes in the state of bone and soft tissue according to the data of targeted visigraphic examination and clinical observation after the installation of a developed bio-implant made of zirconium dioxide in the area of the removed tooth root of the frontal group during trauma.

Clinical Picture

22.11.2023 a patient born in 1985 without smoking abuse, with complaints of a broken and movable tooth crown 1.1. From the anamnesis: in the evening of 21.11.2023, during a corporate dinner in her company, when eating, she felt a sharp pain in the tooth 1.1 and felt the mobility of the crown. The patient had great difficulty waiting for the morning opening hours of the dental clinic, as she was afraid to sleep and swallow a tooth in her sleep. Moreover, on 22.11.2023, an important event for her company was scheduled, which simply cannot be postponed or canceled. The patient actually demanded to solve her problem "here and now". Additionally, we learned from the medical history that in 2019, primary endodontic treatment of tooth 1.1 was performed for acute pulpitis; in 2021, repeated endodontic treatment was performed for exacerbation of chronic periodontitis and an orthopedic crown was made.

22.11.2023 by me Dovgerd A. A., conducted an external examination, studied the data of X-ray examination. When examined in the oral cavity, the ceramic crown on tooth 1.1 was significantly higher than the cutting edges of neighboring teeth, its mobility of 2-3 degrees and sharp pain during percussion were determined. Soft tissues in the tooth area were hyperemic, swollen, and bleeding was detected. On the target R-gram of good quality of the upper jaw in the area of tooth 1.1, in the projection of the upper 1/3 of the root, the fracture line was determined. Bone tissue without signs of chronic destruction. (Figure 1)

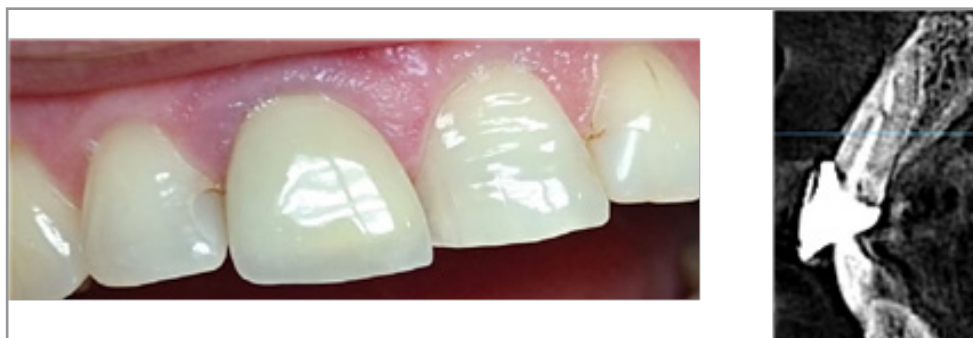


Figure 1: Clinical picture of the injury 1.1 and R-gram of the tooth area 1.1

After discussing various treatment strategies with the patient, the patient decided to remove and implant with immediate prosthetics. After local anesthesia, the orthopedic crown was removed, the root and broken fragment of the apex of tooth 1.1 were atrau-

matically removed, a developed allceramic immediate implant made of nanostructured zirconium dioxide with bio-coating was installed, and prosthetics were performed. (Figure 2)

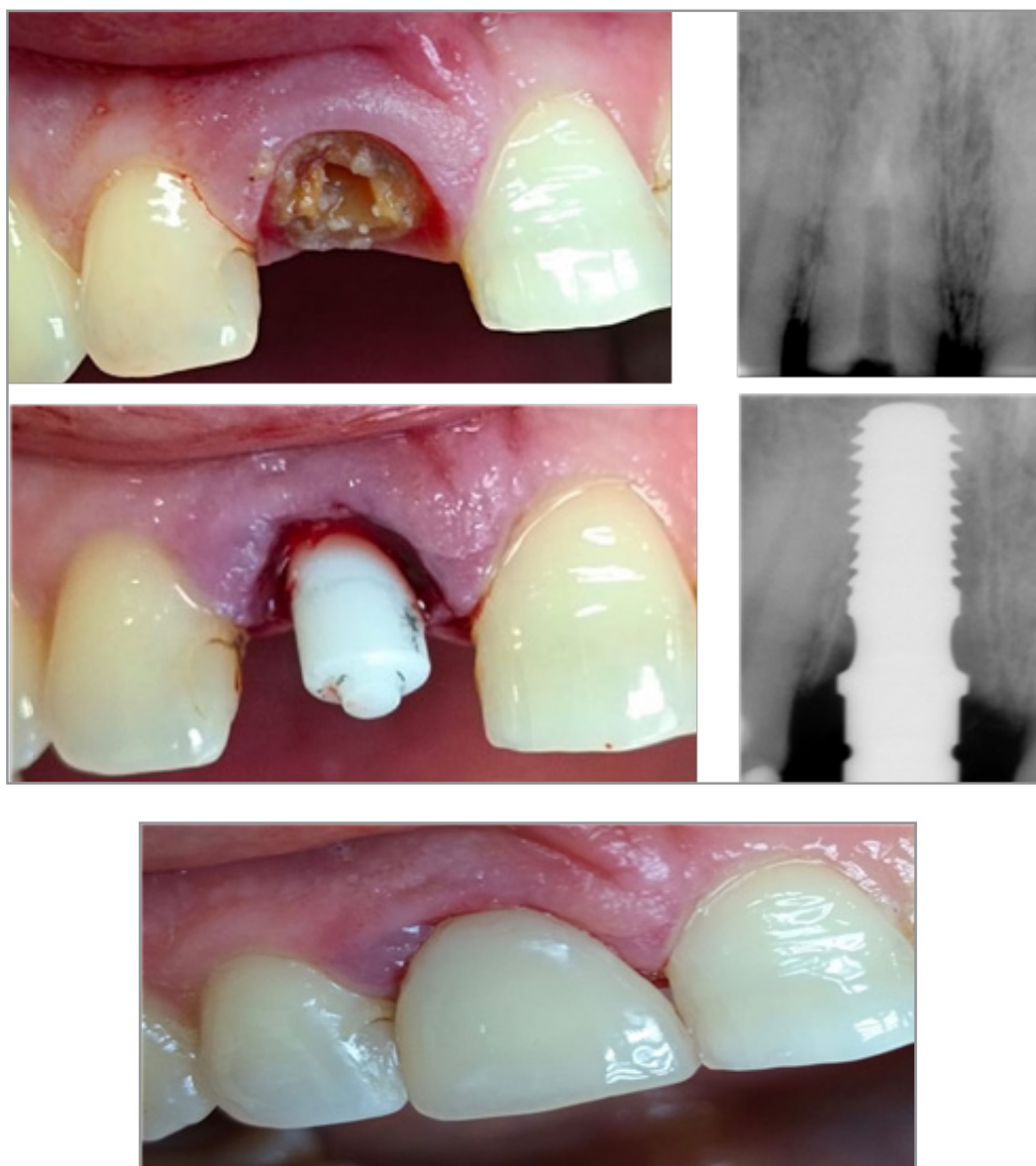

Figure 2: Stages of clinical work and R-control during work

During this work, we did not use bone substitutes, we did not perform auto transplantation of soft tissues. On the targeted control R-image, we can see that there is no complete fit between the implant and the bone tissue, but the torque is 40 N/cm². The crown is fixed on cement. We did not prescribe the patient any additional treatment other than the standard anti-inflammatory one. The

work was completed in 1.5 hours. The patient was very happy. The postoperative period proceeded without the formation of external edema, the patient did not take painkillers. Due to her busy schedule, the patient was only able to come for a checkup on 05.03.2024. We performed an examination and an R-scan to monitor the condition of bone tissue (Fig. 3)

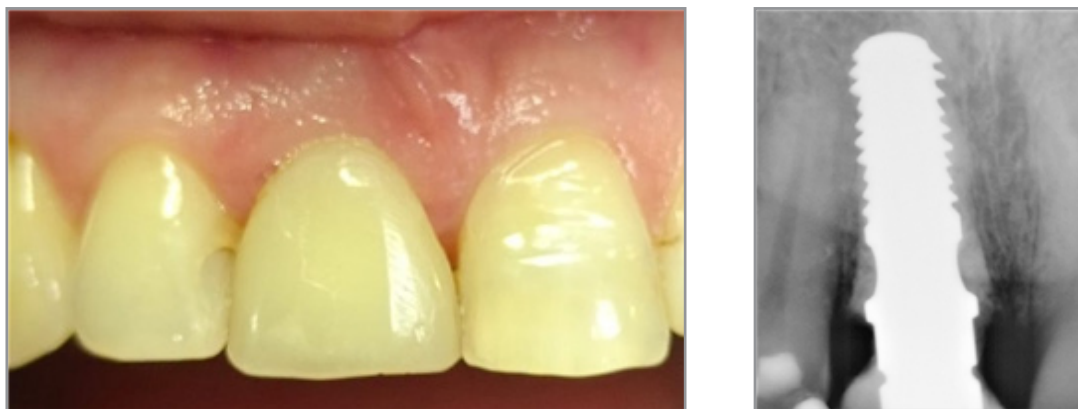

Figure 3: Appearance and R-control of bone condition (3 months)

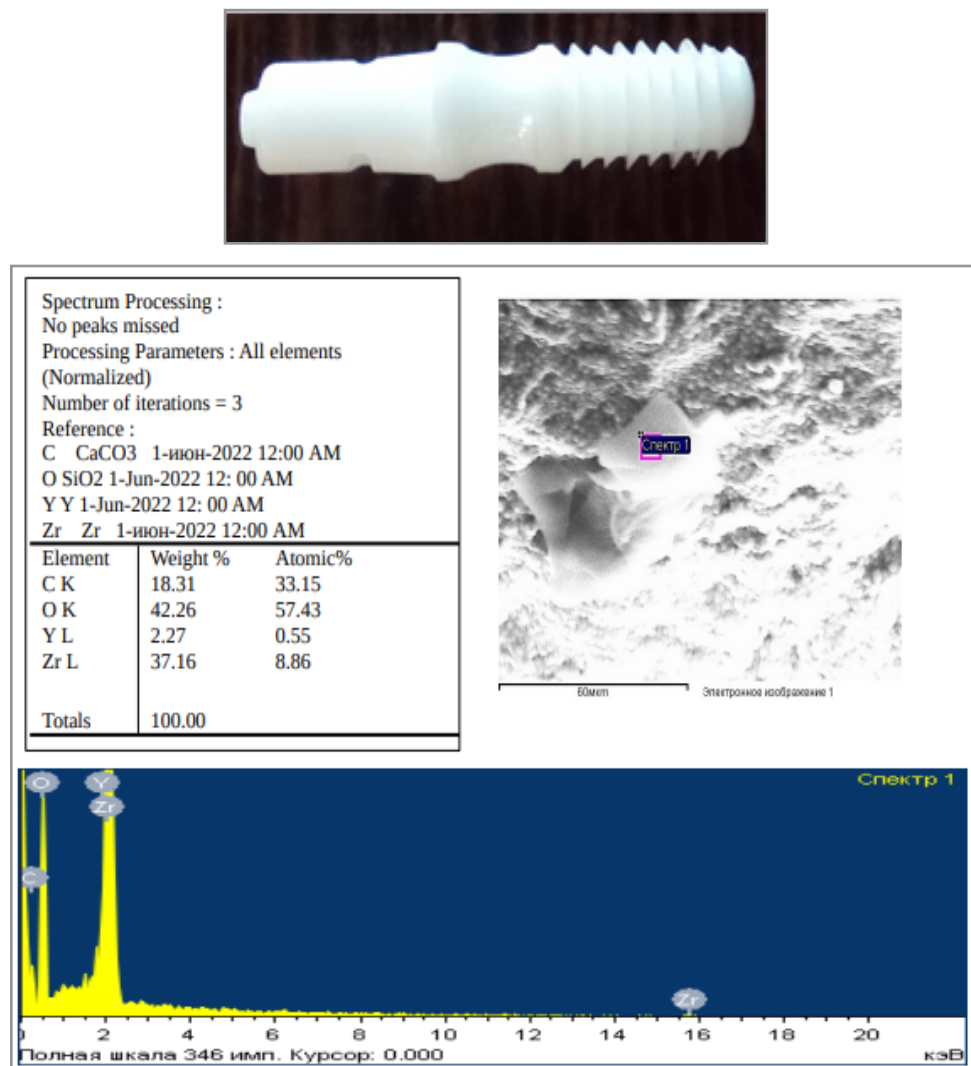


Figure 4: Atomic and spectral analysis of the surface of the threaded part of the developed bio-coated implant

Conclusions

Based on the results of observation of the restoration performed, no signs of re-implantitis have been detected so far in the area of the developed bio-coated zirconium implants. This case shows that the developed system of all-ceramic immediate implants with bio-coating is not only a reliable fulcrum for orthopedic restoration, but also independently contributes to the restoration of bone tissue, preserves and supports the soft tissues of the gums. This system allows you to immediately perform temporary prosthetics for the patient, which has a positive effect on the patient's psycho - emotional status. In the described clinical case, the result fully met our expectations. This is important for the successful implementation of this system in the daily practice of implant logical treatment, especially for patients with a thin gum phenotype and poor bone density. The presented system of all-ceramic instant implants with bio-coating provides flexibility of application for different rehabilitation tasks. The developed thread and coating allow you to achieve better primary stability and transfer of axial loads, and also allows you to be confident in maintaining the volume and density of bone tissue in the implantation area in the long term [12, 13].

References

1. Morozov DI, Zaslavsky RS, Martynov DV, Shmatov KV, Lerner A (2019) Comparison of characteristics of ceramic and titanium implants. Topical issues of dentistry 227-231.
2. Olesova VN, Kashchenko PV, Mikrokov VV, Zveryaev AG (2019) Prospects of intraosseous zirconia implants in orthopedic dentistry. Modern dentistry: problems, tasks, solutions 123-125.
3. Healthcare of the Russian Federation (FSBI "NNIITO named after Ya.L. Tsivoyan" of the Ministry of Health of Russia), Closed Joint Stock Company "INNOVACIONNY-J MEDIKO-TEKNOLOGICHESKIY CENTR (Texnopark)" (ZAO "IMTCz")]
4. Shumakov FG (2018) Experimental and clinical comparison of ceramic and titanium dental implants. Diss. Candidate of Medical Sciences, Moscow: Institute of Postgraduate Professional Education of the Federal State Budgetary Institution "State Scientific Center of the Russian Federation – Federal Medical Biophysical Center named after A. I. Burnazyan of the FMBA of Russia" 136.
5. Paula Andrea Ruiz Henao, Leticia Caneiro Queija, Santiago Mareque, Almudena Tasende Pereira, Antonio Liñares González, et al. (2021) Titanium vs ceramic single dental implants in the anterior maxilla: A 12-month randomized clinical trial. Clinical oral implants research 32: 951- 961.
6. Fernanda H Schünemann, María E Galárraga-Vinueza, Ricardo Magini, Márcio Fredel, Filipe Silva, et al. (2019) Zirconia surface modifications for implant dentistry. Materials science & engineering. C, Materials for biological applications 98: 1294-1305.
7. Ivanov AS, Martynov DV, Olesova VN, Zaslavsky RS, Shmatkov KV, et al. (2019) Zirconium dioxide as a modern material for dentures and implants. Russian Dental Journal 23: 4-6.
8. Melnikov Yu A, Zholudev SE, Zaikin DA (2021) Experimental and mathematical substantiation of the use of digital technologies for recording the position of the lower jaw in total prosthetics using dental implants. Problems of dentistry 17: 108-113.
9. Sadovoy MA, Kirilova IA, Podorozhnaya VT, Rozhnova OM, Mamonova EV (2015) Composite bone-ceramic implant based on ceramic material of the zirconium oxide-aluminum oxide system. Patent No. 2542496 C1 Russian Federation, IPC A61L 27/54, A61L 27/04, A61L 27/10. No. 2013138335/15: application 19.08.2013: published 20.02.2015; applicant Federal State.
10. Budgetary Institution "Novosibirsk Scientific Research Institute of Traumatology and Orthopedics named after Ya. L. Tsivyan" of the Ministry of Health of the Russian Federation (FGBU "NNIITO named after Ya. L. Tsivyan"). Russian Ministry of Health), Closed Joint-Stock Company "INNOVATIVE MEDICAL and TECHNOLOGICAL CENTER (Technopark)" (IMTC CJSC).
11. Meghna Prakash, Khrystal Audi, Ram M Vaderhobli (2021) Long-Term Success of All-Ceramic Dental Implants Compared with Titanium Implants. Journal of long-term effects of medical implants compared with titanium implants 31: 73-89.
12. Bikbaev A, Bungov V (2020) The return of the natural beauty of a smile. Aesthetic rehabilitation of the patient with ceramic restorations on their teeth and implants. Aesthetic dentistry 1: 279-283.
13. Kamalyan AV (2021) Expert criteria for assessing errors and complications in dental implantation in order to increase its effectiveness. Actual problems of medicine and biology 1: 97-105.