

AB Interno Canaloplasty in the Treatment of Glaucoma after Corneal Transplant Surgery

Juan Carlos Izquierdo-Villavicencio^{1,2*}, Elizabeth Pamela Santos Chu¹, Raúl Zúñiga¹, Luis Miguel Horna¹, and Melissa Zapata Duran MD¹

¹Glaucoma Research Department, Instituto de Ojos Oftalmosalud, Lima, Perú

²Head of Sub-Specialty Department of Glaucoma at Instituto de Ojos Oftalmosalud, Lima, Perú.

***Corresponding author:** Juan Carlos Izquierdo-Villavicencio, Instituto de Ojos Oftalmosalud, Javier Prado Este 1142, San Isidro, Lima, Peru.

Submitted: 05 August 2024 **Accepted:** 12 August 2024 **Published:** 19 August 2024

doi <https://doi.org/10.63620/MKSSJOEC.2024.1017>

Citation: Izquierdo-Villavicencio, J. C., Santos Chu, E. P., Zúñiga, R., Horna, L. M., & Zapata Duran, M. (2024). AB Interno Canaloplasty in the Treatment of Glaucoma after Corneal Transplant Surgery. *Sci Set J of Ophthalmology & Eye Care*, 3(3), 01-05.

Abstract

Introduction: Secondary glaucoma is one of the most common complications after corneal transplant surgery, which can lead to the rejection of the graft and irreversible damage to the optic nerve, leading to loss of visual potential in the eye. Therefore, early detection, control of intraocular pressure, and timely treatment are essential to promote graft survival and protect patients' vision. In recent years, glaucoma surgery has undergone a great revolution. Minimally invasive glaucoma surgeries (MIGS) unlike traditional ones, offer a rapid recovery process, less postoperative complications, safety, and effectiveness. MIGS should be considered as a new option in treating secondary glaucoma after keratoplasty given that it allows better protection of the graft and an increased survival rate.

Methods: This study is a retrospective review of patient data from consecutive patients with penetrating keratoplasty (PKP) or deep anterior lamellar keratoplasty (DALK), who underwent ab interno canaloplasty as a stand-alone procedure. Patients were followed up for 6 months: regarding vision, intraocular pressure (IOP), and the number of medications. Endothelial cell density (ECD), coefficient of variation, and hexagonality were calculated using specular microscopy preoperative and postoperatively to evaluate the security of the procedure in these types of patients.

Results: 10 patients were included. All canaloplasty surgeries were performed by the same surgeon. Preoperative mean IOP was 33.7 ± 14.7 ; the number of preoperative glaucoma medications was 4 ± 0.92 , after surgery the mean IOP was 12.2 ± 1.50 mmHg ($p < 0.001$) on 1.9 ± 0.88 medications ($p < 0.001$). The preoperative mean endothelial cell density (ECD) was 1813 ± 687.4 cells/mm². Following surgery was 1473 ± 549.0 cells/mm² ($p = 0.005$). No significant endothelial cell loss was detected. No serious adverse events were recorded. No failure graft was reported after surgery.

Conclusion: Ab interno canaloplasty is an effective and safe procedure that successfully achieves a lower IOP in patients with glaucoma after corneal transplant surgery. In this study survival of the corneal grafts was high, therefore it should be considered as an alternative prior to drainage surgery. Further prospective studies with larger patient populations are needed to elucidate the utility of canaloplasty in this population.

Keywords: Corneal Transplant, Intraocular Pressure, Ab Interno Canaloplasty, Glaucoma Surgery, Graft Survival.

Introduction

Corneal transplantation is a common procedure used to treat many corneal diseases to restore visual function. One of the most concerning complications of this procedure is glaucoma, which can eventually lead to graft failure and irreversible vision

loss [1]. Different studies have shown a variable incidence of post-keratoplasty glaucoma, as low as 8.7% and as high as 54% [1-3]. Patients with corneal transplants are particularly at risk for glaucoma because of various preoperative, intraoperative, and postoperative factors, which include the combination of steroid

response, mechanical alteration to the angle, inflammation till peripheral anterior synechiae (PAS) formation [2]. Glaucoma induced post keratoplasty often respond poorly to medications or laser treatment and require surgical intervention not only to lower the intraocular pressure and preserve the optic nerve but also to improve the survival of the corneal graft [4, 5]. In the past few years, MIGS such as ab interno canaloplasty, have been shown to lower intraocular pressure (IOP) and reduce glaucoma medication in patients with open-angle glaucoma (OAG) [6]. However, there are few publications of the application of MIGS in this kind of population.

We evaluated the effect of ab intern canaloplasty reducing intraocular pressure (IOP), the number of glaucoma medications, and in addition, this paper emphasizes the potential of the security of the procedure in terms of survival of the tissue in patients with glaucoma secondary to corneal transplant surgery.

Methods

This is a retrospective review of patient data from consecutive patients with PKP or DALK, who underwent ab interno canaloplasty 360° by iTrack as a stand-alone procedure from July 2022 to September 2023, at Instituto de Ojos Oftalmosalud, in Lima, Perú.

This study was approved by the Investigational Review Board (IRB) of the Institute. All canaloplasty surgeries were performed by the same surgeon.

Ab interno canaloplasty was performed routinely, a temporary corneal incision was made at hour 9 or 3 and another lateral incision was made to introduce the iTrack catheter (iTrack, iScience Interventional, Menlo Park, CA, USA). Sodium hyaluronate was injected (Healon GV; Abbott Medical Optics, Santa Ana, CA, USA) in the anterior chamber. Gonioscopy was used (Surgical Gonio Lens, Volk Alcon, Mentor, OH, USA) for goniotomy with Kahook dual blade (KDB; New World Medical, Rancho Cu-

camonga, CA, USA), microsurgical forceps was used to feed the distal tip of the microcatheter into Schlemm’s canal through the goniotomy site and was pushed circumferentially through 360, by applying two viscoelastic clicks per hour when removing it. Data was collected at several time points: postoperative day 1, week 1, month 1, month 3, and month 6. The data included visual acuity with correction (BCVA) using the Snellen test, intraocular pressure (IOP) measurements using Goldmann applanation tonometry, and the number of medications taken at each visit. Additionally, a complete medical history was obtained from all patients before they underwent the procedure. Patients with a documented history of diagnosis of glaucoma, and prior glaucoma surgery, including laser treatments, were excluded from the study.

Specular microscopy was used to examine the endothelial cell parameters preoperatively and 6 months postoperatively. This was done to determine the long-term safety of the procedure in this group of patients and to evaluate the benefits of this surgery in the survival of the transplanted tissue.

Statistical Analysis

Statistical Analysis was performed with SPSS software (version 28.0, IBM Inc.). Descriptive statistics were used to analyze the general characteristics, with frequencies and percentages for the qualitative variables and mean with standard deviation for the quantitative data. The median and interquartile range were used to describe corrected visual acuity. Due to the sample size, post-operative changes were assessed with the paired Wilcoxon test. A p value of < 0.05 was considered statistically significant.

Results

The general characteristics of the patients are summarized in Table 1, with an average age of 30.7 years and 80% being male. All patients underwent internal AB canaloplasty plus PKP, except for one patient, who underwent DALK.

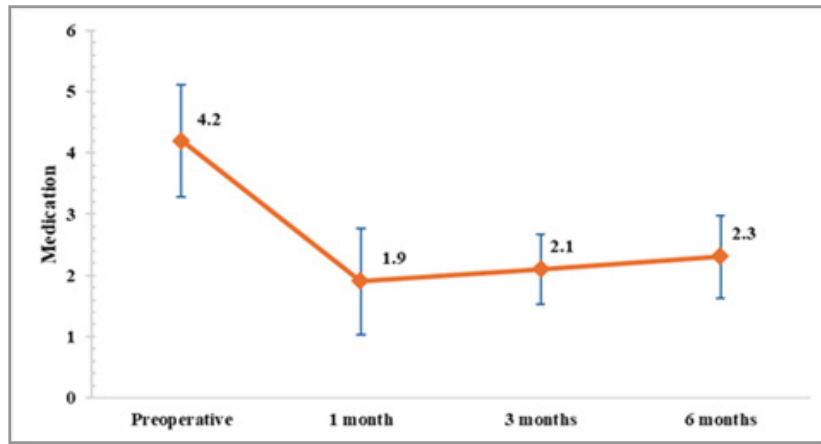
Table 1: Demographics and Baseline Characteristics.

Characteristics	All (n =10)
Age, years (mean ± SD)	30.7 ± 14.98
Gender (n, %)	
Male	8 (80)
Female	2 (20)
Prior corneal surgery (n, %)	
PKP	9 (90)
DALK	1 (10)
Laterality (n, %)	
Left	5 (50)
Right	5 (50)

SD: standard deviation; PKP: Penetrating Keratoplasty; DALK: Deep Anterior Lamellar Keratoplasty.

The average number of glaucoma medications is shown in Graph 1. It decreased from an average of 4.2 ± 0.92 before the operation to 2.3 ± 0.67 after 6 months. The decrease in medication

remained stable up to 6 months compared to before the operation (p<0.005) and showed no significant differences in the number of medications between the first, third, and sixth months.



Graph 1: Mean number of medications from baseline to 6 months post-surgery.

Table 2 shows the median corrected visual acuity before surgery (20/50) and after 6 months (20/40) corrected visual acuity improved in the sixth month, presenting a statistically significant difference compared to preoperative visual acuity ($p = 0.043$).

Concerning the parameters of specular microscopy, there was a significant decrease in the density of endothelial cells ($p=0.005$). However, neither the coefficient of variation nor the hexagonality rate showed significant changes 6 months after the canaloplasty was performed (Table 2).

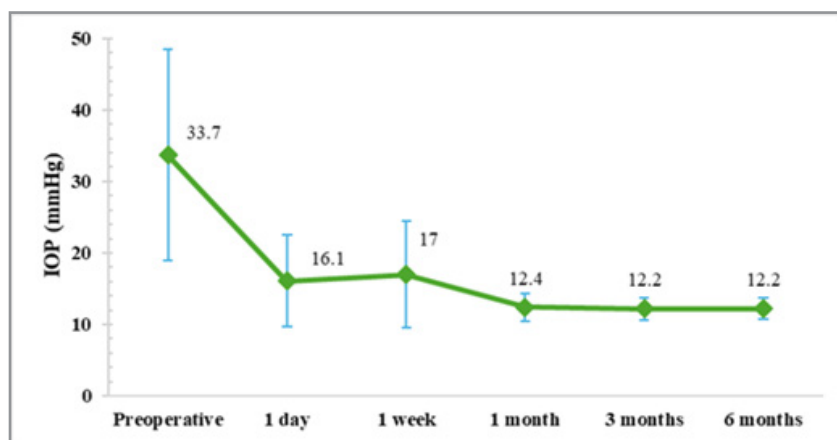
Table 2: Visual acuity and specular microscopy parameters

	Preoperative	6 months	p
Corrected visual acuity	20/50 (20/40, 20/200)	20/40 (20/25, 20/50)	0.043
Endothelial cell parameters			
Endothelial cell density, cells/mm ²	1813.0 ± 687.4	1473.1 ± 549.0	0.005
Coefficient of variation	23.7 ± 12.3	33.2 ± 5.6	0.059
Hexagonality, %	68.1 ± 14.0	70.1 ± 7.8	0.593

Corrected visual acuity is shown as median (interquartile range).

There was a significant decrease in intraocular pressure (IOP) from baseline (33.7 ± 14.7 mmHg) to all post-surgical follow-up appointments ($p<0.001$). The IOP remained above 16 mmHg until the first week after canaloplasty, but it stabilized at around

12 mmHg by the first month and continued at this level until the sixth month, with no significant differences between the first (12.4 ± 1.9 mmHg), third (12.2 ± 1.6 mmHg), and sixth months (12.2 ± 1.5 mmHg).



Graph 2: Intraocular pressure (IOP) measurements at baseline and after 6 months post- surgery.

Discussion

Glaucoma after corneal transplantation is a well-established complication that remains difficult to manage and represents a significant barrier to optimal visual outcome and corneal graft survival [7]. Over the years, glaucoma treatments have intended to reduce in a significant way the side effects and complications [8]. Although the literature includes many studies on the treatment of glaucoma after keratoplasty, many of these studies have small numbers of patients, limited follow-up, and different criteria for defining successful outcomes [9].

MIGS has been the latest addition to the glaucoma surgical treatment paradigm. The main theme and priority of MIGS is patient safety. Ab interno canaloplasty is a nonpenetrating blebless surgical technique for open-angle glaucoma, in which a flexible microcatheter is inserted within Schlemm's canal for the entire 360 degrees and that increases aqueous humor drainage to control IOP [10]. However, there are few pieces of literature on the application of MIGS in the treatment of secondary glaucoma after keratoplasty.

Nazerali et al. reported the first case of glaucoma following PKP managed with gonioscopy-assisted transluminal trabeculotomy (GATT) and cataract phacoemulsification. Following surgery, the patient's intraocular pressure and visual acuity was 13 mmHg and 20/30 respectively [11]. Additionally, Smith et al. published a retrospective case series of eyes with a history of prior corneal transplant undergoing GATT at Glaucoma Associates of Texas. IOP was reduced from the first day, but stabilized at 6 months, presenting a mean of 13.8 ± 4.4 mmHg, which was maintained until 24 months of follow-up (13.9 ± 4.7 mmHg). The number of medications decreased from 4.2 ± 1 at baseline to 0.9 ± 1.3 , at 6 months which is comparable with the results of our study [12].

In 2023, Riaz et al. demonstrated the effectiveness of ab interno canaloplasty with iTrack microcatheter in post-keratoplasty patients for the first time. They found that IOP decreased significantly to 15 ± 4.21 mmHg at 6 months and 13 ± 2.99 mmHg at year. The average number of topical hypotensive medications also reduced to 2.7 ± 1.4 at 6 months, although not significantly ($p = 0.096$). In the present study, we found lower IOP values after iTrack Ab Interno Canaloplasty (33.7 ± 14.7 to 12.2 ± 1.5 ; $p < 0.001$) and the number of medications also reduced significantly from 4 ± 0.92 to 1.9 ± 0.88 ($p < 0.001$). This effect was sustained during the 6 months of the follow-up.

IOP was reduced in all studies, however, this research shows a lower controlled IOP compared to those that underwent GATT. In Riaz et al's study, a higher post-surgical IOP value was found, possibly because the average age of their patients was 60 years, and some of them had pre-existing primary open angle glaucoma [13].

It is important to notice that in all these studies there is a significant reduction in the need for medical treatment after surgery. The importance of this result lies in the fact that topical hypotensive agents not only affect the ocular surface but also induce mild chronic inflammatory reactions of the conjunctiva and corneal epithelium, reduction of corneal thickness, scarring, etc., which can be dangerous for fragile post keratoplasty. Therefore,

it is of utmost importance to use the least amount of medications as possible [14,15].

On the other hand, the use of MIGS may be beneficial for treating glaucoma in patients who have had corneal transplants. Unlike traditional surgeries like trabeculectomy, MIGS can help avoid complications such as bleb-related issues and potential damage to the endothelium. Additionally, MIGS like canaloplasty can treat the entire angle (360 degrees), which is a unique advantage compared to other MIGS procedures [16].

Studies are constantly looking at endothelial cell loss after glaucoma surgery as an indicator of graft survival. Riaz was the first to demonstrate that MIGS is an excellent option for treating secondary glaucoma in patients who have previously undergone keratoplasty [13]. In this, research, we observed that cell density decreased significantly ($p=0.005$), nevertheless, there were no significant changes in terms of hexagonality or in the coefficient of variation, which demonstrates that this is an effective and less traumatic procedure for ensuring long-term graft survival.

Finally, to our knowledge, this is the first study to evaluate endothelial cell parameters after of ab interno canaloplasty reducing IOP in post-keratoplasty patients, showing not only its hypotensive effectiveness but also its safety on corneal properties that help preserve the transplant. However, the main weakness of this study was the retrospective nature, small sample size, short follow-up, and no control group. Future studies with a higher number of participants are necessary for more precise outcomes.

Conclusion

The findings of this study suggest that performing ab Interno canaloplasty on patients with a corneal transplant has a significant positive effect on controlling IOP post-operatively. This procedure reduces the need for a smaller number of medications and, most importantly, it is an effective and safe way to ensure the survival of the corneal graft. As a result, it should be considered as an alternative to drainage surgery. However, further prospective studies with larger patient populations are required to fully understand the benefits of canaloplasty in this group of patients.

Data Availability

The data used to support the findings of this study are available from the corresponding author upon request.

Disclosure

The authors report no conflicts of interest related to this work.

References

1. Zheng, C., Yu, F., Tseng, V. L., Lum, F., & Coleman, A. L. (2018). Risk of Glaucoma Surgery After Corneal Transplant Surgery in Medicare Patients. *American Journal of Ophthalmology*, 192, 104-112.
2. Haddadin, R. I., & Chodosh, J. (2014). Corneal Transplantation and Glaucoma. *Seminars in Ophthalmology*, 5, 380-396.
3. Wu, S., & Xu, J. (2017). Incidence and risk factors for post-penetrating keratoplasty glaucoma: A systematic review and meta-analysis. *PLoS ONE*, 12.

4. Anders, L.-M., Gatzoufas, Z., & Grieshaber, M. C. (2021). Challenges in the complex management of post-keratoplasty glaucoma. *Ophthalmol Eye Dis*, 13, 251584142110313.
5. Lin, Y., Gou, Q., Yu, P., Wu, Z., Zeng, L., & Chen, H. (2024). Mechanism and treatment of secondary glaucoma after corneal transplantation: a review. *Front Ophthalmol*, 4, 1361704.
6. Hughes, T., & Traynor, M. (2020). Clinical Results of Ab Interno Canaloplasty in Patients with Open-Angle Glaucoma. *Clin Ophthalmol*, 14, 3641-3650.
7. Abdelghany, A. A., D'Oria, F., & Alio, J. L. (2021). Surgery for glaucoma in modern corneal graft procedures. *Survey of Ophthalmology*, 66, 276-289.
8. Vallabh, N. A., Kennedy, S., Vinciguerra, R., McLean, K., Levis, H., et al. (2022). Corneal Endothelial Cell Loss in Glaucoma and Glaucoma Surgery and the Utility of Management with Descemet Membrane Endothelial Keratoplasty (DMEK). *Journal of Ophthalmology*, 2022, 1-17.
9. Banitt, M., & Lee, R. K. (2009). Management of patients with combined glaucoma and corneal transplant surgery. *Eye*, 23, 1972-1979.
10. Riva, I., Brusini, P., Oddone, F., Michelessi, M., Weinreb, R. N., et al. (2019). Canaloplasty in the Treatment of Open-Angle Glaucoma: A Review of Patient Selection and Outcomes. *Adv Ther*, 36, 31-43.
11. Nazarali, S., Cote, S. L., & Gooi, P. (2018). Gonioscopy-Assisted Transluminal Trabeculotomy (GATT) in Post-penetrating Keratoplasty Steroid-induced Glaucoma: A Case Report. *Journal of Glaucoma*, 27, 162-164.
12. Smith, O. U., Butler, M. R., Grover, D. S., Kornmann, H. L., Emanuel, M. E., et al. (2022). Twenty-Four-Month Outcome of Gonioscopy-Assisted Transluminal Trabeculotomy (GATT) in Eyes with Prior Corneal Transplant Surgery. *Journal of Glaucoma*, 31, 54-59.
13. Riaz, K. M., Gill, M. S., Murphy, D. A., Ding, K., & Khaimi, M. A. (2023). Surgical Management of Intraocular Pressure with Ab Interno Canaloplasty in Post keratoplasty Patients: 12-Month Results. *Cornea*, 42, 52-59.
14. Ruiz-Lozano, R. E., Azar, N. S., Mousa, H. M., Quiroga-Garza, M. E., Komai, S., et al. (2023). Ocular surface disease: a known yet overlooked side effect of topical glaucoma therapy. *Front Toxicol*, 5, 1067942.
15. Chua, J., Vania, M., Cheung, C. M. G., Ang, M., Chee, S. P., et al. (2012). Expression profile of inflammatory cytokines in aqueous from glaucomatous eyes. *Mol Vis*, 18, 431-438.
16. Mathew, D. J., & Buys, Y. M. (2020). Minimally Invasive Glaucoma Surgery: A Critical Appraisal of the Literature. *Annu Rev Vis Sci*, 6, 47-89.