

The Compendious Insusceptibility- IgG4 Related Disease

Anubha Bajaj

Consultant Histopathology, A. B. Diagnostics, A-1, Ring Road Rajouri Garden, New Delhi 110027, India

*Corresponding author: Anubha Bajaj, Consultant Histopathology, A. B. Diagnostics, A-1, Ring Road Rajouri Garden, New Delhi 110027, India.

Submitted: 28 Mar 2023 Accepted: 04 Apr 2023 Published: 10 Apr 2023

 <https://doi.org/10.63620/MKSSJMCCS.2023.1009>

Citation: Bajaj, A. (2023) The Compendious Insusceptibility- IgG4 Related Disease. Sci Set J of Med Cli Case Stu 2(2), 01-04

Abstract

Introduction: Few studies identified variables associated with neonatal care practices were varied from place to place. However, little is known about the prevalence of neonatal care practice and associated factors in Ethiopia including the study area. This study was aimed to assess the prevalence of neonatal care practice and associated factors among postnatal mothers who have neonates in Kombolcha town.

Methods: Community-based cross-sectional study supplemented with the qualitative inquiry was conducted among 625 postnatal mothers in selected Kebeles of Kombolcha town. Multistage systematic random sampling technique was used to select study participants for a quantitative study. Data were collected using a structured interviewer-administered questionnaire. Eighteen participants for qualitative in-depth interviews were selected through the purposive sampling technique. Data were entered into Epi-Data version 4.6 and then exported to Statistical Package for Social Science (SPSS) version 25 for further analyses. Binary logistic regression was performed to identify factors associated with the outcome variable of interest. The level of statistical significance was declared at P-value less than 0.05. Qualitative data were transcribed and coded during and after the data collection period, then were analysed manually by using a thematic approach.

Results: Out of the total 606 participants, the prevalence of neonatal care practice was [49.7%, 95%CI: (45.72%, 53.68%)]. On multivariable logistic regression model, number of antenatal care visits [AOR = 3.28; 95%CI (1.40, 7.67)], birth interval of current baby [AOR = 2.56; 95%CI (1.06, 6.16)] and knowledge of mothers towards neonatal care practice [AOR = 8.66; 95%CI (4.83, 15.56)] were significantly associated with neonatal care practice.

Conclusion: prevalence of neonatal care practice was relatively low among postnatal mothers in Kombolcha town compared to other literature. The number of antenatal care visits, the birth interval of the current baby, and knowledge of mothers towards neonatal care practice were found to be independent predictors.

Keywords: Neonatal, Care Practice, Factors, Mixed Study

Introduction

IgG4 related disease appears as a component of systemic, immune mediated fibro-inflammatory condition implicating diverse organs. Incrimination of renal parenchyma manifests as an acute or chronic interstitial nephritis delineating a lymphoid and plasma cell rich inflammatory infiltrate with predominance of IgG4+ plasma cells. Besides, tubules and interstitium display deposition of immune complexes along with frequent occurrence of fibrosis configuring tumorous masses or a storiform pattern. Incrimination of glomeruli is variable and essentially emerges as membranous nephropathy. Pathognomonic features as chronic interstitial nephritis with an intense lymphoplasmacytic inflammatory infiltrate with preponderant IgG4+ plasma cells and foci

of storiform fibrosis are discerned. Generally, storiform fibrosis is associated with diverse systemic manifestations of IgG4 related disease. The condition may recapitulate diverse causes of membranous nephropathy and allied patterns of cellular injury. Enhanced interstitial subtype of collagen bundles may be observed. Few lesions may be classified contingent to fibrosis and configured dissemination of collagen bundles. The condition is amenable to therapy with glucocorticoids [1, 2]. Additionally designated as IgG4 related systemic disease, IgG4 syndrome, IgG4 associated disease, IgG4 related sclerosing disease, IgG4 related systemic sclerosing disease, IgG4 related autoimmune disease, IgG4+ multi-organ lymphoproliferative syndrome, hyper-IgG4 disease, systemic IgG4 related plasmacytic syndrome,

systemic IgG4 related sclerosing syndrome, multifocal fibrosclerosis or multifocal idiopathic fibrosclerosis, the condition emerges between 20 years to 80 years with average age of disease occurrence at ~65 years [1, 2]. A male predilection is observed with male to female proportion of 3:1 to 7:1. IgG4 related disease commonly incriminates pancreas, bile duct, lacrimal glands, salivary glands, central nervous system, thyroid gland, pulmonary parenchyma, hepatic parenchyma, renal parenchyma, gastrointestinal tract, prostate, retroperitoneum, arterial vascular articulations, lymph nodes, breast and diverse cutaneous surfaces although no site of disease emergence is exempt [1, 2]. Renal parenchyma or ureter preponderantly delineate incrimination of tubulointerstitial compartment. Ureter may exemplify strictures or a pseudo-tumour. Glomerular involvement with membranous nephropathy is infrequent [1, 2].

Of undefined pathogenesis, IgG4 related disease demonstrates features consistent with an autoimmune disorder in concurrence with an allergic condition. Follicular helper T cells and CD4+ cytotoxic T cells are implicated in disease emergence. Of obscure aetiology, IgG4 related disease may appear concordant to genetic manifestations, bacterial infection and simulated molecular features or as an autoimmune disease [2, 3].

Majority of subjects manifest with acute or progressive renal insufficiency. The condition may represent as a renal mass lesion simulating renal cell carcinoma. Multiple lesions may ensue. Besides, diffuse renal enlargement may occur. Renal enlargement may be bilateral. Singular thickening of renal pelvis may ensue. Ureteral stricture can be discerned [3, 4]. Majority (~90%) of subjects demonstrate incrimination of multiple organs. Lymphadenopathy may be frequently detected. Subjects with multi-organ disease delineate significant loss of weight. Majority (~90%) of subjects exhibit elevated levels of serum IgG4 and ~50% individuals exemplify decimated levels of complement with reduced C3, C4 or CH50. Peripheral eosinophilia may ensue.

Grossly, renal resection specimens of IgG4 related disease enunciate masses or tumour-like lesions [3, 4].

Upon microscopy, lesions preponderantly exhibit chronic interstitial nephritis along with an intense interstitial infiltrate of lymphoid cells, lympho-plasmocytic cells and prominent plasma cells. Plasma cells immune reactive to IgG4+ appear elevated. Foci of fibrosis with storiform configuration are encountered. Frequently, the tubulointerstitial compartment exhibits significant architectural effacement with occurrence of tubulitis. Upon trichrome staining, immunoglobulin deposits may be discerned within tubular basement membrane. Renal parenchyma is generally devoid of obliterative phlebitis. Exceptionally, pattern of renal injury may simulate acute interstitial nephritis. Glomeruli may exemplify a pattern of membranous damage. Surgical tissue samples appear inadequate for ascertaining proportionate interstitial fibrosis. Additionally, occurrence of granulomatous inflammation or necrosis excludes a diagnosis of IgG4 related disease [3, 4].

Upon immunofluorescence, renal tubulointerstitium exhibits granular immunoglobulin deposits upon tubular basement membrane. Majority of tubules exemplify IgG, predominantly IgG4 and dual light chains as kappa and lambda chains. Expression

of C1q and IgM is infrequent. Immunoglobulin deposits appear amalgamated upon foci of fibrosis wherein uninvolved zones may be devoid of the deposits. Plasma cells appear immune reactive to IgG and kappa and lambda light chains. Immunofluorescence appears unsuitable for quantifiable assessment of IgG4+ plasma cells [3, 4]. Incriminated glomerulus may exhibit membranous glomerulopathy with a granular, 'capillary loop' variety of staining. Generally, reactivity to IgG, C3 and light chains is observed. Few instances devoid of membranous pattern of staining may exhibit granular mesangial staining. Glomeruli may be devoid of immunoglobulin deposits and cogent staining may be absent with lack of membranous component. Immunoglobulin deposits may be discerned within Bowman's capsule. Upon ultrastructural examination, electron dense deposits appear along tubular basement membrane in the absence of a substructure. Sub-epithelial deposits are associated with remodelled glomerular basement membrane in concurrence with membranous component [3, 4].

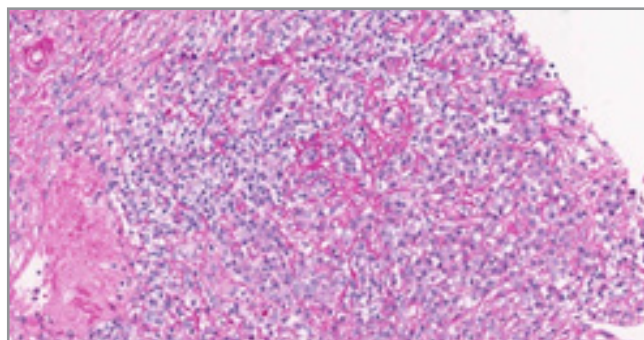


Figure 1: IgG4 related disease exhibiting an intense inflammation of tubules and interstitium with an inflammatory exudate of lymphoid and plasma cells along with thickened tubular basement membrane intermingled with foci of storiform fibrosis [6].

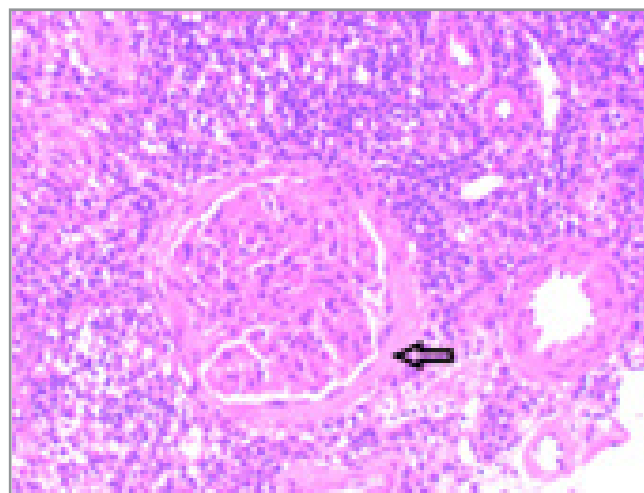


Figure 2: IgG4 related disease demonstrating an involved glomerulus with membranous nephropathy and inflammation of surrounding tubules with interstitium with a lymphoid and IgG4+ plasma cell rich infiltrate admixed with patent capillaries [7].

Revised comprehensive diagnostic criterion for IgG4-Related Disease are designated as

- Clinical and radiological features (1) ~singular or multiple organs display diffuse or localized swelling, tumefaction or

nodule characteristic of IgG4 related disease. Single organ involvement is devoid of incriminated lymph node

- Serological findings (2) ~serum IgG4 levels > 135 milligrams/decilitre
- Pathological features (3) ~discerning minimally two of three criterions elucidated as •dense lymphocytic and plasma cell infiltration with fibrosis •ratio of IgG4+ plasma cells/IgG+ cells are >40% and quantifiable IgG+ plasma cells is > 10 per high power field •typical tissue fibrosis as storiform fibrosis or obliterative phlebitis
- Disease diagnosis ~definite: 1+2+3 ~probable: 1+3 ~possible: 1+2

Subjects with possible or probable diagnosis as per comprehensive diagnostic criterion fulfilling organ specific diagnostic criterion are contemplated as definite IgG4 related disease [3, 4].

IgG4 related disease is immune reactive to CD138. Constituent plasma cells appear immune reactive to IgG4. Foci of fibrosis with storiform configuration can be highlighted with Jones methenamine silver (JMS) stain, periodic acid Schiff's (PAS) stain and trichrome stains. Jones methenamine silver (JMS) stain can optimally highlight spikes within membrane capillaries or articulate a 'pinhole' pattern. Trichrome stain can highlight tubular basement membrane and immunoglobulin deposits within capillary articulations [4, 5].

IgG4 related disease requires segregation from conditions such as Sjögren syndrome related tubulointerstitial nephritis, interstitial inflammation associated with pauci-immune (ANCA associated) glomerulonephritis, allergic or drug related acute or chronic interstitial nephritis, chronic pyelonephritis, lupus nephritis, small B cell lymphomas as extra-nodal marginal zone lymphoma, diabetic nephropathy, multicentric Castleman disease, Erdheim-Chester disease, membranous glomerulopathy or anti-brush border antibody disease / anti-LRP2 nephropathy [4, 5].

IgG4 related disease can be appropriately ascertained with •histological features wherein minimally two of three manifestations are necessitated as ~dense lymphoid and plasma cell infiltrate ~fibrosis which commonly configures a storiform pattern ~obliterative phlebitis. Additionally, IgG4/IgG plasma cell ratio >40%, >30% IgG4+ plasma cells/high power field or >10 IgG4+ plasma cells/ high power field discernible within a tissue sample is necessitated [4, 5]. Probable emergence of IgG4 related disease upon histology is devoid of comprehensive histological disease spectrum or cogent immunohistochemistry associated with IgG4 related disease. Characteristically, singular histopathological feature as a dense lymphoid and plasma cell infiltrate and posited quantification of IgG4+ plasma cells are sufficiently di-

agnostic [4, 5]. Additional clinical, serological or radiological evidence confirmatory for IgG4 related disease is designated as ~serum IgG4 levels > 135 milligrams/decilitre ~incrimination of diverse organs as ascertained with radiological or pathological assessment ~evidence of IgG4 related disease within variable sites [4, 5]. Nevertheless, insufficient histopathological evidence of IgG4 related disease as denominated in aforementioned categories may not entirely exclude IgG4 related disease and may occur due to sampling artefact, preceding therapy or advanced disease stage with significant fibrosis. Majority (~90%) of subjects demonstrate elevated total serum IgG or IgG4 values. Around ~50% subjects depict decimated levels of complement with reduced C3 or C4 levels. Besides, features such as hypergammaglobulinemia or eosinophilia may ensue [4, 5].

Upon imaging, a singular or multiple mass lesions appear confined to renal parenchyma. Tumefaction may extend into perinephric tissues. Also, neoplasms confined to diverse organs may indicate the occurrence of IgG4 related disease [4, 5]. IgG4 related disease is appropriately managed with administration of glucocorticoids. Rituximab is an optimal agent for treating disease recurrence or may be adopted with contraindication of glucocorticoid therapy [4, 5]. Cogent therapy of IgG4 related disease is accompanied by > 80% proportionate therapeutic response with ~10% proportionate disease relapse [4, 5]. Elevation of serum IgG4 and IgE levels and enhanced circulating eosinophils may predict recurrence of IgG4 related disease. Subjects demonstrating enhanced possible occurrence of disease relapse appear devoid of consensus w.r.t. optimal therapeutic strategies. IgG4 related disease may reappear within renal allografts [4, 5].

References

1. Alaggio R, Amador C, Anagnostopoulos I (2022) The 5th edition of the World Health Organization Classification of Haematolymphoid Tumours: Lymphoid Neoplasms. *Leukaemia* 36: 1720-1748.
2. Morf H, Roemer F, Agaimy A (2021) IgG4-related fasciitis. *Rheumatology (Oxford)* 61: e11-e12.
3. Hisanori Umehara, Kazuichi Okazaki, Shigeyuki Kawa, Hiroki Takahashi, Hiroshi Goto (2021) The 2020 revised comprehensive diagnostic (RCD) criteria for IgG4-RD. *Modern Rheumatology* 31: 529 -533.
4. Chen LYC, Mattman A, Seidman MA, Mollie N Carruthers (2019) IgG4-related disease: what a hematologist needs to know. *Haematologica* 104: 444-455.
5. Gaspar BL (2020) IgG4-related lymphadenopathy –a difficult diagnosis. *Surg Exp Pathol* 3: 30.
6. Image 1 Courtesy: Pathology outlines
7. Image 2 Courtesy: Cureus