

Idiopathic Intracranial Hypertension Revealed by Unilateral Subconjunctival Hemorrhage in a Young Female : A Case Report

Hilali Zineb^{1*}, Moumni Ahmed², Azarkan Boutayna³, Benkirane Romaine⁴, Sbai Latifa⁵, El hachimi Rim⁶ & Cherkaoui Lalla Ouafae⁷

Ibn Sina Hospital, Ophthalmology A Department, Rabat – Morocco

*Corresponding author: Hilali Zineb, Ibn Sina Hospital, Ophthalmology A Department, Rabat – Morocco.

Submitted: 13 October April 2025 Accepted: 21 October 2025 Published: 28 October 2025

doi <https://doi.org/10.63620/MKSSJOEC.2025>.

Citation: Hilali, Z., Moumni, A., Azarkan, B., Benkirane, R., Sbai, L., El Hachimi, R., & Cherkaoui, L. O. (2025). Idiopathic Intracranial Hypertension Revealed by Unilateral Subconjunctival Hemorrhage in a Young Female : A Case Report. *Sci Set J of Ophthalmology & Eye Care*, 4(5), 01-05.

Abstract

Idiopathic intracranial hypertension (IIH) is classically characterized by headache, papilledema, and elevated intracranial pressure in the absence of structural brain lesions. Unusual presentations, particularly without headache, can delay diagnosis. We report the case of a 25-year-old woman presenting with unilateral subconjunctival hemorrhage without headache or visual complaints. Fundus examination revealed bilateral papilledema. Brain imaging showed signs suggestive of raised intracranial pressure, and lumbar puncture confirmed elevated cerebrospinal fluid pressure (32 cm H₂O). She was treated with acetazolamide and a cerebrospinal fluid-depleting lumbar puncture, with good clinical and anatomical recovery at three-month follow-up. Subconjunctival hemorrhage is a rare and underrecognized manifestation of IIH. This case underlines the importance of considering IIH in young women presenting with unexplained ocular signs, even in the absence of typical symptoms like headache. L'hypertension intracrânienne idiopathique (HTICI) se caractérise classiquement par des céphalées, un œdème papillaire et une pression intracrânienne élevée en l'absence de lésions structurales cérébrales. Des présentations atypiques, notamment sans céphalées, peuvent retarder le diagnostic. Nous rapportons le cas d'une femme de 25 ans présentant une hémorragie sous-conjonctivale unilatérale sans céphalées ni plainte visuelle. L'examen du fond d'œil a révélé un œdème papillaire bilatéral. L'imagerie cérébrale a montré des signes évocateurs d'une hypertension intracrânienne, et une ponction lombaire a confirmé une pression élevée du liquide céphalorachidien (32 cm H₂O). Elle a été traitée par acétazolamide et ponction lombaire déplétive, avec une bonne récupération clinique et anatomique au suivi à trois mois. L'hémorragie sous-conjonctivale est une manifestation rare et souvent méconnue de l'HTI. Ce cas souligne l'importance de considérer une HTI chez les jeunes femmes présentant des signes oculaires inexpliqués, même en l'absence de symptômes typiques tels que les céphalées.

Keywords: Acetazolamide, Idiopathic Intracranial Hypertension, Papilledema, Subconjunctival Hemorrhage, Visual Field Defect. Acétazolamide, Hypertension Intracrânienne Idiopathique, Œdème papillaire, Hémorragie sous-conjonctivale, Déficit du Champ Visuel.

Introduction

Idiopathic intracranial hypertension (IIH) is a condition characterized by elevated intracranial pressure without an identifiable cause. It predominantly affects obese women of childbearing age and typically presents with headache, visual disturbances, and papilledema. Atypical presentations, such as isolated ocular signs without headache, are uncommon and may lead to delayed diagnosis. We present a case of IIH revealed by isolated subconjunctival hemorrhage in a young woman with no identifiable risk factors.

Case Presentation

A 25-year-old woman with no significant past medical history presented with a spontaneous, painless subconjunctival hemorrhage of the left eye. She denied any trauma, visual disturbances, or headaches, although she reported occasional pulsatile tinnitus. Her body mass index was within the normal range. She was not taking any medications, including oral contraceptives or other drugs known to increase the risk of raised intracranial pressure. Ophthalmologic examination revealed bilateral stage 3 optic disc swelling consistent with papilledema (figure1).

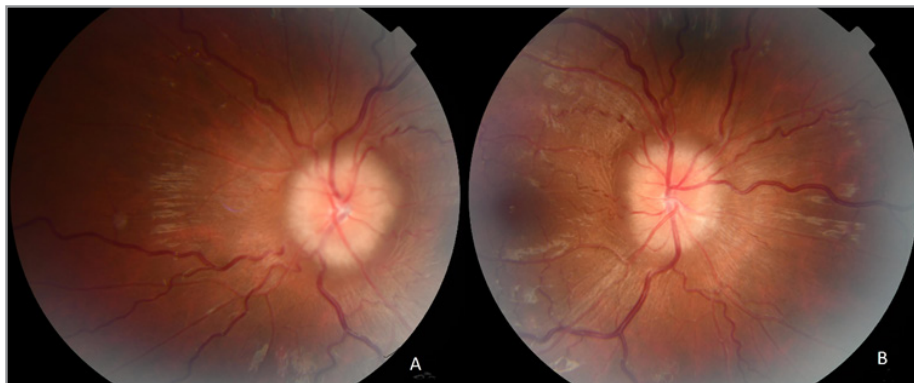

Figure 1: Fundus photography showing stage 3 papilledema on the right (A) and on the left (B)

Visual acuity was 20/20 in both eyes. Neurological examination revealed no evidence of sixth nerve palsy. Optical coherence tomography confirmed optic disc edema (figure 2). Visual field

testing revealed a nasal step and an enlarged blind spot in the left eye.

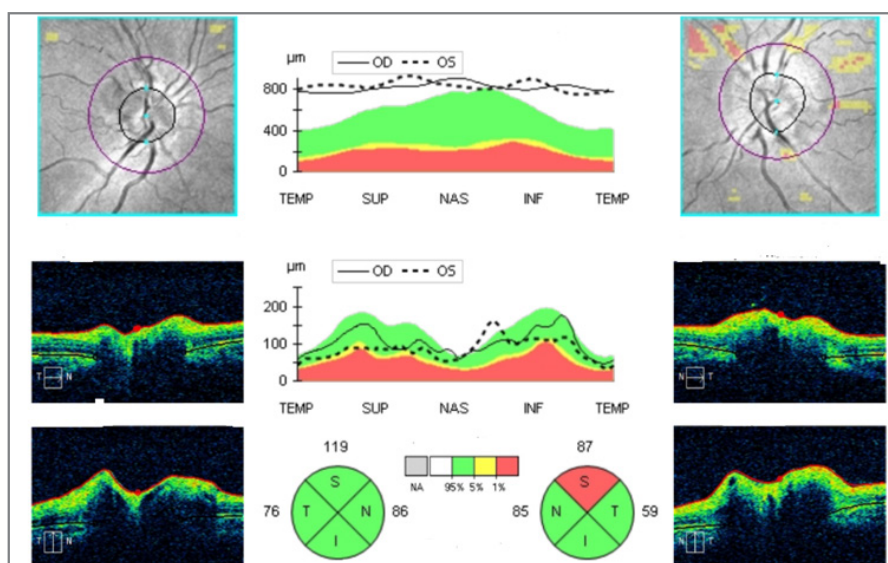


Figure 2: Optical coherence tomography (OCT) confirming the presence of bilateral papilledema.

A computed tomography scan of the brain was normal. Magnetic resonance imaging of the brain and orbits with magnetic resonance venography demonstrated indirect signs of raised intracranial pressure, including flattening of the posterior aspect

of the globe, distension of the perioptic subarachnoid space, and vertical tortuosity of the optic nerves. Cerebral venous sinus thrombosis was observed (figure 3).

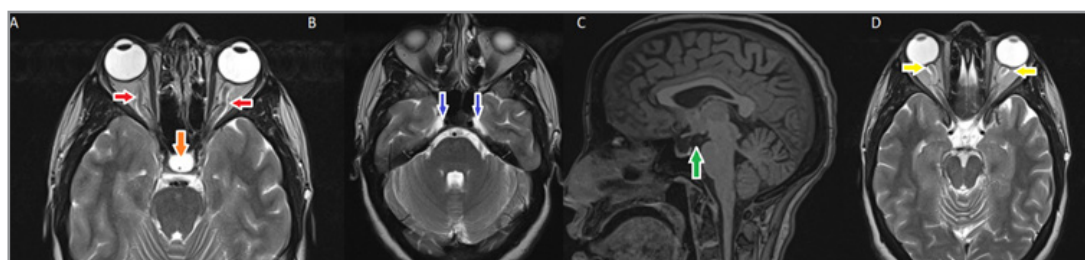


Figure 3: Radiological signs of idiopathic intracranial hypertension (IIH): dilatation of the optic nerve sheaths (A; red arrows), arachnoidocele (A; orange arrow), enlargement of Meckel's cave (B; blue arrows), empty sella (C; green arrow), and protrusion with tortuosity of the optic nerve (D; yellow arrow).

A lumbar puncture showed an opening pressure of 32 centimeters of water, with normal cerebrospinal fluid analysis. Infectious and immunological workups were unremarkable. A therapeutic lumbar puncture for cerebrospinal fluid depletion was performed at the time of diagnosis. The diagnosis of idiopathic intracranial hypertension was established. The patient was started on acetazolamide at a dosage of 4 grams per day. She subse-

quently experienced mild shortness of breath with exertion and paresthesias in the perioral area and in the extremities, consistent with known side effects of carbonic anhydrase inhibitors.

At the 3-month follow-up visit, fundus photography showed significant regression of the optic disc swelling (figure 4), and visual field testing demonstrated improvement in the previously en-

larged blind spot. A repeat lumbar puncture revealed a reduced opening pressure of 22 centimeters of water. No recurrence of

subconjunctival hemorrhage was noted.

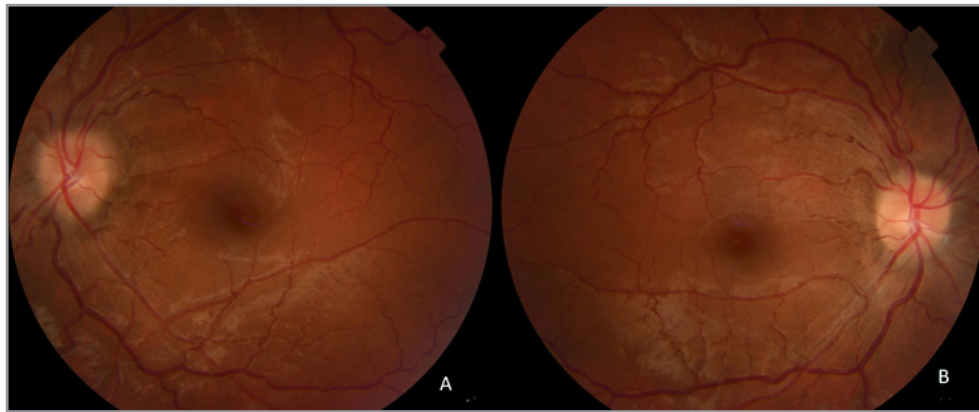


Figure 4: Fundus photographs showing regression of papilledema, now classified as stage 1 in both the right eye (A) and the left eye (B).

Discussion

Idiopathic intracranial hypertension (IIH), also known as pseudotumor cerebri, is a clinical condition characterized by elevated intracranial pressure without an identifiable intracranial lesion or hydrocephalus, and with normal cerebrospinal fluid (CSF) composition. It typically affects women of childbearing age, often with a higher body mass index (BMI). However, this case highlights an unusual presentation of IIH in a normoweight young woman without headache, revealing the variability in clinical presentation and the importance of high clinical suspicion [1, 2].

The initial manifestation in this patient—a unilateral, painless subconjunctival hemorrhage—is rare and not typically associated with intracranial hypertension. Most subconjunctival hemorrhages are benign, resulting from minor trauma, Valsalva maneuvers, hypertension, or coagulopathies [3]. In this case, the hemorrhage may have resulted from venous congestion due to elevated intracranial pressure, affecting episcleral veins. While uncommon, similar presentations have been sporadically reported, emphasizing the need to investigate further when subconjunctival hemorrhage is unexplained and persistent [4].

Classic risk factors for IIH include female sex, reproductive age, obesity, rapid weight gain, and the use of medications such as tetracyclines, vitamin A derivatives, corticosteroid withdrawal, and oraux contraceptifs. Notably, our patient had no identifiable risk factors—she was not obese, had no history of weight gain, and was not taking any medications known to precipitate IIH—making the case even more unusual [5].

The diagnosis of IIH is based on the revised Friedman criteria, which include symptoms of raised intracranial pressure (such as headache, pulsatile tinnitus, transient visual obscurations), signs of papilledema, and elevated opening pressure on lumbar puncture, in the absence of secondary causes [6].

Headache is the most common presenting symptom in IIH, occurring in approximately 75–90% of patients. It is often diffuse, pulsatile, and may worsen with Valsalva maneuvers or changes in posture. Headaches in IIH can mimic primary headache disorders such as migraine or tension-type headache, which can complicate diagnosis. However, the absence of headache does

not exclude the diagnosis. A significant minority of patients—up to 10–15%—may present without any headache, particularly in cases where visual symptoms or incidental findings such as papilledema dominate the clinical picture. These “silent” presentations are especially important to recognize, as they carry a risk of delayed diagnosis and irreversible visual loss if not promptly investigated [7, 8].

In such cases, signs such as papilledema, visual field defects, or even subtle ocular manifestations like optic disc elevation on imaging may be the only clues. The absence of headache should therefore not lead clinicians to exclude IIH from the differential diagnosis, particularly in young women with otherwise unexplained optic disc swelling or ocular symptoms [9, 10].

This variability in clinical presentation highlights the need for a thorough ophthalmological and neurological assessment, even in patients lacking classic systemic symptoms. In this case, the absence of headache makes the diagnosis more challenging. However, the presence of bilateral papilledema and visual field abnormalities, particularly blind spot enlargement and nasal step, are strong indicators of optic nerve involvement.

Differential diagnoses for optic disc edema include optic neuritis, ischemic optic neuropathy, hypertensive retinopathy, and intracranial mass lesions. In this case, the presence of preserved visual acuity, absence of systemic hypertension, and normal brain imaging ruled out most alternative causes. Magnetic resonance imaging and venography further helped to exclude structural lesions and demonstrated imaging signs typical of intracranial hypertension [11, 12].

Magnetic resonance imaging and magnetic resonance venography in this patient revealed multiple indirect signs of raised intracranial pressure : posterior globe flattening, enlargement of the perioptic subarachnoid space, and tortuous optic nerves. These findings, while not diagnostic in isolation, provide strong supportive evidence in the appropriate clinical context [13].

Lumbar puncture served both diagnostic and therapeutic purposes in this case. The elevated opening pressure confirmed the diagnosis, while the removal of cerebrospinal fluid led to partial

symptomatic and anatomical improvement. Therapeutic lumbar puncture remains a valuable first-line measure, particularly when symptoms are severe or when immediate reduction of intracranial pressure is warranted [14].

First-line pharmacologic treatment involves carbonic anhydrase inhibitors such as acetazolamide, which reduce cerebrospinal fluid production. Our patient received a high dose (4 grams per day), which led to improvement but also caused known side effects such as paresthesias and mild exertional dyspnea [15].

In patients with poor response to medical treatment or with rapidly progressive visual loss, surgical interventions may be considered. These include cerebrospinal fluid shunting procedures (lumboperitoneal or ventriculoperitoneal shunts), optic nerve sheath fenestration, and endovascular treatment [16, 17].

In selected cases of idiopathic intracranial hypertension (IIH), particularly those refractory to medical therapy or with progressive visual loss, endovascular treatment may be considered. A significant subset of patients with IIH demonstrate stenosis of the transverse sinuses on magnetic resonance venography. While it remains debated whether this stenosis is a cause or a consequence of raised intracranial pressure, venous sinus stenting has emerged as a promising and viable therapeutic option in carefully selected patients [18-20].

The decision to pursue endovascular treatment should be guided by the presence of a trans-stenotic pressure gradient, usually greater than 8–10 mmHg, as demonstrated by manometry during cerebral venography. In such cases, venous sinus stenting can relieve venous outflow obstruction, reduce intracranial pressure, and lead to improvements in symptoms such as headache and papilledema [21, 22].

Multiple studies and case series have reported favorable outcomes with transverse sinus stenting, including improved visual function and quality of life. However, it carries potential risks such as venous thrombosis, stent migration, or in-stent restenosis, and should be reserved for patients with documented pressure gradients who are non-responsive to medical therapy [23-25].

Multiple studies and case series have reported favorable outcomes with transverse sinus stenting, including improved visual function and quality of life [26]. However, it carries potential risks such as venous thrombosis, stent migration, or in-stent restenosis, and should be reserved for patients with documented pressure gradients who are non-responsive to medical therapy. Long-term follow-up is essential to assess stent patency and clinical outcomes [25].

This case illustrates an atypical and insidious presentation of idiopathic intracranial hypertension revealed by subconjunctival hemorrhage, in the absence of headache and classical risk factors. It emphasizes the importance of fundoscopic examination in any case of unexplained ocular findings and the value of lumbar puncture not only as a diagnostic tool but also as a therapeutic intervention. Awareness of such atypical presentations is crucial for timely diagnosis and preservation of vision.

Close follow-up is essential to monitor visual function and ensure resolution of papilledema. In this patient, follow-up at three months showed clear improvement in optic disc swelling and visual field defects, with a reduced opening pressure on repeat lumbar puncture [14]. Long-term prognosis is generally favorable if treatment is initiated early and vision is monitored closely. However, delay in diagnosis or treatment may result in irreversible optic nerve damage and vision loss [27].

This case illustrates an atypical and insidious presentation of idiopathic intracranial hypertension revealed by subconjunctival hemorrhage, in the absence of headache and classical risk factors. It emphasizes the importance of fundoscopic examination in any case of unexplained ocular findings and the value of lumbar puncture not only as a diagnostic tool but also as a therapeutic intervention [6]. Awareness of such atypical presentations is crucial for timely diagnosis and preservation of vision [27].

Conclusion

Idiopathic intracranial hypertension can present without typical symptoms such as headache. In rare instances, a subconjunctival hemorrhage may be the only presenting sign. This case highlights the need for thorough ophthalmologic and neurologic assessment in young patients with unexplained ocular findings, particularly when papilledema is present.

Acknowledgments

We would like to thank the Ophthalmology A Department of Ibn Sina Hospital for their valuable support in the diagnosis and management of this case. Our gratitude also extends to the patient, who kindly consented to the publication of her clinical information for educational purposes.

References

1. Friedman, D. I., Liu, G. T., Digre, K. B. (2013). Revised diagnostic criteria for the pseudotumor cerebri syndrome in adults and children. *Neurology*, 81(13), 1159-1165.
2. Wall, M. (2010). Idiopathic intracranial hypertension. *Neurologic Clinics*, 28(3), 593-617.
3. Kanski, J. J., & Bowling, B. (2011). *Clinical ophthalmology: A systematic approach* (7th ed., p. 921). Elsevier Health Sciences.
4. Wall, M. (2010). Idiopathic intracranial hypertension. *Neurologic Clinics*, 28(3), 593-617.
5. Digre, K. B., Nakamoto, B. K., Warner, J. E. A., Langeberg, W. J., Baggaley, S. K., & Katz, B. J. (2009). A comparison of idiopathic intracranial hypertension with and without papilledema. *Headache*, 49(2), 185-193.
6. Friedman, D. I., & Jacobson, D. M. (2002). Diagnostic criteria for idiopathic intracranial hypertension. *Neurology*, 59(10), 1492-1495.
7. Biousse, V., Bruce, B. B., & Newman, N. J. (2012). Update on the pathophysiology and management of idiopathic intracranial hypertension. *Journal of Neurology, Neurosurgery & Psychiatry*, 83(5), 488-494.
8. Ljubicavljević, S., & Zidverc Trajković, J. (2016). Idiopathic intracranial hypertension – Pathophysiology based on case series. *Acta Facultatis Medicae Naissensis*, 33(3), 199-209.
9. Bouthour, W., Biousse, V., & Newman, N. J. (2021). Diagnosis of optic disc oedema: Fundus features, ocular imaging

- findings, and artificial intelligence. *Neuro-Ophthalmology*, 47(4), 177-192.
10. Jung, J. J., Baek, S. H., & Kim, U. S. (2011). Analysis of the causes of optic disc swelling. *Korean Journal of Ophthalmology*, 25(1), 33-36.
 11. Bono, F., Messina, D., Giliberto, C., Cristiano, D., Brousard, G., Fera, F. (2006). Bilateral transverse sinus stenosis predicts IIH without papilledema in patients with migraine. *Neurology*, 67(3), 419-423.
 12. Farb, R. I., Vanek, I., Scott, J. N., Mikulis, D. J., Willinsky, R. A., Tomlinson, G. (2003). Idiopathic intracranial hypertension : The prevalence and morphology of sinovenous stenosis. *Neurology*, 60(9), 1418-1424.
 13. El-Demrashed, A. M. (2018). The role of lumbar puncture in management of idiopathic intracranial hypertension (IIH). *Medical Journal of Cairo University*, 86(12), 3839-3843.
 14. Ball, A. K., Clarke, C. E. (2006). Idiopathic intracranial hypertension. *The Lancet Neurology*, 5(5), 433-442.
 15. McGirt, M. J., Woodworth, G., Thomas, G., Miller, N., Williams, M., & Rigamonti, D. (2004). Cerebrospinal fluid shunt placement for pseudotumor cerebri-associated intractable headache : Predictors of treatment response and long-term outcomes. *Journal of Neurosurgery*, 101(4), 627-632.
 16. Salih, M., Enriquez-Marulanda, A., Khorasanizadeh, M., Moore, J., Prabhu, V. C., & Ogilvy, C. S. (2022). Cerebrospinal fluid shunting for idiopathic intracranial hypertension : A systematic review, meta-analysis, and implications for a modern management protocol. *Neurosurgery*, 91(4), 529-540.
 17. Higgins, J. N. P.,owler, B. K., Cousins, C., & Pickard, J. D. (2002). Venous sinus stenting for refractory benign intracranial hypertension. *The Lancet*, 359(9302), 228-230.
 18. Farb, R. I., Vanek, I., Scott, J. N., Mikulis, D. J., Willinsky, R. A., Tomlinson, G., (2003). Idiopathic intracranial hypertension : The prevalence and morphology of sinovenous stenosis. *Neurology*, 60(9), 1418-1424.
 19. Higgins, J. N. P.,owler, B. K., Cousins, C., & Pickard, J. D. (2002). Venous sinus stenting for refractory benign intracranial hypertension. *The Lancet*, 359(9302), 228-230.
 20. Virdee, J., Larcombe, S., Vijay, V., Sinclair, A. J., Dayan, M., & Mollan, S. P. (2020). Reviewing the recent developments in idiopathic intracranial hypertension. *Ophthalmology and Therapy*, 9(4), 767-781.
 21. Ahmed, R. M., Wilkinson, M., Parker, G. D., Thurtell, M. J., Macdonald, J., McCluskey, P. J., et al. (2011). Transverse sinus stenting for idiopathic intracranial hypertension : A review of 52 patients and of model predictions. *American Journal of Neuroradiology*, 32(8), 1408-1414.
 - 22.owler, B. K., Parker, G., Halmagyi, G. M., Dunne, V. G., Grinnell, V., McDowell, D., (2003). Pseudotumor cerebri syndrome : Venous sinus obstruction and its treatment with stent placement. *Journal of Neurosurgery*, 98(5), 1045-1055.
 23. Fields, J. D., Javedani, P. P., Falardeau, J., Nesbit, G. M., Dogan, A., Helseth, E. K., (2013). Dural venous sinus angioplasty and stenting for the treatment of idiopathic intracranial hypertension. *Journal of NeuroInterventional Surgery*, 5(1), 62-68.
 24. Al-Mufti, F., Dodson, V., Amuluru, K., Walia, J., Wajswol, E., Nuoman, R., (2020). Neuroendovascular cerebral sinus stenting in idiopathic intracranial hypertension. *Interventional Neurology*, 8(2-6), 164-171.
 25. Ahmed, R. M., Wilkinson, M., Parker, G. D., Thurtell, M. J., Macdonald, J., McCluskey, P. J., et al. (2011). Transverse sinus stenting for idiopathic intracranial hypertension : A review of 52 patients and of model predictions. *American Journal of Neuroradiology*, 32(8), 1408-1414.
 26. Takenobu, Y., Yang, T., Nomura, N., Inoue, M., Hashimoto, K., & Takenobu, Y. (2024). Venous sinus stenting for idiopathic intracranial hypertension : A report of two cases. *Cureus*, 16(10).
 27. Julayanont, P., Karukote, A., Ruthirago, D., Panikkath, D., & Panikkath, R. (2016). Idiopathic intracranial hypertension : Ongoing clinical challenges and future prospects. *Journal of Pain Research*, 9, 87-99.