

# A Case Report of Eagle's Syndrome – the Union of the Styloid Process and the Hyoid Bone

Ewelina Beck<sup>1</sup>, Maria Tekieli-Pawłowska<sup>2</sup>, Paweł Święch<sup>2</sup>, Witold Matusiak<sup>3</sup>, Przemysław Jaźwiec<sup>2\*</sup>

<sup>1</sup>University Clinical Hospital in Wrocław, Wrocław, Poland

<sup>2</sup>Specialist Medical Center in Polanica-Zdrój, Jana Pawła II 2, 57-320 Polanica Zdrój, Poland

<sup>3</sup>SALUS Medical Center in Kłodzko, Letnia 14, 57-300 Kłodzko, Poland

\*Corresponding author: Przemysław Jaźwiec, Specialist Medical Center in Polanica-Zdrój, Jana Pawła II 2, 57-320 Polanica Zdrój, Poland.

Submitted: 20 December 2023    Accepted: 29 January 2024    Published: 31 January 2024

**Citation:** Przemysław Jaźwiec, Ewelina Beck, Dariusz Janczak and Marek Sęsiadek (2024) Unusual Case Report of Subclavian Steal Syndrome Caused by Rare Congenital Vascular Anomaly - Left Subclavian Artery Agenesis with Auto Bypass. *Sci Set J of Med Cli Case Stu* 3(1), 01-04.

## Abstract

Eagle's syndrome is a rare condition found in 4% of the general population. It occurs due to the elongation of the styloid process or calcification of the stylohyoid ligament. Clinical image depends on which structures, including nerves, blood vessels, and soft tissues, have been compressed by the styloid process. Symptoms include oropharyngeal, neurological, and vascular manifestations. The diagnosis of Eagle's syndrome might be incidental in asymptomatic patients as well. The authors present a case of a patient with Eagle's syndrome, who has suffered from undefined throat discomfort for 6 years. Computed tomography (CT) revealed an excessively elongated styloid process that reached the hyoid bone, contributing to the formation of a new joint. This opened the pathway for further diagnostics and treatment but, most importantly, solved the patient's health problem, bothering her for many years.

**Keywords:** Eagle Syndrome, Styloid Process, Stylohyoid Ligament, Hyoid Bone

## Introduction

Eagle's syndrome is a set of clinical symptoms caused by an elongated styloid process or a calcified stylohyoid ligament, first described and named after American otolaryngologist Watt Weems Eagle (1898–1980) in 1937. The pathoetiology of the syndrome remains unclear in the majority of cases, adding to the complexity of the condition. In some instances, it has been associated with tonsillectomy, direct trauma, and wisdom tooth removal, and in some it has been an incidental finding on head and neck CT scans. Some authors suggest heterotopic calcification in patients with unbalanced calcium-phosphorus metabolism and chronic renal failure as the cause. It is a rare condition, present in 4% of the general population and symptomatic only in 4% of these. Thus, the rarity, anatomical variability, and diverse clinical manifestations of Eagle's syndrome pose significant challenges for physicians [1, 2].

In this article, the authors present the case of a 39-year-old woman with undefined throat discomfort for 6 years.

## Case Presentation

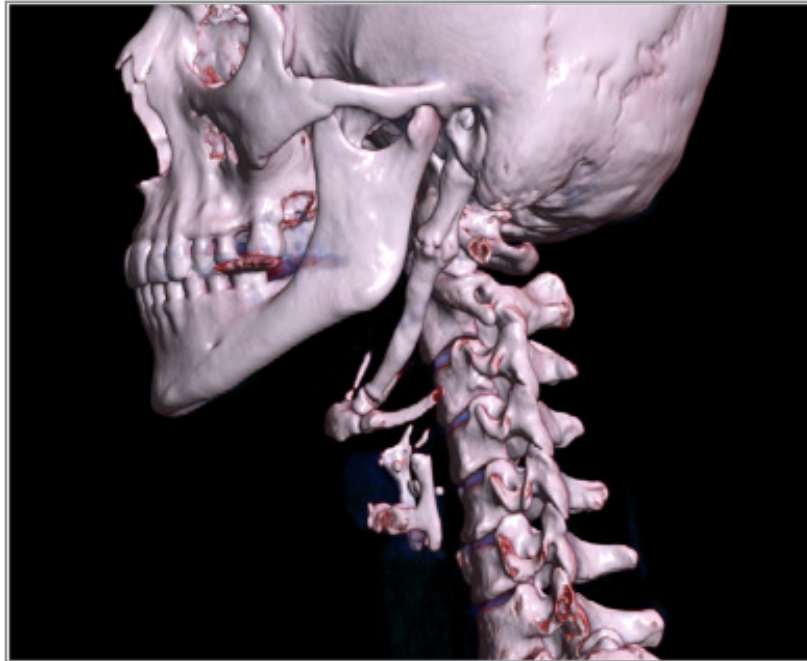The patient was a 39-year-old female, who initially reported to an otolaryngologist because of undefined discomfort in her throat for 6 years. Other complaints included a stabbing sensation in the neck, a feeling of the congested ear as well as tinnitus, otalgia, and excessive salivation.

On physical examination, head movements and opening the mouth caused pain. No neurological deficits or symptoms were present except paresthesia around the left cheek, ear, and medial 1/3 of the neck. The patient denied odynophagia, dysphagia, vision disturbances, headaches, or voice change. Currently, she does not report other complaints.

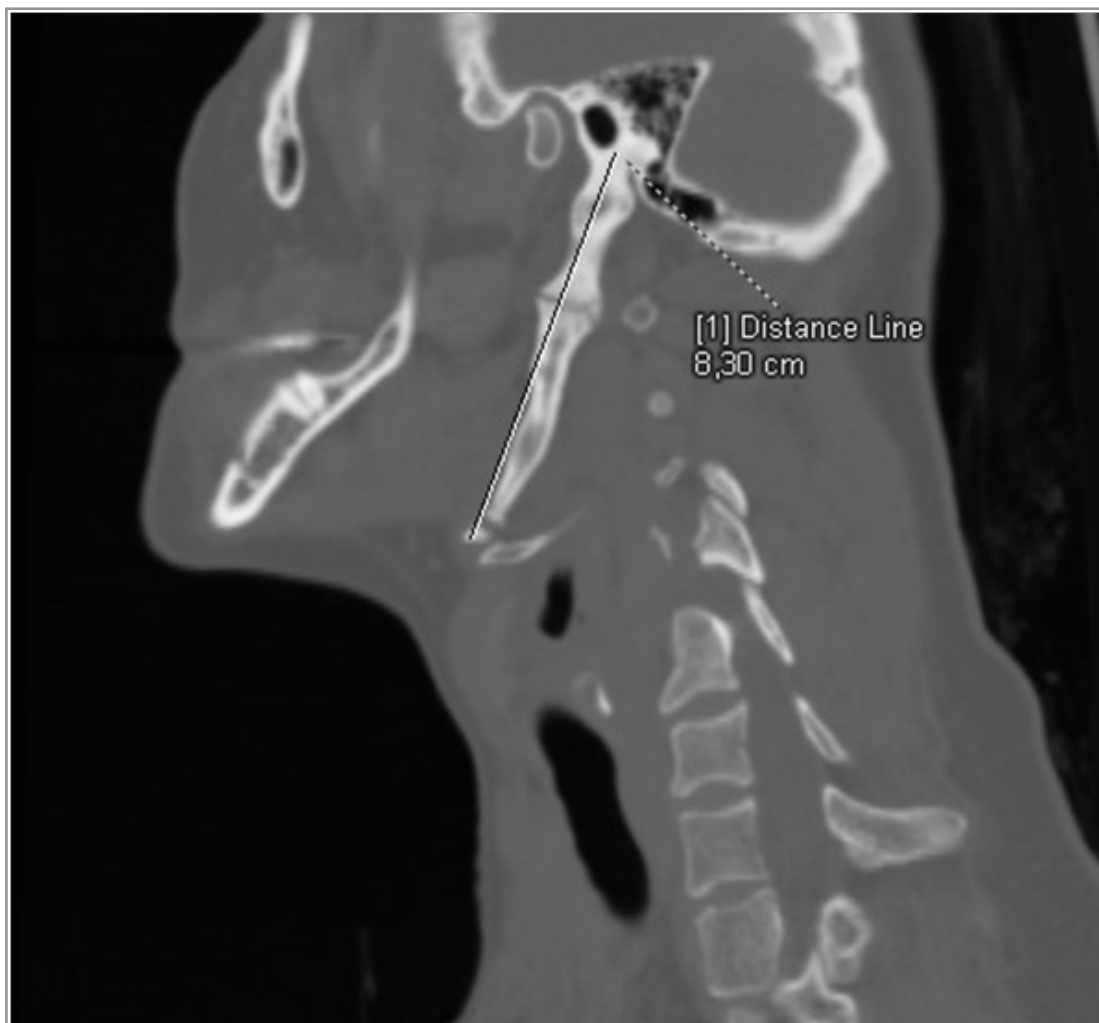In medical history, the patient was diagnosed with arterial hypertension in 2010 and since then she has been put on Captopril. In the past, she suffered cervical lymphadenitis. Apart from these, the patient has no history of past or chronic diseases and has never undergone any surgical procedures.

Computed tomography of the neck without contrast administration showed bilateral elongated styloid processes. On the left side the overall length of the styloid process was 8,3 cm. Additionally within the left styloid process we observed two false joints, one of them in the down part, reposition the hyoid bone in caudal direction (image 3). Maximum width of the left styloid process was 1,3 cm and it was located at the level of the upper false joint. Right styloid process was elongated insignificantly (3,65 cm) and didn't cause pain or any other symptoms.

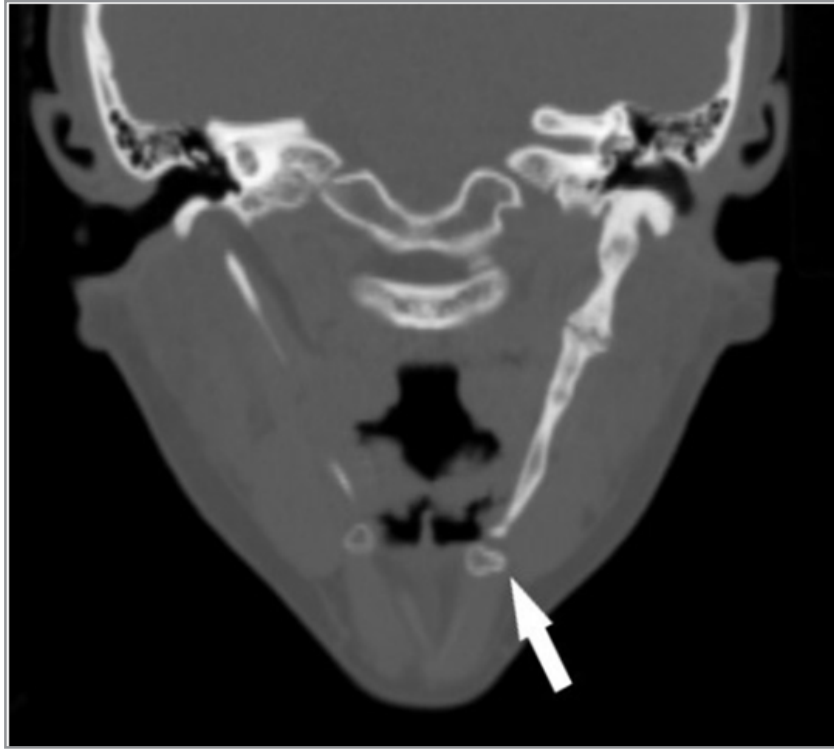
The patient was referred to the University Clinical Hospital in Wrocław for further diagnostics and treatment.



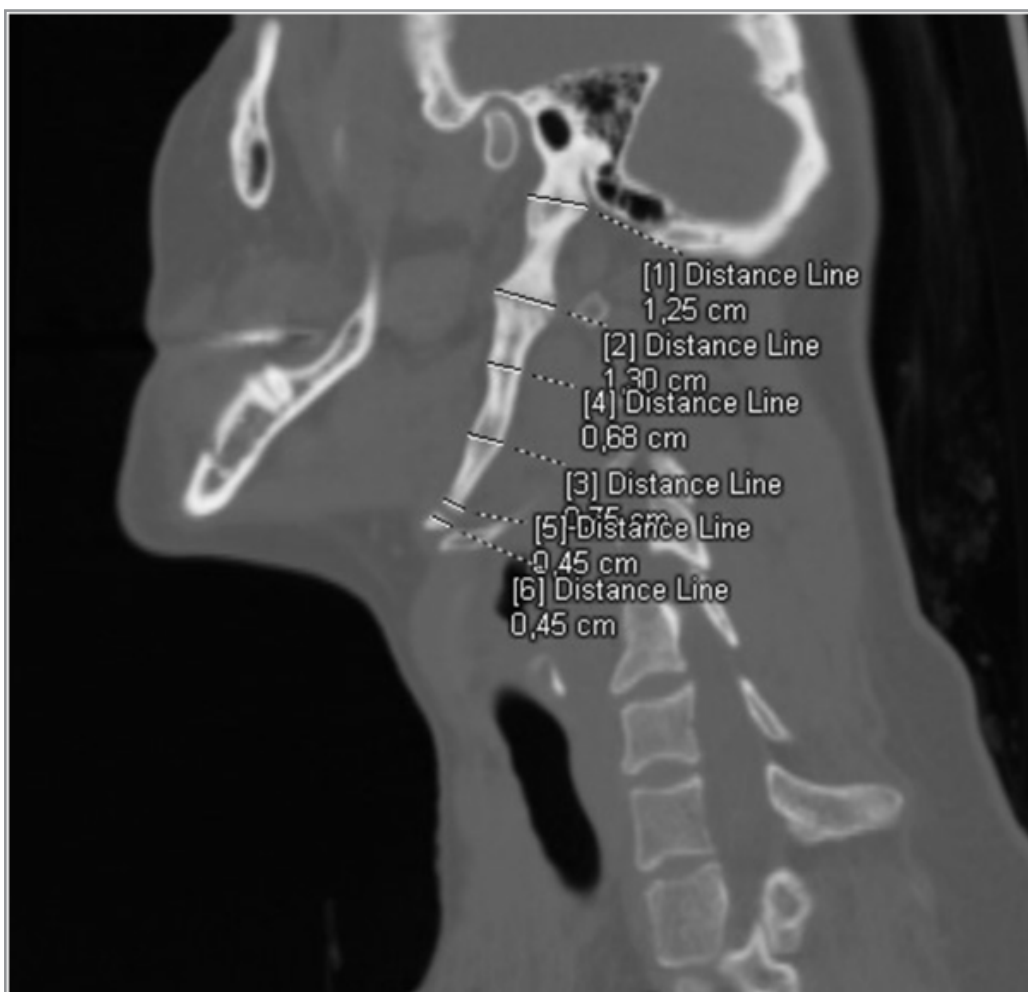
**Figure 1:** Multidetector computed tomography (MDTC) with 3D volumetric reconstructions (3D-VR) - left-sided sagittal view.



**Figure 2:** Multidetector computed tomography (MDTC) with multiplanar reconstructions (MPR) - left-sided sagittal view. Measurement of the overall length of the left styloid process.



**Figure 4:** Multidetector computed tomography (MDTC) with multiplanar reconstructions (MPR) - left-sided sagittal view.  
Measurements of the width of the left styloid process



**Figure 4:** Multidetector computed tomography (MDTC) with multiplanar reconstructions (MPR) - left-sided sagittal view.  
Measurements of the width of the left styloid process

## Discussion

The styloid process is a needle-like bony structure protruding anteroinferiorly from the inferior surface of the temporal bone and towards the hyoid bone. On average its length ranges from 2,5 cm to 3 cm. When it exceeds 3 cm, it is considered elongated. The hyoid bone is a U-shaped bone located in the anterior neck, at the base of the mandible. These two structures are connected by stylohyoid ligaments and both contribute to the unit called the styloid apparatus, along with associated ligaments and muscles. Anatomically they do not make a direct connection with each other. However, the presented case shows a different situation, in which an excessively long styloid process reaches the hyoid and these two form a joint. Altered anatomical relations of the regional structures led to the patient's symptomatic manifestation of Eagle's syndrome [1-5].

Depending on the clinical presentation, there are two types of Eagle's syndrome: classic Eagle's syndrome – due to compression of the cranial nerves V, VII, VIII, IX, or X, - and vascular Eagle's syndrome – due to compression of the internal or external carotid artery. The first one is typically characterized by facial/cervical pain exacerbated by head movement, otalgia, dysphagia, odynophagia, foreign body sensation, headache, and tinnitus. On the other hand, the latter manifests as carotidynia, as a result of sympathetic plexus irritation, or ischemic symptoms such as visual disturbance, syncope, and aphasia. In extreme cases, TIA, ischemic stroke, or carotid dissection might occur [1-3, 6-10].

Eagle's syndrome might be challenging to diagnose because of its nondistinctive clinical image. While managing a patient with head and neck symptoms, a physician should first consider other possible differential diagnoses, primarily facial neuralgia, malignancy, and temporomandibular joint disorder. The diagnosis is usually suggested based on a patient's medical history and physical examination, as an elongated styloid process may be palpable. The classical X-ray enables measuring the process's length. It is accepted that the best method to visualize the styloid process, its angulation, and anatomical relation with nearby structures is multi-row-detector computed tomography (MDCT) with 3D reconstructions. This method appears to be sufficient enough not only to make the final diagnosis but also to plan further treatment. Thus, it is considered the gold standard [1, 3, 11].

Treatment includes both conservative and surgical methods. To alleviate pain, patients are put on analgesics, antidepressants, and anticonvulsants. Transpharyngeal injections of steroids, lidocaine, and non-steroidal anti-inflammatory drugs (NSAID) also can be applied. If a patient does not respond to conservative treatment, they may be suited for a surgical styloidectomy. There are two approaches to the procedure – intraoral and extraoral. According to some authors, the success rate of the surgery is 80% [1, 2, 12].

## Conclusion

Eagle's syndrome is a rare condition found in 4% of the general population. Its manifestation might be asymptomatic or symptomatic with various clinical images. Usually, patients seek medical help because of nonspecific symptoms such as a feeling of a foreign body in the throat, dysphagia, and pain localized in the temporomandibular region, neck, and ear, bothering them for years before the initial diagnosis is established. Specialists of different specializations are often involved in the diagnostic process, especially laryngologists and neurologists. Imaging techniques are essential to confirm the initial diagnosis, make the final one, and plan further treatment. MDCT and 3D reconstructions have been accepted as the gold standard.

## References

1. Maria R Bokhari, Charles Graham, Michael Mohseni (2023) Eagle Syndrome. StatPearls Publishing PMID: 28613540.
2. Singh G, Sharma R, Gaillard F, et al. (2024) Eagle syndrome. Reference article, Radiopaedia.org.
3. Irena Wolińska, Przemysław Jaźwiec, Maria Pawłowska, Paweł Gać, Rafał Poręba, et al. (2021) Eagle's Syndrome as a Cause of Discomfort and the Subjective Presence of a Foreign Body in the Throat. *Diagnostics (Basel)* 11: 1832.
4. Abdulaziz K Abuhaimed, Reinier Alvarez, Ritesh G Menezes (2024) Anatomy, Head and Neck, Styloid Process. StatPearls Publishing PMID: 31082019.
5. Susan Standring (2020) Gray's Anatomy: The Anatomical Basis of Clinical Practice. Susan Standring. Forty-second ed. 737, ISBN 978-0-7020-7707-4.
6. Alper Ceylan, Ahmet Köybaşıoğlu, Fatih Celenk, Oğuz Yilmaz, Sabri Uslu (2008) Surgical treatment of elongated styloid process: experience of 61 cases. *Skull Base*. 18: 289-295.
7. Murtagh RD, Caracciolo JT, Fernandez G (2001) CT findings associated with Eagle syndrome. *AJNR Am J Neuroradiol* 22: 1401-1402.
8. Lorman JG, Biggs JR (1983) The Eagle syndrome. *AJR Am J Roentgenol*. 140: 881: 882.
9. Faivre A, Abdelfettah Z, Rodriguez S, Nicoli F (2009) Neurological picture. Bilateral internal carotid artery dissection due to elongated styloid processes and shaking dancing. *J Neurol Neurosurg Psychiatry* 80: 1154-1155.
10. Chuang WC, Short JH, McKinney AM, Anker L, Knoll B, et al. (2007) Reversible left hemispheric ischemia secondary to carotid compression in Eagle syndrome: surgical and CT angiographic correlation. *AJNR Am J Neuroradiol* 28:143-145.
11. Saccomanno S, Greco F, DE Corso E, Lucidi D, Deli R, et al. (2018) Eagle's Syndrome, from clinical presentation to diagnosis and surgical treatment: a case report. *Acta Otorhinolaryngol Ital* 38: 166-169.
12. Shivani Jain, Ashok Bansal, Samrity Paul, Deepti Vashisht Prashar (2012) Styloid-stylohyoid syndrome. *Ann Maxillofac Surg* 2: 66-69.