

# Outcomes of Semirigid Ureteroscopy with Pneumatic Lithotripsy for Upper Ureteric Stones: A Five-year Experience in Yemen (June 2018–June 2023)

**Mohammed Naji Obad**

Urologist, 48-typical Hospital and Alyemen Alsaeed Hospital, Assistant Professor, 21 Medical University, Yemen

**\*Corresponding author:** Mohammed Naji Obad, Urologist, 48-typical Hospital and Alyemen Alsaeed Hospital, Assistant Professor, 21 Medical University, Yemen

**Submitted:** 09 July 2025    **Accepted:** 17 July 2025    **Published:** 21 July 2025

**doi** <https://doi.org/10.63620/MK.SSJMCSS.2025.1071>

**Citation:** Obad, M. N. (2025). Outcomes of Semirigid Ureteroscopy with Pneumatic Lithotripsy for Upper Ureteric Stones: A Five-year Experience in Yemen (June 2018–June 2023). *Sci Set J of Med Cli Case Stu*, 4(4), 01-05.

## Abstract

**Introduction and objectives:** Urolithiasis is the third most common urological condition, following urinary tract infection and prostate disease. It requires active management due to its high prevalence, recurrence rates, and potential complications. One treatment modality involves the use of a semi-rigid ureteroscope with pneumatic lithotripsy (SUPL).

This study aimed to evaluate the outcomes, effectiveness, safety, and feasibility of SUPL for the treatment of upper ureteric stone (UUS) in low-income countries, such as Yemen, where advanced lithotripter technologies are not available.

**Methods:** comprehensive retrospective analysis was conducted on a cohort comprising 212 patients. Treated for UUS utilized Storz semi-rigid ureteroscope with Swiss pneumatic lithotripter; between June 2018 and June 2023 at 48 typical and Alyemen-Alsaeed hospitals Sana'a, all procedures were performed by one urologist.

**Results:** A total of 212 patients underwent SUPL for UUS, with an average age of 45.5 years and a predominantly male population (62.7%). The mean operative time was 46.5 minutes (range: 24-69 minutes). Stone sizes ranged from 8 to 22 mm, categorized into two groups based on size: 139 patients had stones  $\leq 1.5$  cm (including 17 cases with stones  $< 1$  cm), and 73 patients had stones  $> 1.5$  cm.

The overall stone-free rate (SFR) was 89.2% (189/212). Specifically, for patients with stones  $\leq 1.5$  cm, the SFR was 93.5% (130/139), with a 95% confidence interval ranging from 88.2% to 96.7%. Conversely, patients with stones  $> 1.5$  cm exhibited a slightly lower SFR of 80.8% (59/73), with a 95% confidence interval ranging between 70.1% and 88.0%. Of the total number of patients, fourteen (6.6%) experienced retrograde migration of stones to the renal pelvis.

Intraoperative ureteral perforation, observed in four cases (1.9%), resulted in the termination of the procedure. Previous ureteral strictures impeding the advancement of the ureteroscope were noted in five cases (2.3%). Postoperative urinary tract infections (UTIs) were detected in 8.7% of patients. However, no severe complications such as sepsis or avulsion were reported during the study.

**Conclusion:** SUPL emerges as a successful treatment method for UUS in regions with limited resources. The procedure exhibited a notably high SFR, especially for stones equal to or smaller than 1.5 cm. However, it is crucial to carefully consider and manage potential complications, including stone retropulsion, UTIs, and perforations, to optimize patient outcomes.

**Keywords:** Ureteroscopy, Pneumatic Lithotripsy, Upper Ureteric Stones, Yemen, Stone-Free Rate.

## Introduction

Urolithiasis is the third most common urological condition, following urinary tract infection and prostate disease. Historical documents reporting stone-related illnesses and efforts to dissolve them date back to 3200–1200 BCE in ancient Mesopotamia [1]. Although prevalence ranges from 1–5% in Asia to 7–13% in North America, their prevalence remains undetermined in Yemen [2]. Anatomically, the upper segment of the ureter extends from the pelviureteric junction to the upper sacroiliac joint [3]. Key factors influencing the spontaneous passage of stones are the transverse diameter and the position of the stone within the ureter at presentation [4].

While SUPL is considered an established procedure for treating such conditions, many low-income countries lack access to advanced lithotripter technology like laser options [5]. Pneumatic lithotripsy employs ballistic forces fragmentation techniques that are safe, durable, compatible with various stone compositions and cost-effective but pose challenges related to potential migration during treatment [6–9].

**Objectives:** This study aimed to evaluate the outcomes, effectiveness, safety, and feasibility of SUPL for the treatment of UUS in low-income countries, such as Yemen, where advanced lithotripter technologies are not available.

## Methods and Materials

### Study Design

This retrospective study analyzed the outcomes of SUPL in the treatment of UUS. The treatment was conducted by a single urologist from June 2018 to June 2023 at 48 typical and Al Yemen- Alsaeed Hospitals in Sanaa, Yemen [10].

### Patient Selection

Inclusion criteria involved patients treated by the author using SUPL for ureteral stones above the iliac crest. Exclusion criteria comprised patients with distal or middle ureteral stones, those undergoing alternative procedures, or those with incomplete data [11].

**Preoperative Assessment:** Patients underwent urological ultrasound scans and plain kidney, ureter, and bladder (KUB) films. Abdominal computed tomography (CT) was performed when previous imaging techniques failed to detect or accurately assess stones. Urinalysis and cultures were conducted for all patients, and those with bacteriuria received treatment based on culture results [12].

### Surgical Procedures

Under general anesthesia, the surgical steps included identifying the ureteral orifice, performing retrograde ureterography, and advancing a safety floppy tip 0.035-inch guidewire. A Storz ure-

teroscope (7 French, 43 cm long) facilitated stone localization, disintegration using a Swiss pneumatic lithoclast, and retrieval with a Dormia basket. Smaller fragments were managed with a grasper, and ureterography confirmed the absence of perforation [13].

### Outcome Assessment

Procedural success, defined as complete calculi extraction or fragment reduction to less than 2 mm, was evaluated in patients 1 month postoperatively using abdominal ultrasonography, KUB plain films, and, if necessary, abdominal CT scans.

### Data Collection and Analysis

Patient records supplied information on demographics, stone size, operative details, stone-free rate, and complications. Descriptive statistics summarized sample characteristics, and subgroup analyses were conducted using the chi-square test [14].

## Results

A total of 212 patients underwent SUPL for treating UUS, with patients ranging in age from 18 to 73 years, and a mean age, and predominantly male (62.7%) while 37.3% were female. The mean operative time was 46.5 minutes (range: 24–69 minutes). Stone sizes ranged from 8 to 22 mm, with 139 patients with stones measuring  $\leq 1.5$  cm (including 17 cases with stones  $< 1$  cm) and 73 patients with stones  $> 1.5$  cm. The overall procedural SFR was 89.2% (189 out of 212 cases) [15]. Specifically, for patients with stones  $\leq 1.5$  cm, the SFR was 93.5% (130/139), with a 95% confidence interval ranging from 88.2% to 96.7%. Conversely, patients with stones  $> 1.5$  cm exhibited a slightly lower SFR of 80.8% (59/73), with a 95% confidence interval ranging between 70.1% and 88.0%.

Of the total number of patients, fourteen (6.6%) experienced stone retrograde migration to the renal pelvis, including eight cases with stones  $\leq 1.5$  cm and six cases with stones  $> 1.5$  cm. Management involved inserting Double J (DJ) stents, followed by referral to the Extracorporeal Shock Wave Lithotripsy (ESWL) department.

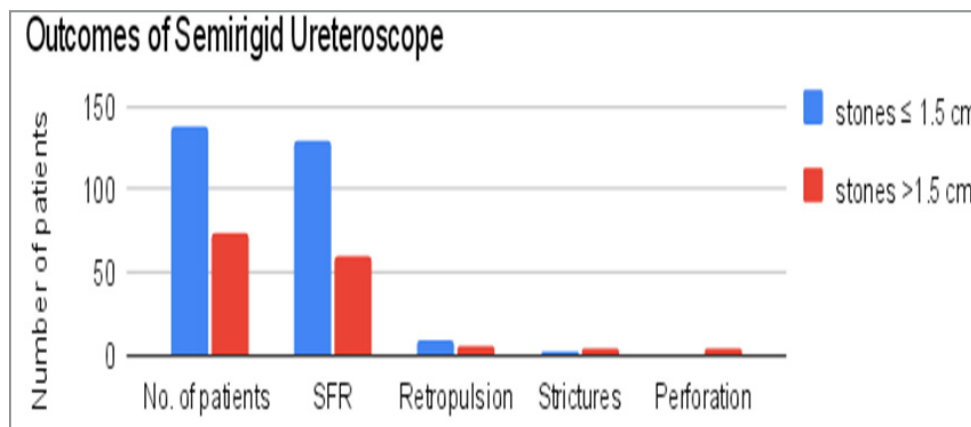
Intraoperative ureteral perforation occurred in four cases (1.9%), leading to procedure termination. This complication exclusively occurred when the stone size exceeded 1.5 cm and was managed by DJ stenting [16].

Ureteral strictures impeding ureteroscope advancement were noted in five cases (2.3%), with one case involving stones  $\leq 1.5$  cm and four cases involving stones  $> 1.5$  cm. Management strategies included using a DJ stent in four cases and performing open ureterolithotomy with a DJ stent in one case with a stone size  $> 1.5$  cm, "Due to difficulties encountered in guiding the wire past the stones [17].

Postoperative urinary tract infections (UTIs) were detected in 8.7% of patients. However, no severe complications such as sepsis or avulsion were reported during the study.

**Table 1:** Outcomes of semi-rigid ureteroscope

	stones $\leq 1.5$ cm	stones $>1.5$ cm	Total	P value	
Number of cases	139	73	212		
SFR	130	59	189		0.0047
Retropulsion	8	6	14		
Strictures	1	4	5		
Perforation	0	4	4	$<0.05$	



**Figure 1:** Outcomes of Semirigid Ureteroscope

## Discussion

Effectively managing UUS, particularly in resource-limited settings, has long posed significant challenges.

Rewrite and phrased For stones  $< 1$  cm, the recommended initial treatment method is ESWL. It has been found to have limited success, with larger stones [18, 19]. However, the use of ESWL is not common in low-income countries due to the expensive machines required. Moreover, the high cost of flexible ureteroscopy with laser lithotripsy further exacerbates the issue of accessibility in low-income countries.

In response to these challenges, a recent study conducted in Yemen light on a potential solution SUPL. This study demonstrates a procedural success rate of 89.2%, making it a feasible alternative for physicians to consider. While caution is advised when treating larger stones over 1.5 cm due to a slightly lower stone-free rate, the statistical significance of this difference ( $p$  value  $< 0.05$ ), underscores the importance of exploring alternative approaches for these cases.

The study also reported certain complications, including stone

migration back into the kidney (6.6% of cases), intraoperative ureteral perforations (four cases), and previous ureteral strictures (six cases). However, it is worth noting that major complications such as avulsion or sepsis were notably absent, highlighting the safety profile of this treatment approach.

These findings suggest that SUPL holds promise as an effective and cost-conscious treatment option for UUS, particularly in low-income environments. Comparing our study's results with previous research (see Table 2), find that our method aligns well with reported success rates for smaller stones, outperforming some and falling slightly short of others. For larger stones, our study's competitive 80.8% stone-free rate compares favorably with similar studies.

Physicians operating in resource-limited settings should take note of these findings, which offer a promising solution to the challenges associated with UUS. As access to healthcare remains a pressing concern in many regions, SUPL can play a vital role in expanding treatment options and improving patient outcomes.

**Table2:** Comparison of Ureteroscopic Interventions for Proximal Ureteral Calculi

Study	Patients (n)	Stone Size (mm)	Procedural Success Rate (%)	Stone migration(%)	Ureteral perforations(%)	Urosepsis (%)
My Study	212	8-22	89.3 93.5 ( $\leq 1.5$ cm), 80.8 ( $>1.5$ cm)	Mursi et al. (10) Bapat et al. (11)	1.9	0

Mursi et al. (10)	95	11.8 (mean)	83	7	7	2
Bapat et al. (11)	394	12.3 (mean)	86		9 cases	11 cases
Bangash et al. (12)	103	>10	83.5			1 case
Ather et al. (13)	265	>30 mm2	74			0
Fasihuddin and Hasan (14)	125	6-22	93.8			38.9
Aghamir et al. (15)	115	5-22	89.5	5.5	0.5	
Sozen et al. (16)	36	7.4 mean	94.6	2	1.4	3
Fong et al. (17)	51	9 mean	80	8		
Preminger et al. (5)	2242	<10 >10	80 79			
Perez Castro et al. (18)	2656	81mm2	84.5			

## Conclusion

SUPL appears to be a successful treatment method for UUS in countries with limited resources. The procedure demonstrated a high SRF, particularly for stones equal to or smaller than 1.5 cm. However, potential complications such as stone retropulsion, UTI, and perforations should be carefully considered and managed to optimize patient outcomes.

## Conflicting Interests

The author declares no potential conflicts of interest related to the research, authorship, and publication of this article.

## Funding

The authors received no financial support for the research, authorship, and/or publication of this article.

## Ethical Approval

Our institution does not require ethics approval for reporting individual case reports.

## References

1. Tefekli, A., & Cezayirli, F. (2013). The history of urinary stones: In parallel with civilization. *Scientific World Journal*, 2013, 423964. <https://doi.org/10.1155/2013/423964>
2. Sorokin, I., Mamoulakis, C., Miyazawa, K., Rodgers, A., Talati, J., & Lotan, Y. (2017). Epidemiology of stone disease across the world. *World journal of urology*, 35(9), 1301–1320. <https://doi.org/10.1007/s00345-017-2008-6>
3. Elkoushy, M. A. (2021). Surgical, radiologic, and endoscopic anatomy of the kidney and urine. In A. J. Wein, L. R. Kavoussi, A. W. Partin, et al. (Eds.), *Campbell-Walsh Urology* (pp. 1873–1874). Elsevier.
4. Coll, D. M., Varanelli, M. J., & Smith, R. C. (2002). Relationship of spontaneous passage of ureteral calculi to stone size and location as revealed by unenhanced helical CT. *AJR. American journal of roentgenology*, 178(1), 101–103. <https://doi.org/10.2214/ajr.178.1.1780101>
5. Preminger, G. M., Tiselius, H. G., Assimos, D. G., Alken, P., Buck, A. C., Gallucci, ... & Wolf, J. S., Jr, American Urological Association Education and Research, Inc., & European Association of Urology (2007). 2007 Guideline for the management of ureteral calculi. *European urology*, 52(6), 1610–1631. <https://doi.org/10.1016/j.eururo.2007.09.039>
6. Michel, M. S., Honeck, P., & Alken, P. (2008). New endourologic technology for simultaneous holmium:YAG laser lithotripsy and fragment evacuation for PCNL: Ex-vivo comparison to standard ultrasonic lithotripsy. *Journal of Endourology*, 22, 1537–1539. <https://doi.org/10.2214/ajr.178.1.1780101>
7. Garg, S., Mandal, A. K., Singh, S. K., Naveen, A., Ravimohan, M., Aggarwal, M., Mete, U. K., & Santosh, K. (2009). Ureteroscopic laser lithotripsy versus ballistic lithotripsy for treatment of ureteric stones: a prospective comparative study. *Urologia internationalis*, 82(3), 341–345. <https://doi.org/10.1159/000209369>
8. Binbay, M., Tepeler, A., Singh, A., Akman, T., Tekinaslan, E., Sarilar, O., Baykal, M., & Muslumanoglu, A. Y. (2011). Evaluation of pneumatic versus holmium:YAG laser lithotripsy for impacted ureteral stones. *International urology and nephrology*, 43(4), 989–995. <https://doi.org/10.1007/s11255-011-9951-8>
9. Hendlin, K., Weiland, D., & Monga, M. (2008). Impact of irrigation systems on stone migration. *Journal of Endourology*, 22, 453–458. <https://doi.org/10.1089/end.2007.0260>
10. Mursi, K., Elsheemy, M. S., Morsi, H. A., Ali Ghaleb, A. K., & Abdel-Razzak, O. M. (2013). Semi-rigid ureteroscopy for ureteric and renal pelvic calculi: Predictive factors for complications and success. *Arab journal of urology*, 11(2), 136–141. <https://doi.org/10.1016/j.aju.2013.04.008>
11. Bapat, S. S., Pai, K. V., Purnapatre, S. S., Yadav, P. B., & Padye, A. S. (2007). Comparison of holmium laser and pneumatic lithotripsy in managing upper-ureteral stones.

- Journal of endourology, 21(12), 1425–1427. <https://doi.org/10.1089/end.2006.0350>
12. Bangash, M., Nazim, S. M., Jamil, S., Abdul Ghani, M. O., & Naeem, S. (2020). Efficacy and Safety of Semi-rigid Ureteroscopic Lithotripsy (URS) for Proximal Ureteral Stone  $\geq 10$  mm. Journal of the College of Physicians and Surgeons--Pakistan: JCPSP, 30(10), 1058–1062. <https://doi.org/10.29271/jcpsp.2020.10.1058>
  13. Ather, M. H., Nazim, S. M., & Sulaiman, M. N. (2009). Efficacy of semirigid ureteroscopy with pneumatic lithotripsy for ureteral stone surface area of greater than 30 mm<sup>2</sup>. Journal of endourology, 23(4), 619–622. <https://doi.org/10.1089/end.2008.0182>
  14. Fasihuddin, Q., & Hasan, A. T. (2002). Ureteroscopy (URS): An effective interventional and diagnostic modality. Journal of the Pakistan Medical Association, 52(11), 510–522. <https://pubmed.ncbi.nlm.nih.gov/12585370/>
  15. Aghamir, S. K., et al. (2003). Treatment of ureteral calculi with ballistic lithotripsy. Journal of Endourology, 17, 887–890. <https://doi.org/10.1089/089277903772036208>
  16. Sozen, S., et al. (2003). Management of ureteral stones with pneumatic lithotripsy: Report of 500 patients. Journal of Endourology, 17(9), 721–724. <https://doi.org/10.1089/089277903770802236>
  17. Fong, Y. K., Ho, S. H., Peh, O. H., Ng, F. C., Lim, P. H., Quek, P. L., & Ng, K. K. (2004). Extracorporeal shockwave lithotripsy and intracorporeal lithotripsy for proximal ureteric calculi--a comparative assessment of efficacy and safety. Annals of the Academy of Medicine, Singapore, 33(1), 80–83.
  18. Perez Castro, E., Osther, P. J., Jinga, V., Razvi, H., Stravodimos, K. G., Parikh, K., Kural, A. R., de la Rosette, J. J., & CROES Ureteroscopy Global Study Group (2014). Differences in ureteroscopic stone treatment and outcomes for distal, mid-, proximal, or multiple ureteral locations: the Clinical Research Office of the Endourological Society ureteroscopy global study. European urology, 66(1), 102–109. <https://doi.org/10.1016/j.eururo.2014.01.011>
  19. Türk, C., Petřík, A., Sarica, K., et al. (2016). EAU guidelines on interventional treatment for urolithiasis. European Urology, 69, 475–482. <https://doi.org/10.1016/j.juro.2015.12.022>