

Malignant Melanoma of Nasal Cavity: Case Report and Review of the Literature

Niema Benkhraba^{1,3*}, Zainab Benyahia^{1,3}, Razika Bencheikh^{2,3}, Mohamed Anas Benbouzid^{2,3}, Abdelilah Oujilal^{2,3}, & Leila Essakalli Houssyn^{2,3,4}

¹Resident physician in otolaryngology, Department of Otolaryngology, Head and Neck Surgery, Ibn Sina University Hospital, Rabat, Morocco

²Professor of otolaryngology, Department of Otolaryngology, Head and Neck Surgery, Ibn Sina University Hospital, Rabat, Morocco

³Faculty of Medicine and Pharmacy of Rabat, Mohamed V University, Rabat, Morocco

⁴ENT Department, Rabat Specially Hospital, Ibn Sina University Hospital, Hafiane-cherkaoui Avenue, 10100 Rabat, Morocco

*Corresponding author: Niema Benkhraba, Faculty of Medicine and Pharmacy of Rabat, Mohamed V University, Rabat, Morocco.

Submitted: 14 February 2023 Accepted: 20 February 2023 Published: 23 February 2024

doi <https://doi.org/10.63620/MKWJMM.2024.1002>

Citation: Benkhraba, N., Benyahia, Z., Bencheikh, R., Benbouzid, M. A., Oujilal, A., & Essakalli Houssyn, L. (2024). Malignant Melanoma of Nasal Cavity : Case Report and Review of the Literature. *Wor Jour of Molecu Medicine*, 1(1), 01-04.

Abstract

Malignant Melanoma of nasal cavity is an extremely rare tumour and is more aggressive than its cutaneous counterpart. Primary malignant melanoma of nasal cavity arise from melanocytes located in the mucous membrane. Only 0.5% of malignant melanoma arises in nasal cavity. We report a case of malignant melanoma of the nasal cavity in a 40 year old patient, the diagnosis is histological, and the treatment was based on surgery and radiotherapy.

Keywords: Melanoma, Nasal Cavity, Mucosa, Negative Surgical Margin

Résumé

Le mélanome malin des fosses nasales est une tumeur extrêmement rare et plus agressive que son homologue cutanée. Le mélanome malin primitif de la cavité nasale provient de mélanocytes situés dans la membrane muqueuse. Seulement 0,5 % des mélanomes malins surviennent dans la cavité nasale. Nous rapportons un cas de mélanome malin des fosses nasales chez une patiente de 40 ans, le diagnostic est histologique, et le traitement a été basé sur la chirurgie et la radiothérapie.

Introduction

Primary malignant melanoma of the nose and paranasal sinus mucosa is a rare disease and seen in less than 1% among all melanomas. Malignant melanomas have 2 origins: cutaneous and mucosal. The mucosal form has a worse prognosis because of its aggressiveness compared with that of the cutaneous form. Mucosal melanomas often occur at a rate of 2% to 3% among all melanomas and are typically found in the nasal cavity and paranasal sinuses. Generally, it is more common in males and in those older than 50 years.

Case Report

This is a 40-year-old patient, who has had unilateral left nasal obstruction for 1 year, associated with anterior and posterior rhi-

norrrhea and hyposmia, complicated 3 months ago by episodes of epistaxis. Clinical examination reveals a left paralateral-nasal swelling, with nasal endoscopy a purplish fleshy process of the lateral wall of the left nasal cavity, taking the lower turbinate and filling the anterior part up to the vestibule, no bleeding on contact.

The CT scan shows a lesion process of the left nasal cavity, of tissue density, moderately enhanced after injection, blowing out the bony walls without associated lysis, extended to the nasal tear duct and pushing back the nasal septum on the right. MRI appearance in favor of a tumor process of the left inferior turbinate, clear contours in moderate T1 and T2 hypersignal, weakly enhanced after gadolinium injection, measuring: 39*19mm, without extra-nasal extension.

The biopsy came back in favor of an undifferentiated malignant tumor process. Excision of the tumor process with lower left turbinectomy was performed. The anatomopathological study of the tumor samples came back in favor of melanoma. Postoperative radiotherapy was given to the patient and the patient is alive one year after surgery.

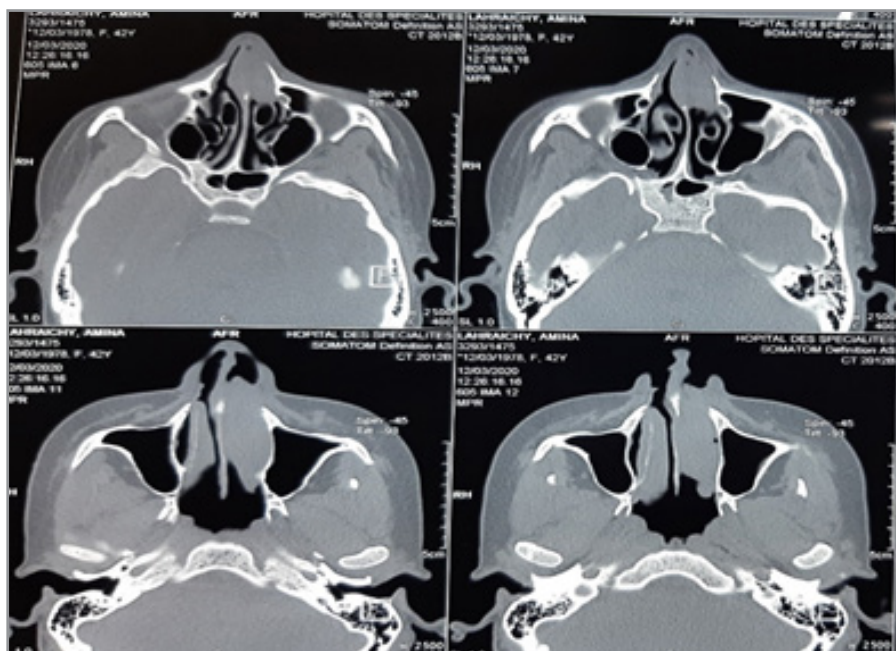


Figure 1: CT scan showing a process of the left nasal cavity blowing out the bony walls and extending to the nasal lacrimal duct, without associated lysis.

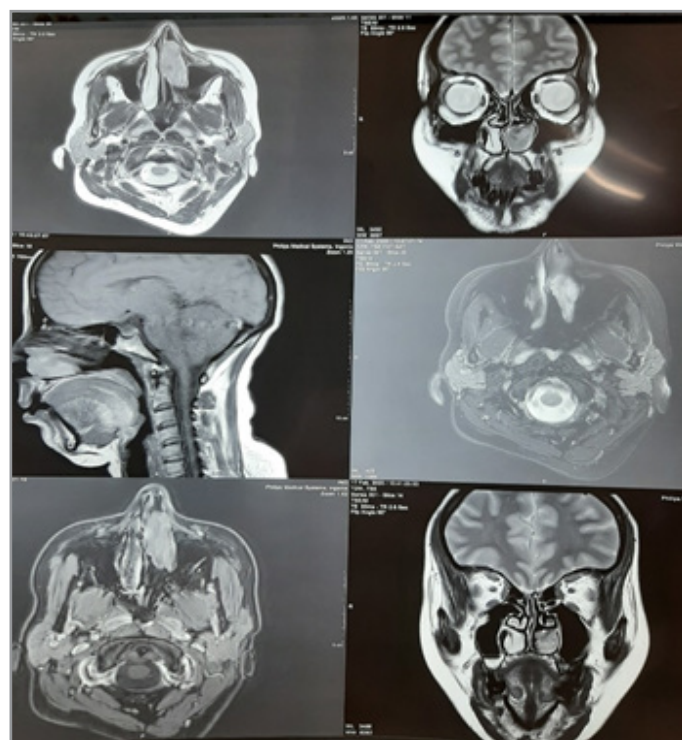


Figure 2: MRI appearance favoring a tumor process in the left lower turbinate without extra nasal extension.

Discussion

Mucosal MMs of the nasal cavity and the paranasal sinuses are rare, accounting for only 1.3% of all MMs in routine ENT practice [1, 2]. Nasal melanomas are tumors that present with high-grade malignancy; they have a different biological nature and epidemiological features to cutaneous melanomas and have a worse prognosis than those. The clinical course of MMs is often unpredictable. Many patients have lymph nodes, distant and

distant lung and hepatic metastases at the time of diagnosis, and recurrences may occur sporadically, even after some years.

Epistaxis and nasal obstruction were the most frequent presenting symptoms in reported series. It's difficult, particularly with large lesions, to determine the exact site of origin. The origin can be determined only if the main mass is resected intraoperatively. In a review of 190 patients with sinonasal melanomas, 148

(78%) were found in the nasal cavity and 42 (22%) were found in the sinus. The nasal septum accounted for 44 (30%), the lateral nasal wall for 44 (30%), the inferior turbinates for 12 (8%), and the middle turbinates 7(5%) of the nasal melanomas [3-11].

Various methods including surgery, irradiation alone, irradiation with surgery or irradiation with surgery and chemotherapy have been used to treat MM of the nose. Different surgical interventions may be applicable, depending on the extent of the lesion, for example, lateral rhinotomy, maxillectomy, craniofacial resection, or endoscopic resection.

Neck dissection is not recommended for patients who in the setting of No neck. However, neck dissection should be done when the patient presents with a metastatic lymph node [9]. The most important point that we want to draw attention to with respect to surgical intervention is that melanotic fields demonstrating maculation metastasis may be present in the other mucosal regions through the nose where the mass is contacted or not. Ronaldo and his colleagues have emphasized the intranasal MMs may be multicentricity [12].

After an accurate determination of these fields and removal of the mucosa within this field, the clinician should ascertain whether the tumor has invaded the cartilage or bony structure. If the bony structure of the base of the nose is affected, then controllable resection is required. If an attempt is made to drill the lesion above the bone using a diamond-pointed drill, recurrence is unavoidable because the melanotic cells will invade the deeper bony structure at the microscopic level.

According to most reported series and reviews, there was no statistical difference in survival between patients receiving surgery alone and those receiving surgery and radiotherapy [2]. Many authors have recommended aggressive local therapy with adjuvant or salvage radiotherapy for patients with sinonasal mucosal melanoma, even in the absence of a survival benefit because postoperative adjuvant radiotherapy provides local control in patients [13, 14].

Chen and colleagues reported that surgery is the first choice, and that postoperative radiotherapy yields better outcomes. Another study reported that absolute local control by radiotherapy alone achieved success in 61% of cases [15, 16].

Melanoma is a relatively chemo-resistant tumor. Chemotherapy can be used for palliative purposes in patients with advanced stage disease [17]. Nakaya and colleagues stated that negative surgical margins were not predictive of a better prognosis [9]. However, we believe that negative surgical margins and clearing foci such as mucosal maculation areas are important criteria for treatment success. The precise etiopathogenesis is unknown, with one study suggesting that tobacco use, and formaldehyde exposure may play a role [11]. Smoking or alcohol abuse was present in none of our patients, and they reported no history of major drug exposure.

The first step in the diagnosis of suspect lesions. MMs are usually dark black in color with a view, although the appearance and the color of the lesion may vary according to the contents melanosis. Histopathology and immunohistochemical analysis are

needed for a definitive diagnosis. The differential diagnosis of nasal melanoma includes olfactory neuroblastoma, lymphoma, plasmacytoma, undifferentiated carcinoma, rhabdomyosarcoma, malignant fibrous histiocytoma, leiomyosarcoma, malignant fibrous histiocytoma, and neurogenic sarcoma [18-21].

On the other hand, some recent studies have reported that MRI is a useful method for the diagnosis of melanotic melanomas located in the nasal region. Some authors have reported that MMs of the sinonasal cavity show characteristic MR signal intensity, which is mainly attributable to the degree and the distribution of melanin pigmentation and partly attributable to hemorrhage within the mass [19]. It has also been reported that high signal intensity within the lesion on T1-weighted images suggests the presence of melanin [20].

Mucosal MM in the head and neck has a poor prognosis. Despite advances in surgical techniques and methods of adjuvant therapy, the 5-year survival rate of patients with nasal melanoma is very low [12].

Conclusion

The primary malignant melanoma of the nose is an extremely rare entity and it must be differentiated from other tumours of the nose and paranasal sinuses. Early diagnosis and surgical treatment of the melanoma of the nose offer the only possible hope of survival and therefore, attention must be paid to the minor nasal symptoms at the earliest.

References

1. Jayaraj, S. M., Hern, J. D., Mochloulis, G., & Porter, G. C. (1997). Malignant melanoma arising in the frontal sinuses. *Journal of Laryngology and Otology*, 111(4), 376–378.
2. Chang, A. E., Karnell, L. H., & Menck, H. R. (1998). The national cancer data base report on cutaneous and noncutaneous melanoma: A summary of 84,836 cases from the past decade. *Cancer*, 83(8), 1664–1678.
3. Khademi, B., Bahrani-fard, H., & Nasrollahi, H. (2011). Primary mucosal melanoma of the sinonasal tract: Report of 18 patients and analysis of 1077 patients in the literature. *Brazilian Journal of Otorhinolaryngology*, 77(1), 58–64.
4. Mori, W. (1973). Geographic pathology of malignant melanoma in Japan. In V. J. McGovern & P. Russell (Eds.), *Pigment Cell Mechanism in Pigmentation* (Vol. 1, pp. 246–254). Karger.
5. Mills, S. E., & Fechner, R. E. (1999). The nose, paranasal sinuses, and nasopharynx. In S. S. Sternberg (Ed.), *Diagnostic Surgical Pathology* (pp. 903–904). Lippincott Williams & Wilkins.
6. Billings, K. R., Wang, M. B., Sercarz, J. A., & Fu, Y. S. (1995). Clinical and pathologic distinction between primary and metastatic mucosal melanoma of the head and neck. *Otolaryngology–Head and Neck Surgery*, 112(6), 700–706.
7. Temam, S., Mamelle, G., Marandas, P., Wibault, P., Avril, M. F., Janot, F., Julieron, M., Schwaab, G., & Lubinski, B. (2005). Postoperative radiotherapy for primary mucosal melanoma of the head and neck. *Cancer*, 103(2), 313–319.
8. Peng, R. Q., Wu, G. H., Chen, W. K., Ding, Y., Ma, J., Zhang, N. H., & Zhang, X. S. (2006). Clinical characteristics and prognosis of primary nasal mucosal melanoma: A report of 44 cases. *Ai Zheng*, 25, 1284–1286.

9. Nakaya, M., Mochiki, M., Takeuchi, S., Yuge, T., Nakao, K., Nakamura, N., & Sugawara, M. (2004). Malignant melanoma of nasal cavity: Report of 16 Japanese patients. *Auris Nasus Larynx*, 31(3), 233–237.
10. Manolidis, S., & Donald, P. J. (1997). Malignant mucosal melanoma of the head and neck: Review of the literature and report of 14 patients. *Cancer*, 80(8), 1373–1386.
11. Uysal, İ. Ö., Misir, M., Polat, K., Altuntaş, E. E., Atalar, M. H., Tuncer, E., & Müderris, S. (2012). Primary malignant melanoma of the nasal cavity. *Journal of Craniofacial Surgery*, 23(1), 2–5.
12. Rinaldo, A., Shaha, A. R., Patel, S. G., & Ferlito, A. (2001). Primary mucosal melanoma of the nasal cavity and paranasal sinuses. *Acta Oto-Laryngologica*, 121(8), 979–982.
13. Mendenhall, W. M., Amdur, R. J., Hinerman, R. W., Werning, J. W., Villaret, D. B., & Mendenhall, N. P. (2005). Head and neck mucosal melanoma. *American Journal of Clinical Oncology*, 28(6), 626–630.
14. Lund, V. J., Howard, D. J., Harding, L., & Wei, W. I. (1999). Management options and survival in malignant melanoma of the sinonasal mucosa. *Laryngoscope*, 109(2), 208–211.
15. Chen, M., Lin, Z., & Tang, X. (1995). Malignant melanoma of nasal cavity: Report of 24 cases. *Chinese Journal of Otolaryngology*, 30(4), 246–247.
16. Gilligan, D., & Slevin, N. J. (1991). Radical radiotherapy for 28 cases of mucosal melanoma in the nasal cavity and sinuses. *British Journal of Radiology*, 64(766), 1147–1150.
17. Soengas, M. S., & Lowe, S. W. (2003). Apoptosis and melanoma chemoresistance. *Oncogene*, 22(20), 3138–3151.
18. Brandwein, M. S., Rothstein, A., Lawson, W., Bodian, C., & Urken, M. L. (1997). Sinonasal melanoma: A clinicopathologic study of 25 cases and literature meta-analysis. *Archives of Otolaryngology–Head & Neck Surgery*, 123(3), 290–296.
19. Kim, S. S., Han, M. H., Kim, J. E., Lee, C. H., Chung, H. W., Lee, J. S., & Chang, K. H. (2000). Malignant melanoma of the sinonasal cavity: Explanation of magnetic resonance signal intensities with histopathologic characteristics. *American Journal of Otolaryngology*, 21(6), 366–378.
20. Yousem, D. M., Li, C., Montone, K. T., Montgomery, L., Loevner, L. A., Rao, V., Chung, T. S., Kimura, Y., Hayden, R. E., & Weinstein, G. S. (1996). Primary malignant melanoma of the sinonasal cavity: MR imaging evaluation. *Radiographics*, 16(5), 1101–1110.
21. Mills, S. E., & Fechner, R. E. (1999). The nose, paranasal sinuses, and nasopharynx. In S. S. Sternberg (Ed.), *Diagnostic Surgical Pathology* (pp. 903–904). Lippincott Williams & Wilkins.