

## A Case of an Esophageal Complication

Inês Araújo Oliveira<sup>1\*</sup>, Filipa Lima Coelho<sup>2</sup> & Rosa Lima<sup>3</sup>

<sup>1</sup>Department of Pediatrics, Centro Materno Infantil do Norte, Centro Hospitalar e Universitário de Santo António, Porto, Portugal

<sup>2</sup>Department of Radiology, Centro Hospitalar e Universitário de Santo António, Porto, Portugal

<sup>3</sup>Department of Pediatric Gastroenterology, Centro Materno Infantil do Norte, Centro Hospitalar e Universitário de Santo António, Porto, Portugal

**\*Corresponding author:** Dr. Inês Araújo Oliveira, Department of Pediatrics, Centro Materno Infantil do Norte, Centro Hospitalar e Universitário de Santo António, Porto, Portugal. Tel: 916244984

**Submitted:** 31 May 2024    **Accepted:** 07 June 2024    **Published:** 14 June 2024

**doi** <https://doi.org/10.63620/MKJCBA.2024.1027>

**Citation:** Oliveira, I. A., Coelho, F. L., & Lima, R. (2024). A Case of An Esophageal Complication. *J of Clin Bio Med Adv*, 3(3), 01-02.

### Abstract

Epidermolysis bullosa (EB) is a group of inherited disorders characterized by blistering of the skin as a result of minor trauma. Diagnosis is based on clinical symptomatology, histopathology, and genetic studies. Major types of EB previously include epidermolysis bullosa simplex, hemidesmosomal epidermolysis bullosa, junctional epidermolysis bullosa, and dystrophic epidermolysis bullosa (EBD), based on the level of tissue separation within the cutaneous basement membrane zone. [1], [2] We report an adolescent with EBD with an esophageal complication.

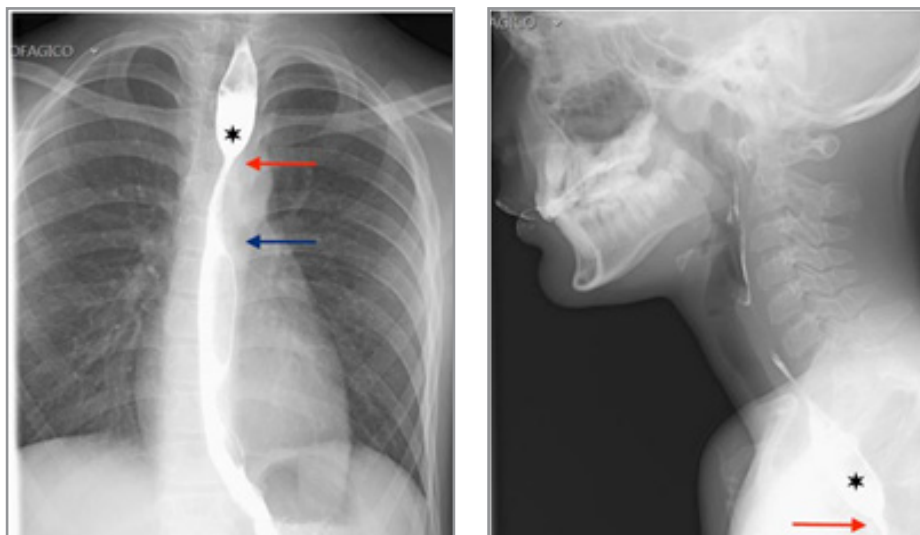
**Keywords:** Epidermolysis, Barium Esophagogram, Gastrointestinal Complications

### Case Presentation

A male adolescent was diagnosed with EBD during the neonatal period, which was later confirmed through a skin biopsy. He was born to non-consanguineous parents and there was no significant prenatal or family history of the condition. Since the beginning, he has been under the care of a multidisciplinary medical team.

As the disease has progressed, the skin involvement has become more extensive, manifesting with blisters, crusts, erosions, atrophic scars, milia cysts, onychodystrophy, and pseudo syndactyly affecting both hands and feet. These symptoms have led to muscle contractures, resulting in significant functional and motor impairment. Over the years, episodes of infection of the described lesions were recorded and successfully treated with antibiotic therapy.

At 7 years old, he began to exhibit symptoms of dysphagia and food impaction. Concomitantly, he presents ulcerative and scarring lesions in the oropharynx that also contribute to dysphagia, especially for solids. As the condition continued to worsen, an initial investigation was carried out using a barium esophagogram, revealing a narrowed segment of the esophagus starting approximately 17 cm from the dental arch (red arrow). This segment had a minimum estimated diameter of about 3 mm at its proximal end and extended longitudinally for approximately 4 cm (blue arrow). These findings are compatible with a stenotic esophageal segment, which conditions upstream esophageal stasis and impairs the movement of contrast during the exam (star). (Figures 1 and 2) In this context, endoscopic dilation was performed. The recurrence of the described esophageal complications required regular endoscopic dilations. This provided the patient with relief from dysphagia, thereby contributing to the improvement of their nutritional status.



**Figures 1 and 2:** In the barium esophagogram, a stenotic esophageal segment is observed, where the proximal extremity (red arrow) begins at 17 cm from the dental arch, with an estimated longitudinal extension of 4 cm to the distal end (blue arrow). It causes the upstream esophageal stasis of the contrast product (star).

### Discussion/Conclusion

EBD is rare, with an estimated prevalence at birth is 2–6 per million births out of an overall EB prevalence of 8–10 per million births [1]. It is characterized by non-inflammatory bullous lesions which can involve the mucous membranes. EBD is characterized by multiple organ involvement and severe complications starting in the first years of life [1, 2]. The different types of EBD include dominant dystrophic which has onset at birth or early infancy, blistering predominates on hands, elbows, knee, and lower legs, and milia with scarring is present [2]. Nail dystrophy is present in 80 percent. The recessive form has widespread blistering, scarring, milia deformities like pseudo syndactyly or joint contracture, and severe mucosal and nail involvement [1]. Esophageal webs or strictures result from bullous lesions and tend to relapse and can be found in about a third of the patients with the recessive dystrophic type of this disease. The esophageal involvement causes painful dysphagia followed by malnutrition and leads to the deterioration of skin lesions in these patients [3, 4].

Current treatment for epidermolysis bullosa consists of supportive care for skin and other organ systems. It entails a combination of wound management, infection support for chronic wounds, surgical management as needed, nutritional support, and prevention of complications [1, 2]. The initial, most effective, and safe treatment of esophageal stricture is balloon dilation, which can be carried out under fluoroscopic or endoscopic guidance. The intervention may be repeated, as the balloon dilation is well tolerated and can be done frequently. Early recognition of dysphagia in a patient with RDEB can improve the quality of life of the

patient. Prognosis varies considerably and is based on both EB subtype and the overall health of the patient [3-5].

### References

1. Marchili, M. R., Spina, G., Roversi, M., Mascolo, C., Pentimalli, E., Corbeddu, M., ... & Villani, A. (2022). Epidermolysis Bullosa in children: the central role of the pediatrician. *Orphanet journal of rare diseases*, 17(1), 147. <https://doi.org/10.1186/s13023-022-02369-w>
2. Has, C., Bauer, J. W., Bodemer, C., Bolling, M. C., Bruckner-Tuderman, L., Diem, A., ... & Mellerio, J. E. (2020). Consensus reclassification of inherited epidermolysis bullosa and other disorders with skin fragility. *British Journal of Dermatology*, 183(4), 614-627. <https://doi.org/10.1111/bjd.18921>
3. Xu, Z., Huang, T., Pan, M., Huang, Y., & Jiang, Y. (2022). Case report: Recessive dystrophic epidermolysis bullosa with severe esophageal stenosis: A case report and literature review. *British Journal of Biomedical Science*, 79(1), 10200. <https://doi.org/10.1080/09674845.2021.2007653>
4. Zhou, W. Z., Xia, J. G., Yang, Z. Q., Zhou, C. G., Zhao, L. B., Liu, S., & Shi, H. B. (2018). Balloon dilation of epidermolysis bullosa-related esophageal strictures: A report of two cases. *Gastrointestinal Intervention*, 7(3), 172-175. <https://doi.org/10.18528/ijgii.2018.07.004>
5. Gollu, G., Ergun, E., Ates, U., Can, O. S., & Dindar, H. (2017). Balloon dilatation in esophageal strictures in epidermolysis bullosa and the role of anesthesia. *Diseases of the Esophagus*, 30(1), 1–6. <https://doi.org/10.1093/dote/dow021>