

Munchausen Syndrome by Proxy: A Report from Russia

Sergei V Jargin

Associate Professor of the Department of Pathology, Peoples' Friendship University of Russia, 117198 Moscow, Russia

***Corresponding author:** Sergei V Jargin, Associate Professor of the Department of pathology, Peoples' Friendship University of Russia, 117198 Moscow, Russia. Tel: +7 495 9516788

Submitted: 22 January 2024 **Accepted:** 29 January 2024 **Published:** 31 January 2024

Citation: Sergei V Jargin (2024) Munchausen Syndrome by Proxy: A Report from Russia. *J of Gyne Obste & Mother Health* 2(1), 01-06.

Abstract

A case of child maltreatment compatible with Munchausen syndrome by proxy (MBP) or medical child abuse is presented. Perpetrators in such cases are typically mothers of victims, often with a history of emotional, physical abuse or abandonment in their childhood. The perpetrators were also reported to be high users of obstetrics and gynecology services. However, the chief purpose of this report and mini-review was not so much the presentation of MBP, which is a well-known condition, but the depiction of the current and historical background in Russia. Family violence and child abuse has been rarely discussed in the Russian literature. This topic is interconnected with certain features of the healthcare, namely paternalism, authoritative management style, occasional disregard for the principles of informed consent and professional autonomy, contributing to the use of invasive procedures without sufficient indications. This is a fruitful soil for iatrogeny and medical abuse of different kind including MBP. Examples from gynecology and other fields of medicine are discussed.

Keywords: Munchausen Syndrome by Proxy, Child Abuse, Family Violence, Breast Cancer, Endocervical Ectopy

Introduction

Child abuse has been rarely discussed in the Russian literature. Several booklets were published in the period 1990-2016 (referenced) but today the topic is largely avoided [1]. During medical education and postgraduate training in pathology, the author hardly ever heard about child abuse. In the literature, the accent is often on visible injuries: bruises, burns and fractures. Of note, child abuse can continue for years with cerebral concussions, burns of oral/esophageal mucosa and intoxications without externally visible injuries, exemplified by the case report below. According to some analyses, the prevalence of family violence in Russia during last decades has been 45-70 times higher than, for example, in England and France [2]. According to a recent report, about 40% of all serious violent crimes in Russia are committed within families; 14% of children are subjected to physical abuse, 2 million are regularly beaten by parents while 10% of them lose their lives as a result [3]. According to other sources, 40% of children are beaten in families [4]; 31% experience sexual abuse and 41% suffer cruel punishments [5]. It was reported in 2016 that the General Prosecutor's Office records about 2 million children beaten by their parents yearly, whereas 10% of the cases end in death, of which about 2 thousand by suicide [6]. Yet in 2017 Vladimir Putin has signed into law an amendment that decriminalizes some forms of domestic violence [7]. Apropos, physical abuse was described in his biographies [8-10]. It has been hypothesized that Putin is re-enacting his own and his

family's traumas in conditions of an intergenerational chain of violence [10, 11]. There is a "danger of blundering into a nuclear war" thanks to that case of child maltreatment [11].

The self-referral rate of victims of domestic violence in Russia is low; among reasons are distrust of authorities, fears of revenge from perpetrators or of humiliations and breach of secrecy in the course of investigation. In case of disclosure, not only abusers but also victims are sometimes blamed [12]. Detection of family violence often depends on victims. It is easier to denounce a socially unprotected abuser e.g. an alcoholic. Otherwise, various defenses can be applied by perpetrators: denial of facts, allegations of slander and/or mental abnormality in the victim, threats and intimidation, appeals to preserve honor of the family or nation. The intergenerational transmission of violence is evident in many families [5]. The attitude of some professionals and a part of the population is tolerant [6, 13]. Authorities, teachers and neighbors did not react to some known cases of child maltreatment. There is neither official standpoint nor agreed policies [2, 14]. Investigations are started mainly on official request. Numerous children continue living in conditions of abuse potentially harmful for their physical and mental health [5]. The predominant way to solve problems of child abuse has been a placement in an orphanage [6]. The institutionalization means that not the abuser but the victim is removed from the familiar environment, suffers deprivation and discomfort [12].

Medical child abuse or Munchausen syndrome by proxy (MBP), also known as factitious disorder imposed on another, is a variant of child maltreatment whereas the victim is subjected to unnecessary or potentially harmful medical treatments. The offenders are predominantly mothers of victims, often with emotional, physical abuse or abandonment in their childhood and/or abusive relationships [15-17]. The perpetrator goes “doctor shopping” with her child, welcoming multiple tests and procedures if even painful and unnecessary. Repeated hospitalizations are common [18, 19]. It was estimated that 10% of MBP victims die at the hands of offenders [18]. According to another review, mortality rates in victims of fabricated illnesses range from 6 to 9%, but challenges in detection suggest that actual rate is higher [15]. Perpetrators of MBP exaggerate, falsify, simulate and/or induce illness in children to convince medics that a therapy is needed. Personality disorders, depression and factitious disorder imposed on self are relatively frequent among MBP perpetrators [15, 19, 20]. The condition is difficult to recognize because abuse is often not evident. Psychological effects may be chronic and long-standing but not immediately recognizable. The perpetrators (mothers) are traditionally held above suspicion [18]. As in the case report presented below, offenders may suffer psychological dissociation, alternating their behavior from maternal affection and care to overt sadism, sometimes talking about their roles in terms of “other self”. At the same time, high deceptive abilities of offenders, enabling them to covertly commit child abuse, have been noticed [18]. Unwilling to accept responsibility for their actions, abusive parents blame others, especially their children [17]. Finally, perpetrators of MBP were reported to be high users of obstetrics and gynecology services; for example, the mother of the abuse victim discussed below experienced several abortions, apparently, as a result of contraception sabotage [19]. The latter has been not infrequent in the former Soviet Union, hence the worldwide highest abortion rates [21].

Case Report

A 2-years-old Sergei (S.), playing in a yard of a suburb house, was hit by a stone in his left temporal area. The stone was thrown by an older child; the stone-throwing went on for some minutes; the mother sat in shadow and watched. An immediate medical help was not sought; the boy stayed in bed for several days. Transitory neurological symptoms were observed: strabismus, blepharoptosis, dysphagia with aspiration of food. Moderate symptoms compatible with Klüver-Bucy or frontal lobe syndrome were observed, which has been reported after head trauma including minor one [22-25]. After the accident, the child was often brought to medical institutions mainly by his grandmother (mother's aunt) but the head trauma was concealed from doctors. Sergei's mother, an orphan, had been adopted by her childless aunt, who physically maltreated her stepdaughter during the latter's childhood.

When S. was three years old, his parents were divorcing; and he was sent with a nanny to a suburb. They spent there also two subsequent summers, having almost no contact with other children. The boy sat on a sofa or bench days on end and was often locked up alone in the room, which did not contribute to his physical development and communication skills. There were repeated burns of the oral mucosa, esophagus and genital area by hot porridge or soup; consequences are felt at the advancing age. The nanny gave alcohol to the child. At the age of 6-7 years,

S. underwent adenoidectomy and tonsillectomy with insufficient local anesthesia and questionable indications. Later it has become clear that he has allergic rhinitis; but symptoms were regularly exaggerated by the grandmother with a refrain: “Something must be done about it!” After years-long antibacterial and decongestant therapy, adenoidectomy was performed. As for the tonsillectomy, relapsing tonsillitis and pharyngitis was apparently caused by burns: the hungry child was given nearly boiling hot porridge, soup or tea. A proof thereof is that pharyngitis discontinued when the child grew older and stopped swallowing the hot stuff. Burns are common in child abuse but not always easy to evaluate [17]. Symptoms of an esophageal stricture have become increasingly disturbing after the age of 50 years, up to difficulties in swallowing solid food. Moreover, the grandmother was insisting on eye surgery because of above-mentioned strabismus. The child was repeatedly brought to an ophthalmological institution, the surgery was considered; but doctors adequately assessed the findings and the surgery was denied. Strabismus spontaneously disappeared before the school age.

When S. was 7 years old, his mother married a 13 years younger individual of non-Russian ethnic background, who wanted to live in Moscow. The following risk factors of the child maltreatment were present: poor social support, presence of a younger child, family history of abuse - the perpetrator had been beaten by his father [26]. The abuse was administered mainly by slapping in the face and head. The beating often occurred under the pretext of punishment, but sometimes without any pretext. Episodes of violence went along with intimidation by gestures. The physical abuse sometimes occurred before spectators: the mother, relatives or friends. Occasionally, the mother participated in beating, which is in agreement with reports that mothers abuse their children more often when their partners are not fathers of the victims [27]. In several cases, the child abuse was associated with sexual activities of the caregivers; the stepfather got up from the marital bed and whipped the child with a belt without putting on his pants. Rarely, the young husband applied violence also to his wife. When the boy was 12-13 years old, a visiting alcohol-consuming family friend climbed into the child's bed; fortunately, the boy was able to defend himself. It should be commented that the victim was “trained” not to make noise when abused. Nonetheless, the scene was loud enough to be heard through the small apartment; the stepfather laughed about it in the morning. Undoubtedly, the scenes of abuse were heard by neighbors in the thin-walled apartment block; but nobody intervened. Apart from irregular nourishment, an example of neglect was a deprivation of training clothes during early school years. The boy was sent to gymnastics lessons inappropriately dressed, so that his genitals were visible during exercises, in spite of written reprimands from the teacher and the child's repeated begging. This was one of the immediate causes of the bullying at school as well as of delayed physical development: the teacher let the boy sitting on a bench during gymnastics lessons.

As mentioned above, superficial scald burns of the genital area occurred to S. in early childhood. Immediate medical help was not sought. Subsequently, the fact of the burn was concealed from medics. When the healing ensued, the child started scratching the area. Seeing that, the mother pinched his genitals with considerable force. Her partner did the same once at least. In the meantime, symptoms of balanoposthitis were repeatedly

noticed. The child was brought to the surgeon who diagnosed phimosis and performed repeated manual retraction of the foreskin. Along with the pubertal development, the foreskin became completely and permanently retracted; at an older age the penis binding with soft cloth has become necessary because of the skin vulnerability. Finally, it should be mentioned that the caregivers not only induced abnormal behaviors by maltreatment but also spread information about the child's supposed abnormality as a justification for the "strict upbringing" and corporal punishments. Apart from other medical specialists, psychiatrists and neurologists were visited. At the age of around 7 years S. received potassium bromide and some tranquilizers, thereafter communicating with same-aged peers, which probably contributed to inadequate behavior and bullying. It is known that abuse at home places a child at risk for inadequate peer relationships [28]. Children experiencing maltreatment often develop maladaptive conduct [29]. Finally, child abuse impeded the school learning, which agrees with the literature [30]. The case report should end on a positive note. After 2 years of military service and altogether ~3 years of work in the North of Russia, the final outcome has been largely acceptable; although insufficient adaptation to the society and shame accompanied S. through his life. Fortunately, many survivors of child abuse learn not to dwell in the past imbued with helplessness and pain [17].

Discussion

The special feature of the case presented above is that there were two perpetrators, the grandmother and mother, who acted by mutual consent before the latter moved to a separate apartment with her new family when S. was 8 years old. The following arguments in favor of malicious intent and hence the medical child abuse or MBP should be pointed out. Bringing the child repeatedly to doctors and exaggerating symptoms, both perpetrators were aware of possible complications as they had negative experiences with the Soviet healthcare mainly in the field of gynecology. The mother complained about harsh and painful gynecological manipulations and abortions. The grandmother had an enlarging ostrich-egg-sized hernia in a hysterectomy scar probably as a result of poor procedural quality. Moreover, she was crippled by a Halsted mastectomy performed for T2 breast cancer (BC). The worldwide tendency towards a sparing BC management was not followed in Russia for decades. In the 1980s and decreasingly in the 1990s, the Halsted procedure with the removal of both Pectoralis muscles was a predominant method of BC management [31-34]; it was presented as the main treatment modality of BC in some textbooks and monographs published after the year 2000 [35-37]. The principle of informed consent was often disregarded. Patients with early cancers were subjected to mastectomies with resection of pectoral muscles without discussing the extent of operation and potential adverse effects. A surgery could be extended to a radical (Halsted) procedure if an intraoperative frozen section found an early (2 cm) BC [38]. The latter operation is known to be associated with complications; considering BC incidence, millions of women underwent it in the former Soviet Union. Even more radical methods were recommended and applied [39]. Old age was not regarded as contraindication to the radical surgery [40]. In view of complications, some experts recommended the modified radical mastectomy of Patey with resection of only the smaller pectoral muscle for T1-2 laterally located BCs [41-43]. Others advocated the Halsted procedure

[44]. The Patey operation is also associated with adverse effects; nonetheless, it has been broadly used in Russia in last decades. The article dated 2007 discussed the "gradual abandonment of the Halsted operation" [45]. In papers dated 2015-2022, the Patey operation was still mentioned as a routine procedure; but the preservation of both pectoral muscles was finally becoming a standard [46-48]. Today, the recommendations are adjusted to international patterns.

Factors contributing to the persistence of suboptimal practices applied in Russia include a partial isolation from the international scientific community, shortages of medical education and unavailability of many internationally used handbooks [49-51]. Some translations of foreign manuals are of low quality. Justifications of surgical hyper-radicalism could be heard in private conversations among medics, for example: "The hopelessly ill are dangerous" i.e. may commit reckless acts undesirable by the totalitarian state [52]. For example, glioblastoma patients were routinely operated on, which was regarded by some staff to be generally useless, just forcing many patients to spend the rest of their lives in bed; details are in [53]. The training of medical personnel has been another motive. The lacking professional autonomy has further contributed to the persistence of suboptimal and outdated methods in the healthcare [54, 55]. In conditions of paternalism, misinformation and persuasion of patients with de facto compulsory treatments are deemed permissible [56]. Suboptimal practices have been used as per instructions by healthcare authorities and leading experts' publications. The following has been discussed previously: overuse of gastrectomy for peptic ulcers, of thoracic surgery for tuberculosis, bronchial asthma and other respiratory diseases, overtreatment of radiation-related lesions, spleno-renal anastomosis in diabetes, excessive and compulsory treatments of alcoholics [52, 54, 57]. Furthermore, electro- and thermocoagulation of cervical ectopy, regardless of the presence of epithelial dysplasia, has been routinely applied in the former SU. It should be commented that cervical ectopy or ectropion is called pseudo-erosion (colloquially erosion) in Russia, while the term ectropion is mainly used for the cervix eversion after delivery. Cervical ectopies were found at mass examinations and treated by cauterization [58, 59]. This is at variance with the evidence not supporting the hypothesis that the cauterization protects against cervical cancer [60]. The ablative methods left the endocervix and deeply located glands intact. At the same time, Pap smears have been performed infrequently and not up to the quality standards, cervical cancer being diagnosed relatively late [61, 62]. Ablative methods are advertized (Fig. 1a, b) and recommended by some contemporary Russian-language literature. For example, relapsing endocervical ectopy without epithelial dysplasia is presented as an indication for cryotherapy although this method impedes histological examination [63]. Other experts recommend laser, cryo- or electrocoagulation for acquired endocervical ectopy [64]. For leukoplakia without cell atypia a loop excision is recommended [65]. Some medical practices possess only one device for ablative therapy and apply it occasionally with questionable indications. More details and references are in [61, 63, 66]. Thanks to the Internet, foreign literature is largely available in Russia these days, guidelines being adjusted to international standards. However, some published instructions have remained without due commentaries, so that a comeback to suboptimal practices is not excluded.

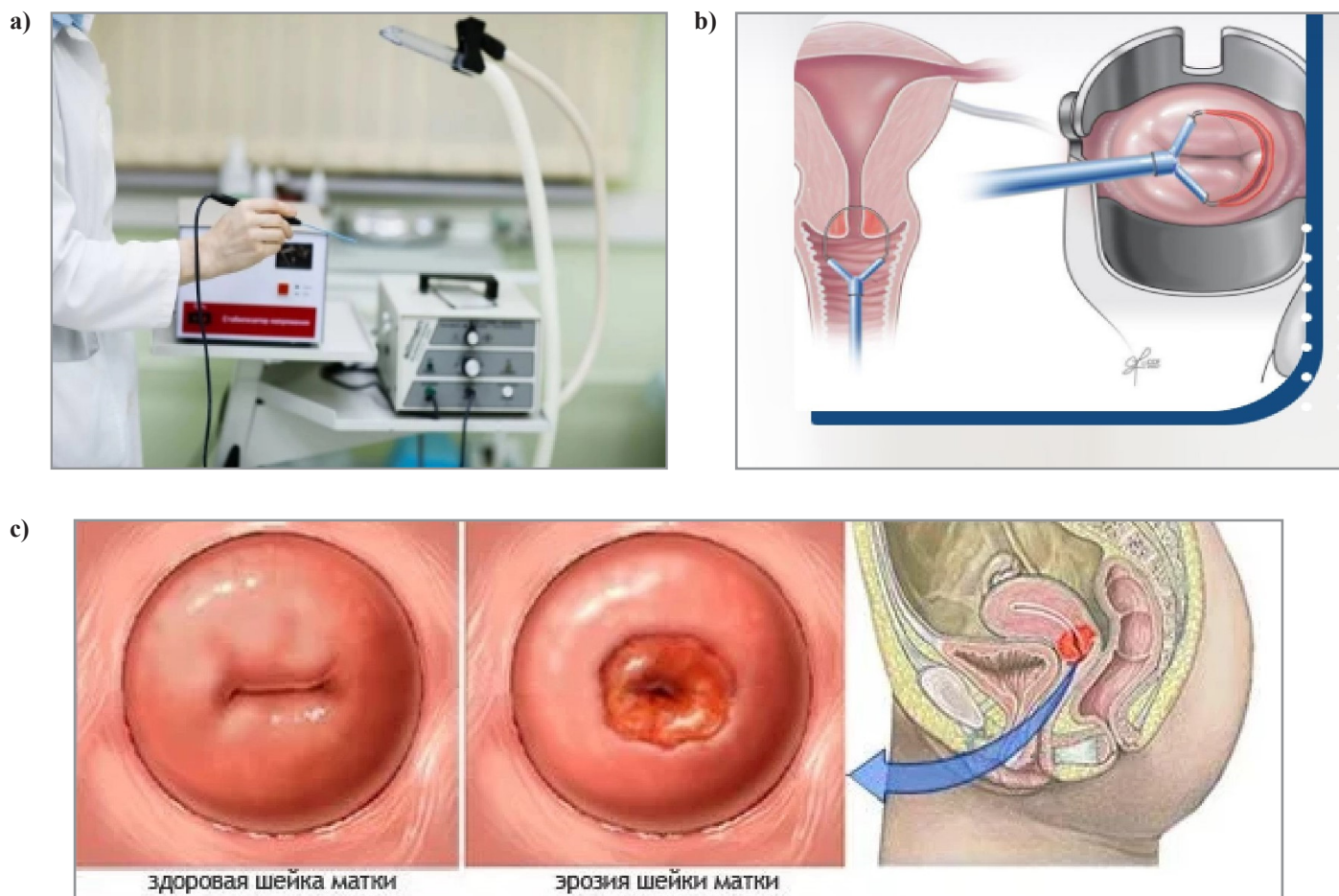


Figure 1a, b, c: Online advertising of ablative treatments for erosion or cervical ectopy.

Conclusion

The aim of this case report and mini-review was not so much the description of MBP, which is a well-known entity, but emphasizing of the widespread family violence and child abuse in Russia, largely tolerated by the society and authorities. This topic is interconnected with some features of Russian healthcare, namely paternalism, authoritative management style, occasional disregard for the principles of informed consent, professional autonomy and scientific polemics, contributing to the use of invasive procedures without sufficient indications. The field of topics related to child abuse is insufficiently known by many doctors; there are neither agreed policies nor clear instructions how to report suspicions. Considering shortcomings of medical practice, research and education, a simple increase in funding is unlikely to be a solution. Measures for improvement of the public health in Russia must include participation of authorized foreign advisers. Unfortunately, current international tensions are not contributing to this development.

References

- Jargin SV (2023) Child abuse in Russia. *J Addiction Prevention* 11: 1-4.
- Besschetnova OV (2015) Problems of child abuse in a contemporary Russian family. Saratov University.
- Borisov SN, Volkova OA, Besschetnova OV, Dolya RY (2020) The domestic violence as factor of disorder of social and mental health. *Probl Sotsialnoi Gig Zdravookhranenni-iai Istor Med* 28: 68-73.
- Agafonova SV, Beschastnova OV, Dymova TV, Ryabichkina TV (2011) Prevention of child abuse. Astrakhan: Sorokin.
- Tinkova EL, Katilevskaia IuA (2016) Special features of victim behavior of children and adolescents subjected to cruel treatment. Stavropol: Pedagogical Institute.
- Alekseeva LS (2016) Child abuse: its consequences and prevention. Moscow: Sentiabr.
- Walker S (2017) Putin approves legal change that decriminalises some domestic violence. *The Guardian*.
- Baker P, Glasser S (2005) Kremlin rising. Vladimir Putin's Russia and the End of Revolution. Washington DC: Potomac Books.
- Ressler N (2017) Putin according to Freud: hidden and obvious. Moscow: Algorithm.
- Ihanus J (2022) Putin: Ukraine, and fratricide. *Clio's Psyche* 28: 300-311.
- Elovitz PH (2022) Mother Russia's savior, traumatic reenactment, and the atrocities of war. *Clio's Psyche* 28: 320-325.
- Alekseeva LS (2012) Competence improvement of a social educator: working methods with at-risk families. Moscow: Sovremennoe obrazovanie.
- Safonova TIa, Tsymbal EI, Zhuravleva TM, Kurasova NV, Klein TP, et al. (2001) Child abuse: Helping abused children and their parents. Moscow: Ozon.
- Besschetnova OV (2003) Social work with children - victims of abuse in families. Balashov: Nikolaev.

15. Hoffman JS, Koocher GP (2020) Medical child abuse hidden in pediatric settings: detection and intervention. *J Clin Psychol Med Settings* 27: 753-765.
16. Egge MK (2023) Medical child abuse: a review by subspecialty. *Adv Pediatr* 70: 59-80.
17. Crosson-Tower C (2002) Understanding child abuse and neglect. Boston: Allyn and Bacon.
18. Artingstall K (1999) Practical aspects of Munchausen by proxy and Munchausen syndrome investigation. Boca Raton: CRC Press.
19. Yates G, Bass C (2017) The perpetrators of medical child abuse (Munchausen Syndrome by Proxy) - a systematic review of 796 cases. *Child Abuse Negl* 72: 45-53.
20. Abdurrachid N, Gama Marques J (2022) Munchausen syndrome by proxy (MSBP): a review regarding perpetrators of factitious disorder imposed on another (FDIA). *CNS Spectr* 27: 16-26.
21. Popov AA, Visser AP, Ketting E (1993) Contraceptive knowledge, attitudes, and practice in Russia during the 1980s. *Stud Fam Plann* 24: 227-235.
22. Jargin SV (2020) Klüver-Bucy syndrome after a head trauma in conditions of child abuse and neglect. *Psychiatr Danub* 32: 434-435.
23. Asensio JA (2003) Klüver-Bucy syndrome as a result of minor head trauma. *South Med J* 96: 726.
24. Olson DA (2003) Klüver-Bucy syndrome as a result of minor head trauma. *South Med J* 96: 323.
25. Salim A, Kim KA, Kimbrell BJ, Petrone P, Roldán G, et al. (2003) Klüver-Bucy syndrome as a result of minor head trauma. *South Med J* 95: 929-931.
26. Hindley N, Ramchandani PG, Jones DP (2006) Risk factors for recurrence of maltreatment: a systematic review. *Arch Dis Child* 91: 744-752.
27. Alexandre GC, Nadanovsky P, Moraes CL, Reichenheim M (2010) The presence of a stepfather and child physical abuse, as reported by a sample of Brazilian mothers in Rio de Janeiro. *Child Abuse Negl* 34: 959-966.
28. Lewis M (1989) What can child development tell us about child abuse? In: Browne K, Davies C, Stratton P (eds) Early prediction and prevention of child abuse. Chichester: Wiley 3-13.
29. Garbarino J, Kostelny K, Grady J (1995) Children in dangerous environments: Child maltreatment in the context of community violence. In: Cicchetti D, Toth SL (eds) Child abuse, child development, and social policy. Norwood: Ablex 167-188.
30. Cicchetti D, Toth SL, Henessy K (1995) Child maltreatment and school adaptation: problems and promises. In: Cicchetti D, Toth SL (eds) Child abuse, child development, and social policy. Norwood: Ablex 301-316.
31. Pereslegin IA, Nikitina TP (1990) Surgical, radiation and drug treatment of breast cancer. *Med Radiol (Mosk)* 35: 39-44.
32. Levin AO, Miasnikova MO (1992) Saving the musculus pectoralis minor in radical mastectomy. *Vopr Onkol* 38: 80-84.
33. Irov NN (1989) Evaluation of various surgical methods in the treatment of breast cancer. *Khirurgiia (Mosk)* 17-19.
34. Letiagin VP (1992) The treatment of primary breast cancer. The late results. *Ter Arkh* 64: 33-37.
35. Kazachenok VM, Baryash VV (2005) Breast diseases. Minsk: Belarusian Medical University.
36. Kovanov VV, Perelman MI (2001) Operations on the chest and thoracic cavity organs. In: Kovanov VV (ed) Operative surgery and topographic anatomy. Moscow: Meditsina 297-321.
37. Semiglazov VV, Topuzov EE (2009) Breast cancer. Moscow: Medpress-inform.
38. Demidov VP, Pak DD, Ostrovtshev LD (1990) Errors in the treatment of breast cancer. *Khirurgiia (Mosk)* 90-95.
39. Kholdin SA, Dymarskii LIU (1975) Extended radical operations in breast cancer. Leningrad: Meditsina.
40. Suspitsyn IuV, Letiagin VP, Ivanov VM, Orlova PN (1990) Treatment of breast cancer in middle-aged and elderly menopausal women. *Sov Med* 72-76.
41. Kuzin MI, Shkorob OS, Kulakova AM, Bukhteeva NF (1977) Indications for Patey's operation in breast cancer. *Khirurgiia (Mosk)* 19-23.
42. Kuzin MI, Shkorob OS, Kulakova AM, Zal'tsman IN, Zolotarevskii VB (1981) Diagnosis and treatment of nonpalpable breast tumors. *Vopr Onkol* 27: 3-10.
43. Bazhenova AP, Madich KK, Khakhanashvili GN, Sikharulidze AV (1987) Experience in performing the Patey-Dyson operation in cancer of the breast. *Khirurgiia (Mosk)* 37-42.
44. Datsenko VS, Abisheva AB (1977) Patey mastectomy in the combined treatment of breast cancer. *Vopr Onkol* 23: 48-53.
45. Khvastunov RA, Kireev AV, Nikolskiy IV, Suvorov VA (2007) Single-step mastectomy and laparoscopic ovariectomy in the treatment of breast cancer. *Journal of Modern Oncology* 9(3): 24-28.
46. Bektursynov SM, Bayduvaliev AM (2015) Treatment of breast cancer with the use preoperative radiotherapy. *International Journal of Applied and Fundamental Research* 80-83.
47. Yarema VI, Fatuev OE, Stepanyants NG, Safronova VV (2019) Immediate and remote results of surgical interventions on the breast. *Research'n Practical Medicine Journal (Issled Prakt Med)* 6: 110-119.
48. Bukkieva T, Pospelova M, Efimtsev A, Fionik O, Alekseeva T, et al. (2022) Functional network connectivity reveals the brain functional alterations in breast cancer survivors. *J Clin Med* 11: 617.
49. Murphy J, Jargin S (2017) International trends in health science librarianship part 20: Russia. *Health Info Libr J* 34: 92-94.
50. Senokosova EK (2019) Criminal incompetence and dishonesty in medicine. Moscow: Yurlitinform.
51. Jargin SV (2013) Some aspects of medical education in Russia. *Am J Med Stud* 1: 4-7.
52. Jargin SV (2022) Surgery without sufficient indications: an update from Russia. *J Surgery* 10: 1-9.
53. Jargin S (2024) Surgical procedures with questionable indications used in Russia. Preprints 2024010961. doi: 10.20944/preprints202401.0961.v1.
54. Jargin SV (2020) Misconduct in medical research and practice. New York: Nova Science Publishers. doi: 10.52305/GIEZ3244.
55. Danishevski K, McKee M, Balabanova D (2009) Variations in obstetric practice in Russia: a story of professional autonomy, isolation and limited evidence. *Int J Health Plann Manage* 24: 161-171.
56. Mikirtichan GL, Kaurova TV, Pestereva EV (2022) Introduction to bioethics. St. Petersburg: Pediatric Medical University.

57. Jargin SV (2023) Overtreatment of supposedly radiogenic cancer and precancerous lesions. *Cancer Screening and Prevention* 2: 270-272.
58. Lesiuk VS (1963) On the problem of treatment of erosion of the cervix uteri and endocervicitis by different methods of heat coagulation. *Akush Ginekol (Mosk)* 39: 83-86.
59. Bokhman IaV (1985) Prevention of cancer of uterine cervix and corpus. All-Union Symposium "Early diagnostics, treatment of pretumorous and tumorous diseases of the uterine cervix and dispensarization of the female population. Pskov, USSR. Leningrad 31-33.
60. Machado Junior LC, Dalmaso AS, Carvalho HB (2008) Evidence for benefits from treating cervical ectopy: literature review. *Sao Paulo Med J* 126: 132-139.
61. Jargin SV (2008) Perspectives of cervical cytology in Russia. *Am J Obstet Gynecol* 199: e10.
62. Syrjänen S, Shabalova IP, Petrovichev N, Kozachenko VP, Zakharova T, et al. (2002) Human papillomavirus testing and conventional pap smear cytology as optional screening tools of women at different risks for cervical cancer in the countries of the former Soviet Union. *J Low Genit Tract Dis* 6: 97-110.
63. Damirov MM (2023) Cryogenic method of treatment of cervical diseases. Moscow: Geotar-Media.
64. Gantsev ShH (2014) Diseases of the cervix. Moscow: Geotar-Media.
65. Kuznetsova IA, Grechkanov GO, Kachalina OV, Borovkova LV (2017) Diagnosis and treatment of cervical diseases. Modern possibilities, error analysis. Nizhny Novgorod Medical Academy.
66. Jargin SV (2016) Surgical procedures with questionable indications: A letter from Russia. *J Surgery* 4: 6.