

A Theoretical Approach for Diagnosing Corneal Ectasia Using Purkinje Image Geometry: An Accessible Method for Low-Cost and Early Detection

Mohsen Sharifzadeh, PhD*

Affiliate Professor at Brigham Young University

*Corresponding author: Mohsen Sharifzadeh, PhD, Affiliate Professor at Brigham Young University. Email: msh1344@byu.edu

Submitted: 09 December 2024 Accepted: 16 December 2024 Published: 23 December 2024

Citation: Sharifzadeh, M. (2024). A Theoretical Approach for Diagnosing Corneal Ectasia Using Purkinje Image Geometry: An Accessible Method for Low-Cost and Early Detection. *Sci Set J of Ophthalmology & Eye Care*, 3(4), 01-09.

Abstract

Purpose: To propose a theoretical method for diagnosing corneal ectasia, including keratoconus and related conditions, by analyzing Purkinje images, specifically the displacement and distortion of the first Purkinje image (P1). The method aims to provide a cost-effective, accessible diagnostic tool for early detection and monitoring.

Methods: The proposed method utilizes an algorithm that analyzes key metrics, including Euclidean distance, eccentricity, area, and perimeter, derived from Purkinje images. Data augmentation techniques are employed to create a diverse reference dataset simulating varying ectatic conditions. The method is adaptable to multiple platforms, such as attachments to existing fundus cameras or standalone devices and incorporates a composite scoring system to quantify ectasia severity.

Results: Simulated scenarios demonstrate that the method effectively identifies deviations in P1 metrics indicative of ectasia. Higher composite scores correspond to more severe cases, reflecting significant changes in eccentricity, perimeter, and displacement metrics. The robustness of the algorithm is supported by data augmentation, which enhances diagnostic reliability even in the absence of clinical data.

Conclusions: This method provides a promising approach for diagnosing corneal ectasia, offering a cost-effective and adaptable solution. Future integration of artificial intelligence and machine learning is expected to optimize the scoring system, automate the analysis process, and further improve diagnostic accuracy.

Translational Relevance: The proposed method bridges the gap between high-end diagnostic tools and accessible, low-cost solutions, particularly for underserved populations. It has the potential to revolutionize corneal ectasia diagnostics by enabling early detection and improving patient outcomes in diverse healthcare settings.

Keywords: Corneal Ectasia, Keratoconus, Purkinje Images, Data Augmentation, Non-Invasive Diagnostics, Ophthalmology, Low-Cost Diagnostics

Introduction

Corneal ectasia encompasses a group of progressive, non-inflammatory disorders characterized by structural instability and thinning of the cornea, leading to irregular astigmatism and visual impairment. Among these, keratoconus is one of the most studied conditions, marked by localized corneal thinning and cone-shaped deformation [1, 2]. However, corneal ectasia also

includes related conditions such as pellucid marginal degeneration and forme fruste keratoconus, which share overlapping clinical features [3]. Early detection of these conditions is crucial, as timely intervention can prevent severe visual deterioration and reduce the need for invasive procedures such as corneal transplantation [4]. Despite their importance, diagnosing ectatic conditions in their early stages remains challenging,

particularly in low-resource settings where access to advanced diagnostic tools is limited.

Current diagnostic techniques, such as corneal topography and tomography, offer detailed assessments but are often cost-prohibitive and require specialized equipment that may not be accessible in underserved areas [5]. While traditional tools like Placido discs provide a low-cost alternative, they lack the quantitative precision to detect subtle early-stage abnormalities [6]. Additionally, these methods often rely on cross-sectional evaluation, which may not capture the progressive nature of ectatic conditions without longitudinal follow-up.

To address these limitations, this study proposes a novel, theoretical method for detecting corneal ectasia by analyzing Purkinje images, mainly focusing on the displacement and distortion of the first Purkinje image (P1) [7, 8]. The method employs key geometric metrics, such as Euclidean distance, eccentricity, area, and perimeter, combined with a composite scoring system to quantify the severity of ectasia. The method establishes a robust reference dataset for diagnostic comparisons by leveraging data augmentation techniques, even without clinical data [9].

The method's adaptability to multiple platforms, including attachments for existing fundus cameras and standalone, low-cost devices, ensures its utility across diverse healthcare settings. Increasing the analysis resolution, such as using additional LEDs, could further enhance its ability to detect early-stage abnormalities. These features make it particularly suitable for low-resource environments, where affordable and accessible solutions are urgently needed [10, 11].

Integrating artificial intelligence (AI) and machine learning (ML) offers a promising avenue to refine this method. AI can optimize the scoring system, automate the analysis process, and improve diagnostic accuracy, enabling real-time interpretation of Purkinje images [12, 13]. By lowering the barrier to use, AI could also empower non-specialists to perform screenings, expanding access to early detection in underserved regions. These advancements would complement, rather than replace, high-end diagnostic tools, offering a scalable, practical alternative for widespread screening.

In summary, this method represents a significant advancement in ophthalmology, offering a cost-effective and accessible solution for diagnosing corneal ectasia. Addressing current limitations and incorporating future refinements, such as increased resolution and AI integration, this approach could establish a new standard for early detection and management of ectatic corneal disorders, particularly in underserved areas.

Materials and Methods

Overview of the Method

This study introduces a theoretical approach to diagnosing corneal ectasia, including keratoconus and related conditions, through

the geometric analysis of Purkinje images. The focus is on the first Purkinje image's displacement and distortion characteristics (P1), a key reflection from the anterior corneal surface [7, 8]. The method is designed to function either as an attachment to existing fundus cameras or as a stand-alone, low-cost diagnostic device, enhancing accessibility, particularly in low-resource settings where traditional diagnostic tools are unavailable [10, 11].

This approach's core is a robust database built through data augmentation, simulating a wide range of corneal shapes and ectasia severities. This augmented database provides a comprehensive reference for the diagnostic algorithm, enabling accurate comparisons between patient images and baseline metrics derived from both healthy and simulated ectatic corneas [9, 14]. By leveraging this framework, the method aims to offer an accessible, non-invasive screening solution for early detection and monitoring of corneal ectasia.

Optical Setup and Image Capture

The primary setup for capturing Purkinje images involves either an attachment to existing fundus cameras or a dedicated stand-alone device, both equipped with near-infrared (NIR) LEDs (Figure 1) [7, 15]. NIR wavelengths are chosen for their ability to produce consistent, high-quality reflections from the corneal surface while minimizing interference from ambient light [10]. This setup ensures precise alignment and enhances image quality, both of which are essential for reliable diagnosis.

The light source is positioned to uniformly illuminate the cornea, generating the first Purkinje image (P1). The camera or imaging sensor, integrated within either the fundus camera attachment or the stand-alone device, is aligned with the light source to capture P1 in a clear, focused frame. To standardize image capture, subject positioning, and lighting conditions are carefully controlled, reducing variability and improving the reliability of geometric measurements [10].

Multiple NIR LEDs can be arranged at different positions around the cornea to enhance diagnostic accuracy. This setup captures multiple P1 reflections from varying angles, providing a more comprehensive analysis of corneal asymmetry and ectasia-related irregularities [15, 16]. Increasing the number of LEDs (e.g., from 4 to 8 or 12) could improve resolution and sensitivity to early-stage abnormalities [10, 11].

Figure 2 illustrates the differences in Purkinje image reflections between healthy and ectatic cornea. These images highlight the characteristic variations in P1 displacement and distortion associated with ectasia, forming the basis for subsequent image analysis. By leveraging these optical distinctions, the method identifies early signs of ectatic conditions through the geometric properties of P1.

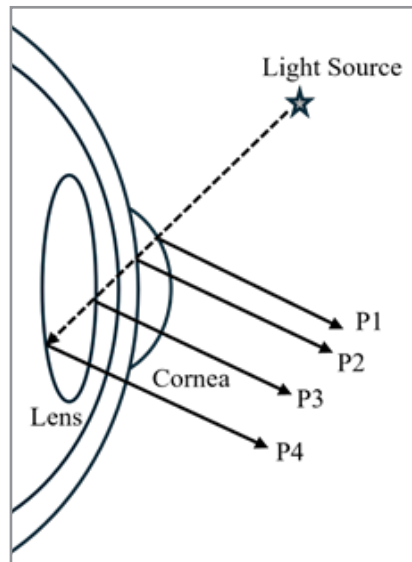


Figure 1: Schematic representation of the optical setup used to capture Purkinje images, highlighting the placement of near-infrared (NIR) LEDs and the imaging sensor. This setup ensures consistent image quality and accurate detection of the P1 reflection.

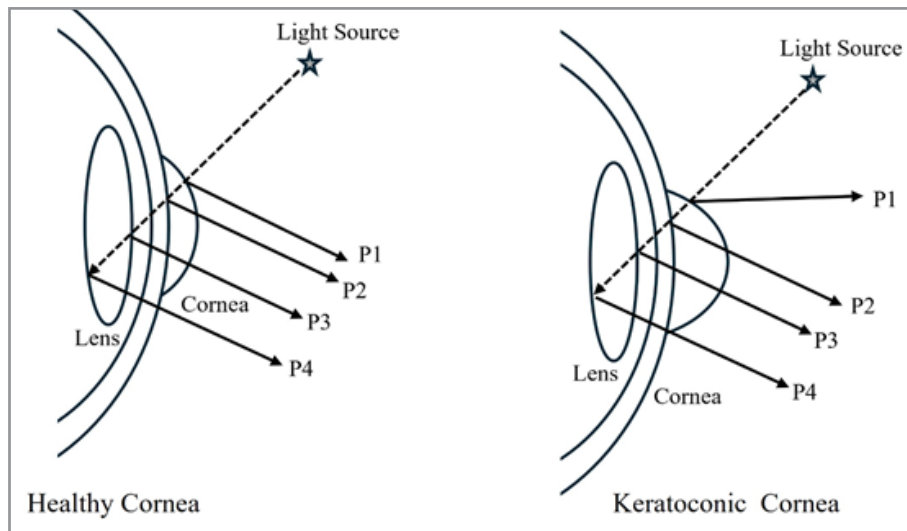


Figure 2: Comparison of Purkinje images from a healthy cornea and a keratoconic cornea. The images illustrate the displacement and distortion of the P1 reflection in the keratoconic eye, which are key indicators used in the proposed diagnostic method.

Image Processing and Analysis

Purkinje images provide valuable diagnostic information, offering insights into corneal and lens conditions. Once captured, the images undergo a series of processing steps to prepare and analyze them for ectasia indicators [8].

The process begins by detecting the pupil center using edge detection algorithms, such as the Canny edge detector. It is fol-

lowed by contrast enhancement to distinguish the pupil from the surrounding iris. The image is aligned with the pupil center as the reference point for all subsequent measurements (Figure 3) [15].

The primary diagnostic metric is the Euclidean distance between the pupil center and the P1 reflection, calculated using the following formula, referred to as Equation (1):

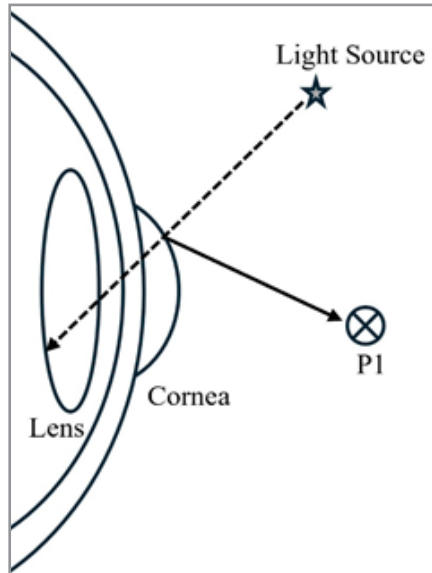


Figure 3: Illustration of the light source and P1 reflection in a healthy cornea. The light path and corresponding reflection point (P1) are shown to demonstrate the normal geometric relationship between the corneal surface and the lens, which is used as a baseline in diagnosing keratoconus.

$$d_{P1} = \sqrt{(x_{P1} - x_0)^2 + (y_{P1} - y_0)^2} \quad (1)$$

where (x_{P1}, y_{P1}) represents the coordinates of P1, and (x_0, y_0) represents the pupil center coordinates [8].

In addition to the Euclidean distance, the analysis quantifies P1 distortion by calculating its area, perimeter, and eccentricity. These geometric metrics are compared to a reference database

derived from healthy corneal images (Figure 4) [7]. Significant deviations in these metrics indicate the presence of corneal irregularities consistent with ectatic conditions.

To enhance diagnostic reliability, the method employs a composite scoring system, integrating the deviations of each metric from its reference value. This scoring system quantifies the severity of ectasia, providing a standardized measure for early detection and follow-up monitoring [9, 17].

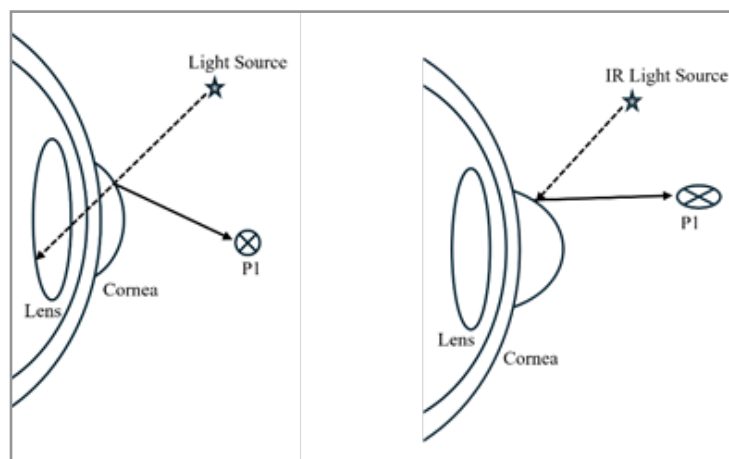


Figure 4: Illustration comparing the P1 reflection in a healthy cornea (left) and a keratoconic cornea (right). The distortion in the P1 reflection for the keratoconic cornea is highlighted, showing the significant deviations that are key diagnostic indicators.

Algorithm for Purkinje Image Analysis

The following algorithm outlines the steps for accurate detection and measurement of Purkinje images, specifically targeting the geometric properties of the first Purkinje image (P1):

- 1. Define Coordinate System:** Establish a coordinate system with the origin (x_0, y_0) at the detected center of the pupil on the camera sensor.

- Capture and Preprocess Image:** Capture the image of the subject's cornea and preprocess it to enhance reflection points and reduce noise, ensuring improved visibility of key features.
- Detect Pupil Center:** Apply edge detection algorithms, such as the Canny edge detector, to identify the pupil's boundaries. Enhance the image contrast to distinguish the pupil from the surrounding iris. Fit an ellipse to the detected edges, modeling the pupil's shape and determining the ellipse's center as the detected pupil center.
- Normalize Image Alignment:** Align the image such that the detected pupil center coincides with the reference point (x0, y0) on the imaging sensor. This standardization ensures consistent measurements across images.
- Identify Reflection Points (P1):** Detect the coordinates (xP1, yP1) of the reflection point P1 on the sensor.
- Measure Distance and Analyze Distortion:** Euclidean Distance: Calculate the Euclidean distance from the pupil center to P1 using Equation 1:

$$d_{P1} = \sqrt{(x_{P1} - x_0)^2 + (y_{P1} - y_0)^2}$$

Reflection Shape Analysis: Analyze the shape and properties of the reflection around P1 by measuring the area, perimeter, and ellipticity of the reflection spot.

- Ellipticity is calculated using the equation:

$$E = \frac{a}{b}$$

where a is the length of the semi-major axis and b is the length of the semi-minor axis of the ellipse that best fits the reflection

- Area is calculated using:

$$A = \pi \cdot a \cdot b$$

- Perimeter is calculated using:

$$P = \pi \cdot [3(a + b) - \sqrt{(3a + b)(a + 3b)}]$$

- Establish Baseline Metrics:** Develop a comprehensive reference database of baseline metrics—distances, areas, perimeters, and eccentricities—from a large sample of healthy corneas. This database serves as the benchmark for identifying deviations indicative of ectatic conditions.
- Comparison and Thresholds:** Compare the patient's corneal metrics with the baseline database using statistical methods to determine whether the measurements fall within normal ranges or indicate ectasia. Thresholds are established based on statistical distributions of the baseline metrics.
- Scoring System:** Combine the deviations of each metric from its reference value to calculate an overall keratoconus severity score SSS using the following formula:

$$S = w_1 \cdot (d_{P1} - d_{ref}) + w_2 \cdot (E - E_{ref}) + w_3 \cdot (A - A_{ref}) + w_4 \cdot (P - P_{ref})$$

where:

- dP1 is the measured Euclidean distance from the pupil center to P1, and dref is the corresponding reference distance for a healthy cornea.
- E is the eccentricity of the reflection spot, and Eref is the reference eccentricity.

- A is the area of the reflection spot, and Aref is the reference area.
- P is the perimeter of the reflection spot, and Pref is the reference perimeter.
- w1, w2, w3, w4 are the weights assigned to each metric, reflecting their relative importance in the overall score.

Higher scores indicate greater deviations from normal corneal profiles, suggesting more severe ectatic conditions.

Composite Scoring System

To enhance diagnostic accuracy, multiple NIR LEDs are positioned around the cornea at different locations. Images are captured individually for each LED position, enabling the calculation of multiple scores (e.g., K1 and K2) from different directions. This multidirectional assessment provides a more comprehensive evaluation by capturing asymmetries and surface irregularities indicative of ectasia.

Data Augmentation Techniques

To overcome the absence of clinical data, data augmentation techniques are utilized to simulate a wide array of corneal shapes by systematically altering K1 (horizontal curvature) and K2 (vertical curvature) values. These variations encompass a spectrum of corneal ectasia stages, including keratoconus and similar conditions, creating a comprehensive dataset of simulated corneal profiles [9, 18]. Each profile is paired with corresponding Purkinje images, capturing the anticipated distortions and displacements in P1 for both healthy and ectatic corneas.

The augmented dataset includes thousands of corneal profiles, each meticulously defined by key P1 metrics such as Euclidean distance, area, perimeter, and eccentricity. This broad dataset provides a reliable foundation for establishing normative and pathological ranges for P1 characteristics. By leveraging this augmented reference, the algorithm can effectively differentiate between normal and abnormal corneal features with high precision [19]. This approach ensures accurate diagnostic comparisons even in the absence of real patient data, laying a practical groundwork for future clinical studies and validation.

Comparison with Reference Data

The diagnostic metrics derived from the subject's Purkinje images—such as Euclidean distance, area, perimeter, and eccentricity—are systematically compared against the augmented reference database. This database, built through data augmentation techniques, defines statistically validated thresholds for normal and ectatic corneal profiles.

Each metric is evaluated in relation to its baseline distribution within the reference database. Metrics closely aligned with the normative ranges are classified as normal, while significant deviations indicate potential ectasia. The algorithm integrates these deviations into a composite scoring system, quantifying the likelihood and severity of ectatic conditions. Scores exceeding predetermined thresholds act as diagnostic alerts, recommending further clinical evaluation where appropriate. This quantitative, comparative process ensures an objective and reproducible assessment of corneal health, even without clinical data.

Potential Validation (Future Work)

While this method is currently theoretical, future work will prioritize validating the approach through rigorous clinical studies. These studies will involve collecting and analyzing data from patients with confirmed diagnoses of corneal ectasia, including keratoconus and related conditions. By correlating clinical observations with the diagnostic metrics derived from Purkinje image analysis, the robustness and reliability of the method can be critically assessed.

The integration of artificial intelligence (AI) and machine learning (ML) is anticipated to significantly enhance the method's diagnostic precision. AI models trained on the augmented dataset, and eventually real patient data, could refine the scoring system, dynamically adapting to diverse populations and corneal conditions. These advancements could enable the method to become a reliable, scalable tool for early ectasia detection, particularly in low-resource settings where high-cost equipment is impractical. Collaboration with ophthalmology institutions and regulatory bodies will further ensure the method's clinical viability and adoption.

Supplementary Note on Mobile Attachment

While this study's primary focus is on the use of fundus cameras and stand-alone devices for Purkinje image analysis, a supplementary approach involves the potential development of a mobile device attachment equipped with a low-intensity white LED. This option could dramatically enhance accessibility, particularly in underserved areas lacking traditional ophthalmic equipment.

However, technical challenges must be addressed to ensure the method's feasibility in mobile environments. These include achieving consistent pupil detection, maintaining image alignment, and minimizing variability in lighting conditions. While promising, this mobile-based approach is currently considered experimental. Future iterations will explore this option's technical and diagnostic viability, focusing on optimizing performance and reliability under real-world conditions.

Results

Simulated Outcomes and Theoretical Analysis

The algorithm developed for Purkinje image analysis demonstrates its potential to effectively differentiate between healthy and ectatic corneas, including keratoconic profiles, by evaluating key geometric metrics: Euclidean distance (dP1), eccentricity (E), area (A), and perimeter (P). Simulated scenarios, which represent corneal shapes with varying degrees of ectasia severity, indicate that the algorithm reliably detects deviations in these metrics compared to reference values derived from healthy corneas [1, 2].

For example, as the severity of corneal ectasia increases, significant deviations are observed in the eccentricity and perimeter of the P1 reflection, both of which diverge substantially from baseline values. Similarly, the Euclidean distance (dP1) shows a marked increase, reflecting greater displacement of P1 from the pupil center—a characteristic associated with ectasia-induced corneal steepening [7, 8]. These findings suggest that the proposed algorithm could serve as a robust tool for identifying and monitoring the progression of corneal ectasia by tracking specific changes in Purkinje image metrics.

Data Augmentation Outcomes

The data augmentation process produced a diverse array of simulated corneal shapes, encompassing both healthy and ectatic profiles. This dataset serves as a robust reference, enabling the algorithm to evaluate patient data by comparing it against established normative and pathological metrics [18, 20].

Analysis of the augmented dataset demonstrates the algorithm's ability to reliably detect abnormalities in Purkinje images. The scoring system effectively categorizes the severity of ectasia based on deviations in key metrics. Visual examples from the dataset illustrate distinct differences between Purkinje images of healthy corneas and those indicative of ectatic conditions [14, 19]. These simulated comparisons validate the proposed method, highlighting its potential for detecting corneal ectasia with high sensitivity, even in the absence of clinical data.

Scoring System Validation (Theoretical)

The scoring system has undergone theoretical validation using simulated cases, demonstrating that higher composite scores correlate with more severe presentations of corneal ectasia. In a series of hypothetical scenarios where patient data were simulated to reflect varying levels of corneal irregularities, the scoring system consistently aligned with the severity of the condition [3, 5].

For instance, scores that deviate significantly from the baseline range—derived from healthy corneas—indicate advanced ectasia stages, prompting further clinical evaluation. These theoretical validations suggest that the scoring system is a reliable quantitative indicator of ectasia severity, accurately distinguishing between mild and advanced stages based on deviations in Purkinje image metrics [6, 21].

Potential Impact

The results of this theoretical study indicate that the proposed method has significant potential to advance the early diagnosis and monitoring of corneal ectasia, particularly in low-resource settings. By leveraging data augmentation and a robust scoring system, this method offers a cost-effective, accessible diagnostic tool that can be seamlessly integrated into existing ophthalmologic practices without requiring specialized equipment [10, 11].

The ability to diagnose ectatic conditions early, using minimal resources, could lead to improved patient outcomes by enabling timely interventions and reducing the need for invasive procedures in advanced stages. This approach addresses critical gaps in healthcare accessibility, offering a scalable solution that benefits underserved communities and has the potential to transform corneal ectasia screening globally [22, 23].

Discussion

Interpretation of Results

The theoretical results suggest that the proposed method for diagnosing corneal ectasia, including keratoconus, through Purkinje image analysis is both feasible and potentially highly effective. By analyzing key geometric metrics—Euclidean distance (dP1), eccentricity (E), area (A), and perimeter (P)—the method provides a detailed and quantitative assessment of corneal irregularities [7, 8]. Each metric captures unique aspects of ectasia-induced changes in corneal geometry.

The scoring system, which integrates these metrics, has demonstrated its ability to quantify the severity of corneal ectasia accurately. This capability makes the method valuable not only for early detection but also for monitoring disease progression over time [3, 5]. These findings emphasize the method's diagnostic reliability and highlight its potential as a low-cost, quantitative solution for identifying ectatic conditions, particularly in settings with limited access to advanced diagnostic tools [1, 4].

Comparison with Existing Methods

Compared to established diagnostic approaches such as corneal topography and tomography, the proposed method offers several distinct advantages. While traditional methods are highly accurate, they are often expensive and require sophisticated equipment that may not be available in all healthcare settings [6, 24]. In contrast, the proposed method is designed to be cost-effective and adaptable to a range of platforms, including attachments to existing fundus cameras and standalone units.

This adaptability makes the method particularly suitable for low-resource environments, where access to high-end ophthalmic devices is limited [10, 11]. Additionally, the non-invasive nature of the technique and the use of near-infrared (NIR) LEDs enhance patient comfort by eliminating the need for direct contact with the eye or complex imaging procedures. These attributes position this method as a practical and accessible alternative to conventional diagnostics, especially in underserved regions [22, 23].

Implications for Clinical Practice

The proposed method can potentially transform the early detection and monitoring of corneal ectasia in clinical practice, particularly in underserved regions. By providing a low-cost and accessible diagnostic tool, this method enables widespread screening and early intervention, which is critical for preventing severe visual impairment and improving patient outcomes [21, 25].

Its simplicity and ease of use allow integration into routine eye examinations, even in settings with limited access to specialized care. By bridging gaps in healthcare accessibility, the method offers an opportunity to proactively manage ectatic conditions in low-resource environments [26, 27]. This approach not only enhances diagnostic capabilities but also serves to improve overall eye health on a global scale.

Integration of AI and Machine Learning for Enhanced Diagnostic Accuracy

Integrating artificial intelligence (AI) and machine learning (ML) into this diagnostic approach offers a transformative opportunity to enhance accuracy, efficiency, and scalability. ML algorithms, particularly those employing deep learning, can be trained on the augmented dataset to detect complex patterns indicative of corneal ectasia [12, 27]. By leveraging a diverse array of Purkinje images—including both healthy and ectatic cases—these models can reliably distinguish various stages of the disease with high precision [13, 28].

AI also has the potential to optimize the composite scoring system by dynamically adjusting the weights assigned to each diagnostic metric (e.g., dP1, E, A, P). Techniques such as reinforcement learning or genetic algorithms can refine these weights

iteratively, tailoring the scoring system to improve diagnostic accuracy across diverse patient populations and corneal conditions. This adaptability enhances the robustness and versatility of the method [29, 30].

Additionally, AI-driven analysis can enable real-time evaluation of Purkinje images during routine eye exams, significantly reducing diagnostic time. This rapid, automated capability, combined with the method's low-cost design, makes it a practical solution for both clinical settings and remote or resource-constrained environments. By facilitating non-specialists in identifying ectatic conditions, AI-powered tools can expand access to early diagnosis and timely intervention, especially in underserved regions [17, 31].

The ongoing evolution of AI technology further underscores its potential to continuously improve diagnostic outcomes, positioning this method at the forefront of accessible and innovative ophthalmic diagnostics.

Practical Implementation in Clinical Settings

To transition this method from theory to practice, several steps are required to ensure successful integration into clinical workflows:

- **Device Adaptation and Setup:** The method's adaptability allows implementation as attachments to existing fundus cameras or standalone, low-cost devices. The method can be deployed as an add-on for clinics with advanced equipment, requiring minimal modifications. For low-resource settings, a standalone or smartphone-based device offers a cost-effective alternative that maintains diagnostic accuracy.
- **Training and Calibration:** Training programs for clinicians and technicians will be essential, focusing on device setup, calibration, and interpretation of results. Regular calibration using the reference database will ensure consistency and reliability across diverse clinical environments.
- **Workflow Integration:** Seamless integration into existing clinical workflows will require user-friendly software interfaces compatible with electronic medical records (EMR). Features such as automatic report generation and alerts for suspected ectatic conditions will streamline the diagnostic process in busy settings.
- **Regulatory Approval and Validation:** Clinical trials will be necessary to validate the method's effectiveness and obtain regulatory approval. Collaborations with ophthalmology institutions and regulatory agencies will be critical to establishing the method's credibility and ensuring its widespread adoption.

Limitations and Future Work

Although this method has a solid theoretical foundation, its primary limitation is the current lack of clinical data for validation. Future work should prioritize collecting clinical data from diverse patient populations to rigorously test and refine the method's diagnostic capabilities. Additionally, further refinement of the algorithm, particularly through AI and ML integration, could enhance its precision by identifying subtle patterns associated with corneal ectasia.

Future research should also explore optimizing the device's design for improved portability and usability in low-resource set-

tings. By addressing these limitations, the method could evolve into a clinically validated, AI-enhanced diagnostic tool for early detection and management of ectatic conditions worldwide.

Conclusion

This study presents a novel, theoretical method for diagnosing corneal ectasia, including keratoconus, through the geometric analysis of Purkinje images. By focusing on the displacement and distortion of the first Purkinje image (P1), the method evaluates key metrics—Euclidean distance, eccentricity, area, and perimeter—to comprehensively assess corneal irregularities. Integration of a composite scoring system enables the quantification of ectasia severity, offering a robust foundation for early detection and continuous monitoring.

A defining feature of this approach is its accessibility and cost-effectiveness, making it particularly suited for low-resource environments. By employing near-infrared LEDs and adaptable configurations—such as attachments to existing fundus cameras or standalone, low-cost devices—the method offers a scalable solution for widespread screening. Additionally, using data augmentation to simulate diverse corneal profiles enhances the method's diagnostic accuracy, even without direct clinical data.

Future advancements in artificial intelligence and machine learning present an exciting avenue for enhancing this diagnostic tool. AI-driven algorithms could refine the scoring system, automate diagnostic processes, and improve overall accuracy, enabling real-time analysis and broader applicability across diverse healthcare settings. These advancements can potentially elevate the method into a practical, high-precision tool for early detection and proactive management of corneal ectasia.

In conclusion, the proposed method represents a significant advancement in ophthalmic diagnostics, potentially improving access to early detection and management of corneal ectasia, particularly in underserved areas. By addressing current limitations, validating the method through clinical studies, and integrating AI-driven improvements, this method could establish a new standard for accessible, reliable, and scalable corneal diagnostics worldwide.

Conflict of Interest Disclosure

The author, Mohsen Sharifzadeh, has applied for a patent (US Patent Application Number: 18/746,773) related to the method described in this manuscript for diagnosing corneal ectasia using Purkinje images analysis. This potential financial interest has been disclosed in accordance with the journal's policy on conflicts of interest.

Code and Data Availability Statement

This manuscript presents a theoretical approach, and no empirical data or code were generated or used in this study. Therefore, no datasets or code are required for replication or interpretation of the findings.

Disclosure Section

The author acknowledges the use of AI tools, specifically OpenAI's ChatGPT, for assistance in refining the language and grammar of the manuscript. No AI tools were used for data collection, analysis, or figure creation. All scientific content, methodologies, and results were developed by the author.

References

1. Rabinowitz Y. S. (1998). Keratoconus. *Survey of ophthalmology*, 42(4), 297–319. [https://doi.org/10.1016/s0039-6257\(97\)00119-7](https://doi.org/10.1016/s0039-6257(97)00119-7)
2. Gomes, J. A., Tan, D., Rapuano, C. J., Belin, M. W., Ambrósio, R., Jr, Guell, J. L., Malecaze, F., Nishida, K., Sangwan, V. S., & Group of Panelists for the Global Delphi Panel of Keratoconus and Ectatic Diseases (2015). Global consensus on keratoconus and ectatic diseases. *Cornea*, 34(4), 359–369. <https://doi.org/10.1097/ICO.0000000000000408>
3. Belin, M. W., Kundu, G., Shetty, N., Gupta, K., Mullick, R., & Thakur, P. (2020). ABCD: A new classification for keratoconus. *Indian journal of ophthalmology*, 68(12), 2831–2834. https://doi.org/10.4103/ijjo.IJO_2078_20
4. Kymes, S. M., Walline, J. J., Zadnik, K., Gordon, M. O., & Collaborative Longitudinal Evaluation of Keratoconus study group (2004). Quality of life in keratoconus. *American journal of ophthalmology*, 138(4), 527–535. <https://doi.org/10.1016/j.ajo.2004.04.031>
5. Ambrósio, R., Jr, Lopes, B. T., Faria-Correia, F., Salomão, M. Q., Bühren, J., Roberts, C. J., Elsheikh, A., Vinciguerra, R., & Vinciguerra, P. (2017). Integration of Scheimpflug-Based Corneal Tomography and Biomechanical Assessments for Enhancing Ectasia Detection. *Journal of refractive surgery (Thorofare, N.J. : 1995)*, 33(7), 434–443. <https://doi.org/10.3928/1081597X-20170426-02>
6. Klyce S. D. (1984). Computer-assisted corneal topography. High-resolution graphic presentation and analysis of keratoscopy. *Investigative ophthalmology & visual science*, 25(12), 1426–1435.
7. Rosales, P., Dubbelman, M., Marcos, S., & van der Heijde, R. (2006). Crystalline lens radii of curvature from Purkinje and Scheimpflug imaging. *Journal of vision*, 6(10), 1057–1067. <https://doi.org/10.1167/6.10.5>
8. Turuwhenua J. (2009). Reconstructing ocular surfaces by Purkinje images: an exact ray approach. *Ophthalmic & physiological optics : the journal of the British College of Ophthalmic Opticians (Optometrists)*, 29(1), 80–91. <https://doi.org/10.1111/j.1475-1313.2008.00612.x>
9. Kebaili, A., Lapuyade-Lahorgue, J., & Ruan, S. (2023). Deep Learning Approaches for Data Augmentation in Medical Imaging: A Review. *Journal of imaging*, 9(4), 81. <https://doi.org/10.3390/jimaging9040081>
10. Ettore Giardini M. (2015). The Portable Eye Examination Kit: Mobile phones can screen for eye disease in low-resource settings. *IEEE pulse*, 6(6), 15–17. <https://doi.org/10.1109/MPUL.2015.2476563>
11. Bastawrous, A., Rono, H. K., Livingstone, I. A., Weiss, H. A., Jordan, S., Kuper, H., & Burton, M. J. (2015). Development and Validation of a Smartphone-Based Visual Acuity Test (Peek Acuity) for Clinical Practice and Community-Based Fieldwork. *JAMA ophthalmology*, 133(8), 930–937. <https://doi.org/10.1001/jamaophthalmol.2015.1468>
12. Ting, D. S. W., Pasquale, L. R., Peng, L., Campbell, J. P., Lee, A. Y., Raman, R., Tan, G. S. W., Schmetterer, L., Keane, P. A., & Wong, T. Y. (2019). Artificial intelligence and deep learning in ophthalmology. *The British journal of ophthalmology*, 103(2), 167–175. <https://doi.org/10.1136/bjophthalmol-2018-313173>

13. Esteva, A., Robicquet, A., Ramsundar, B., Kuleshov, V., DePristo, M., Chou, K., Cui, C., Corrado, G., Thrun, S., & Dean, J. (2019). A guide to deep learning in healthcare. *Nature medicine*, 25(1), 24–29. <https://doi.org/10.1038/s41591-018-0316-z>
14. Ibrahim, M., Al Khalil, Y., Amirrajab, S., Sun, C., Breeuwer, M., Pluim, J., Elen, B., Ertaylan, G., & Dumontier, M. (2024). Generative AI for Synthetic Data Across Multiple Medical Modalities: A Systematic Review of Recent Developments and Challenges. *Artificial Intelligence Review*, 57(3), 2345–2378. arXiv:2407.00116
15. Chang, D., H. (2011). Centering IOLs using Purkinje images. *Cataract Refract Surg Today*, 11(6), 35–38.
16. Narang, P., Holladay, J., Agarwal, A., Jaganathasamy, N., Kumar, D. A., & Sivagnanam, S. (2019). Application of Purkinje images for pinhole pupilloplasty and relevance to chord length μ . *Journal of cataract and refractive surgery*, 45(6), 745–751. <https://doi.org/10.1016/j.jcrs.2019.02.037>
17. Al-Ars, Z., Agba, O., Guo, Z., Boerkamp, C., Jaber, Z., & Jaber, T. (2024). NLICE: Synthetic medical record generation for effective primary healthcare differential diagnosis. In *Proceedings of the 2023 IEEE 23rd International Conference on Bioinformatics and Bioengineering (BIBE)*. IEEE. <https://doi.org/10.1109/BIBE60311.2023.00071>
18. Athalye, C., & Arnaout, R. (2023). Domain-guided data augmentation for deep learning on medical imaging. *PLoS one*, 18(3), e0282532. <https://doi.org/10.1371/journal.pone.0282532>
19. Shorten, C., Khoshgoftaar, T. M., & Furht, B. (2021). Text Data Augmentation for Deep Learning. *Journal of big data*, 8(1), 101. <https://doi.org/10.1186/s40537-021-00492-0>
20. Mumuni, A., & Mumuni, F. (2022). Data augmentation: A comprehensive survey of modern approaches. *Array* 16, 100258.
21. Reinstein, D. Z., Archer, T. J., Gobbe, M., Silverman, R. H., & Coleman, D. J. (2008). Epithelial thickness in the normal cornea: three-dimensional display with Artemis very high-frequency digital ultrasound. *Journal of refractive surgery (Thorofare, N.J. : 1995)*, 24(6), 571–581. <https://doi.org/10.3928/1081597X-20080601-05>
22. Williams, C., et al. (2017). The Arlight: A pocket ophthalmoscope to revitalise undergraduate teaching and provide high-quality low-cost diagnostic tool for low-income countries. *Eye News*.
23. World Health Organization. (2013). Universal eye health: A global action plan 2014–2019. World Health Organization. *Castro-Martínez, F., De la Cruz Sánchez, E., Nieto Martínez, J., Fernández Cañavate, F. J., & Fernández-Pacheco, D. G. (2016). Corneal topography in keratoconus: state of the art. Eye and vision (London, England)*, 3, 5. <https://doi.org/10.1186/s40662-016-0036-8>
24. Mohammadi, S. F., Mohammadzadeh, V., Kadivar, S., Beheshtnejad, A. H., Norooznezhad, A. H., & Hashemi, S. H. (2018). Topographic typology in a consecutive series of refractive surgery candidates. *International ophthalmology*, 38(4), 1611–1619. <https://doi.org/10.1007/s10792-017-0631-2>
25. Kovai, V., Krishnaiah, S., Shamanna, B. R., Thomas, R., & Rao, G. N. (2007). Barriers to accessing eye care services among visually impaired populations in rural Andhra Pradesh, South India. *Indian journal of ophthalmology*, 55(5), 365–371. <https://doi.org/10.4103/0301-4738.33823>
26. Compton B, Barash D, Farrington J, Hall C, Herzog D, Meka V. (2018). Access to Medical Devices in Low-Income Countries: Addressing Sustainability Challenges in Medical Device Donations." *National Academy of Medicine*. 8: 1–9.
27. Litjens, G., Kooi, T., Bejnordi, B. E., Setio, A. A. A., Ciompi, F., Ghafoorian, M., van der Laak, J. A. W. M., van Ginneken, B., & Sánchez, C. I. (2017). A survey on deep learning in medical image analysis. *Medical image analysis*, 42, 60–88. <https://doi.org/10.1016/j.media.2017.07.005>
28. Goodman, D., & Zhu, A. Y. (2024). Utility of artificial intelligence in the diagnosis and management of keratoconus: a systematic review. *Frontiers in ophthalmology*, 4, 1380701. <https://doi.org/10.3389/fopht.2024.1380701>
29. Topol E. J. (2019). High-performance medicine: the convergence of human and artificial intelligence. *Nature medicine*, 25(1), 44–56. <https://doi.org/10.1038/s41591-018-0300-7>
30. Beede, E., Baylor, E., Hersch, F., Iurchenko, A., Wilcox, L., Ruamviboonsuk, P., & Vardoulakis, L. M. (2020). A human-centered evaluation of a deep learning system deployed in clinics for the detection of diabetic retinopathy. In *Proceedings of the 2020 CHI Conference on Human Factors in Computing Systems* (pp. 1–12). ACM.
31. Pamplona, V. F., Mohan, A., Oliveira, M. M., & Raskar, R. (2010). NETRA: Interactive display for estimating refractive errors and focal range. *ACM Transactions on Graphics*, 29(4), 77.