

# Usefulness of Early Ultrasound Thoracal Assesment for A Group of Newborn Foals, Under Suspicion of Rhodococcus Equi Infection, in Increasing the Survival Rate Associate with Early Treatment

Otilia Teodora Rachieru<sup>1\*</sup>, Diana Gosav<sup>2</sup>, Dragos Pistol<sup>1</sup>, Teodoru Soare<sup>2</sup>, Raluca Tiu<sup>2</sup>, George Nicolae<sup>2</sup>, Iuliana Ionaşcu<sup>2</sup>, and Gabriel Cotor<sup>2</sup>

<sup>1</sup>Department for Horse Breeding and Husbandry – National Forest Administrator – ROMSILVA, <sup>9A</sup>Petricani Str, District <sup>2</sup>, <sup>023841</sup>, Bucharest, Romania

<sup>2</sup>University of Agronomic Sciences and Veterinary Medicine of Bucharest, <sup>59</sup>Marăşti Blvd, District <sup>1</sup>, Bucharest, Romania

**\*Corresponding author:** Otilia Teodora Rachieru, Department for Horse Breeding and Husbandry – National Forest Administrator – Romsilva, 9A Petricani Str, District 2, 023841, Bucharest, Romania.

**Submitted:** 10 July 2025    **Accepted:** 16 July 2025    **Published:** 21 July 2025

 <https://doi.org/10.63620/MK.JCMRRR.2025>.

**Citation:** Rachieru, O. T., Gosav, D., Pistol, D., Soare, T., Tiu, R., Nicolae, G., Ionaşcu, I., & Cotor, G. (2025). Usefulness of Early Ultrasound Thoracal Assesment for A Group of Newborn Foals, Under Suspicion of Rhodococcus Equi Infection, in Increasing the Survival Rate Associate with Early Treatment. *J of Comp Med Res Rev Rep*, 2(4), 01-07.

## Abstract

The paper aimed to present the importance of early thoracic ultrasound assessment for a group of newborn foals, with suspicion of Rhodococcus Equi outbreak, in order to increase survival rate. We studied a group of 32 Pure Bred Arabian pregnant mares, that gave birth of 7 nonviable foals and 25 viable foals, out of which 7 foals were dead between 14 days – 8 months of age, with clinical and postmortem signs associates with enzootic Rhodococcus Equi pneumonia. Out of the 25 viable foals, we have performed an ultrasound examination of thorax and lungs for a number of 13 foals, with age between 2 days and 3 months and establish a prophylactic protocol treatment for all the foals that had significant to mild ultrasound changes (without or with mild clinical signs associate with ultrasound assessment). In conclusion, all foals that undergone prophylactic treatment, according to ultrasound assessment, have survived over 8 months of life, while most of foals that were born before and after the assessment, died, all with clinical and post mortem signs of severe pneumonia and septicemia.

**Keywords:** Newborn Foals, Infectious Pneumonia, Early Thoracic Ultrasound Assessment, Survival Rate

## Introduction

Pneumonia caused by soil bacteria Rhodococcus Equi occurs in the foals of most horse breeds, all over the world, posing a significant challenge for veterinary practitioners, causing lot of economical loses within stud farm/ equine breeding industry worldwide [1]. That is why many researchers constantly try to find new solutions for successful prevention and management of this disease, but it still remains poorly controlled Rhodococcus etiological agent, a well - known ubiquitous, opportunistic, intracellular soil saprophyte Rhodococcus Equi may be responsible for severe pyogranulomatous bronchopneumonia that evolve endemic, as a stable enzootic disease in some stud farms,

with morbidity up to 90 % of foals and mortality up to 40%. It is currently accepted that foals become infected within the first hours or days of life likely through inhalation of contaminated dust. However, clinical signs and pulmonary lesions may not become apparent until several weeks later.

The references note that R. Equi can be biophyte in adult horses, becoming conditioned pathogen and is more likely to be found in geographical areas that are sandy and with a very dry and warm climate. The germ resists up to 6 weeks on dry manure, survive over 1 year in external environment (stables, paddocks, pastures).

The aim of our study is to highlight once again that thoracic ultrasonography proves to be a valuable tool for the early detection of *Rhodococcus equi* pneumonia, even before clinical signs appear. Compared to traditional methods like radiography or bacterial culture, ultrasound allows for real-time visualization of pulmonary lesions and monitoring of disease progression. This makes it a crucial tool in screening foals at high risk of infection and optimizing early treatment strategies.

## Materials and Methods

The study was conducted in Mangalia Stud Farm, who was confronted in 2024 season with a major outbreak on enzootic pneumonia in newborn foals, under suspicion of *R. equi*. During the foaling season, out of 32 pregnant mares, 25 viable foals were born, and 7 were non-viable (21.87% mortality within the first 24 hours postpartum). Of the 25 viable foals, 6 died between 14 days and 3 months of age, and 1 died after weaning at 8 months. The overall mortality rate at the end of the season was 28%.

In order to more accurately assess the general health status and initiate an early protocol for hygienic management, dietary management, and antimicrobial treatment based on ultrasound findings, we performed thoracic ultrasound assessments on 13 foals that were born during the time of our action. Ultrasound has proven to be one of the most effective methods to assess early pulmonary changes, even before the onset of clinical signs.

Of the 13 foals assessed, 10 showed significant ultrasound findings at the time of assessment (regardless of their age). These foals underwent an antimicrobial protocol consisting of Rifampicin (5 mg/kg, PO, twice daily) and Clarithromycin (15 mg/kg, PO, once daily) for 4 to 6 weeks, with treatment extension up to 12 weeks depending on their clinical development [3].

For the foals that died, postmortem examinations were performed. These were conducted either at the Faculty of Veterinary Medicine in Bucharest – Pathology Department (2 cases) or in the field (5 cases) by our field veterinarian.

We also performed PCR tests on postmortem harvested organs, as well as bacteriological tests on nasal swabs collected from foals that had nasal discharge at the time of ultrasound assessment. However, all of these tests were negative for *R. equi*.

## Results and Discussions

### Post Mortem Findings

During cases analysis, 3 out of 7 cases died before ultrasound assessment, with severe clinical signs associated with bronchopneumonia, peritonitis, septicemia, sometimes joint disease. We have found typical lesions, encountered in *R. Equi* infection, such as catarrhal pneumonia, serofibrinous pleuritis, pulmonary oedema (BA 20776/07.07.2024 – foal out of brood mare 935- dead at 14 days of age), purulent broncho-

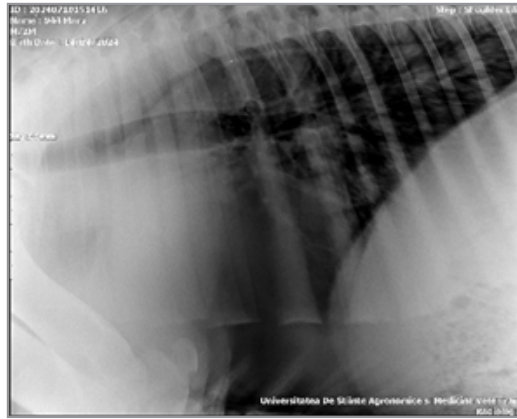
pneumonia, with areas of pulmonary consolidations, serofibrinous pleuritis, pyothorax (B. A 20749/ 04.07.2024 – foal out of mare 928, dead at 14 days of age), purulent bronchopneumonia with multiple purulent spots (foal out of mare 931, dead at 2 months old), another 3 cases were born after the ultrasound assessment, so they receive antimicrobial protocol after the onset of clinical signs, with poor prognosis. Post mortem exams have highlighted cyanotic mucosae, small pulmonary purulent spots, in resolution, purulent content in abdominal cavity, serofibrinous adhesions on spleen and heart (case of foal out of brood mare 945 dead at 2 months old), hydronephrosis, renal basin dilatation, with purulent content in urine, deletion of the renal cortico-medullary demarcation, cause of death was bronchopneumonia, with pyelonephritis and hydronephrosis (foal out of brood mare IM 948, dead at 5 weeks old), serosanguineous pleural liquid in small quantity, abdominal cavity with mild purulent content, joints disease, with purulent content in hocks and fetlocks, dead in septic shock, generalised peritonitis (foal out of brood mare 905, dead at 7 weeks old). 1 foal, out of brood mare 944 have been assessed by ultrasound, but, at the time of our assessment, pulmonary appearance did not impose the beginning of antimicrobial protocol, therefore he received the medication 1 month later, at the onset of severe clinical signs. He additionally undergone an X-ray examination, at 3.5 months old (see fig. 1 and fig. 2) when he was under treatment for about 1 month, this case did survive weaning age, but he died later, at 8 months old, after separation from mother. Post mortem examination revealed cyanotic mucosae, small pulmonary purulent spots in resolution, pleural liquid in small quantity, with purulent aspect, abdominal cavity with mild purulent content, cause of death- septic shock, generalized chronic peritonitis [4].

Foals dead in the first 2 weeks of life have developed specific lesions for acute pneumonia, with pulmonary oedema, serofibrinous pleuritis, catarrhal bronchopneumonia, while those who survived over 2 months of age, have pulmonary lesions in resolution, but developed abdominal lesions (generalised peritonitis and 1 case pyelonephritis).

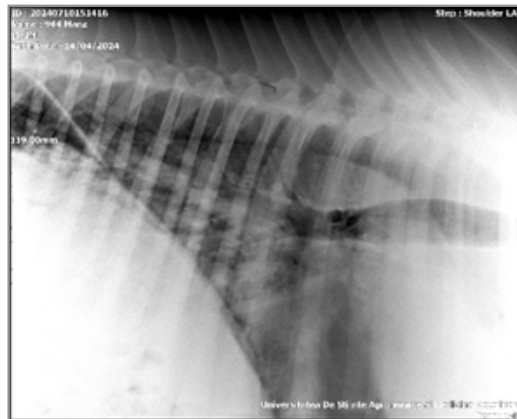For nonviable foals (7 dead within 24 hours after birth), postmortem examinations did not reveal specific lesions for any infectious agent, their death was due to dystocia parturition, who led to lesions that were incompatible with life (pulmonary haemorrhage, subdural hematomas, ribs fractures).

Although PCR results were negative, the clinical presentation, ultrasonographic findings, and response to treatment strongly suggest *Rhodococcus equi* as the causative agent. The negative PCR results could be due to factors such as the timing of sample collection, bacterial load, or test sensitivity.

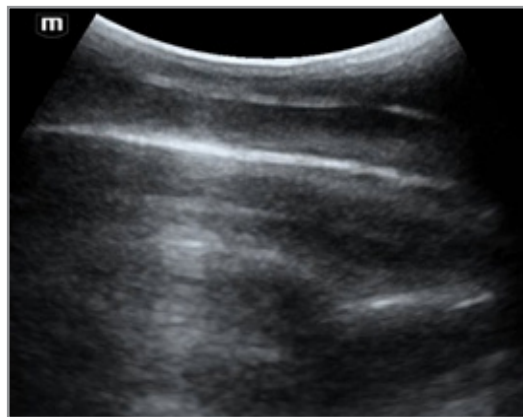
Ultrasound findings are described in table no.1, and in fig. 3-13, radiological findings in fig. 1 and 2.



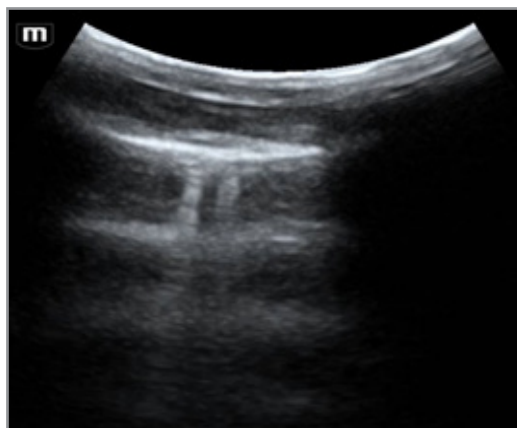
**Figure 1:** Left latero-lateral radiograph of foal 944 showing showing mixed alveolar-interstitial pattern



**Figure 2:** Right latero-lateral radiograph of 944 foal, unstructured interstitial pattern within the ventral aspect of the right caudal lobe, with multifocal round soft tissue opaque nodules



**Figure 3:** thickened pleura on 944 brood mare foals

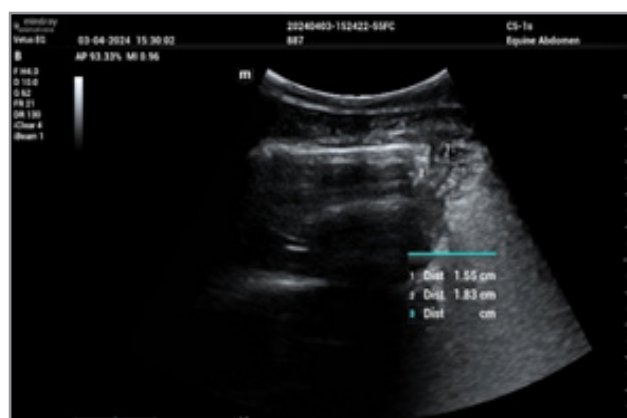

**Figure 4:** B lines on 944 brood mare foals

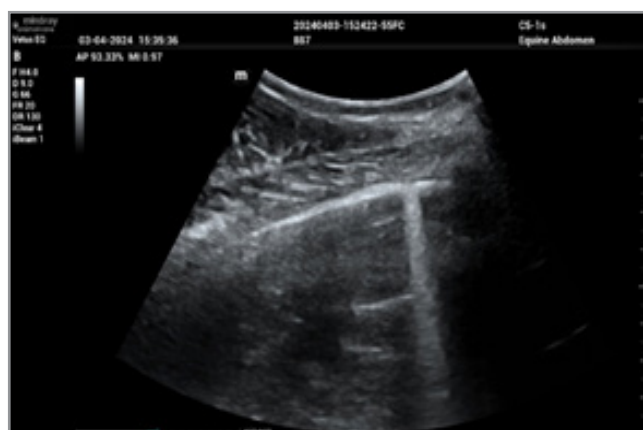**Table 1:** Thoracal ultrasound findings for 13 cases, clinical signs on assessment data, therapeutic protocol

No.	Case (mother's ID)	Birth data	History, ultrasound findings	Therapeutic protocol, recommendations
1	Foal out of brood mare 884	12.01. 2024	No clinical signs. Right hemithorax hyperechoic pleura, with no inflammation. Left hemithorax, pleura slightly hyperechoic pleura, comet tail. Pulmonary consolidation areas, due to a pleural abscess on ventral 7th intercostal space, with dimensions of 1.45/ 0.68cm	Clarithromycin & Rifampicin (30 days). Clinically sound at weaning
2	Foal out of brood mare 919, ultrasound on fig. 8.	16.01. 2024	Severe dyspnoea, purulent nasal discharge, horn. Right hemithorax - thickened, irregularly pleura, hyperechoic with comet tail, abscess of, 1.76/1.19 cm, delimited by gas points and pulmonary consolidation Left hemithorax - thickened pleura, comet tails, multiple small abscesses of different size in pulmonary parenchyma, see figure 8.	Cefquinome, Gentamycin, Bromhexine, Dexamethasone (03.04-09.04), then Clarithromycin & Rifampicin (30 days). Clinically sound at weaning.
3	Foal out of brood mare 947 on fig. 13	27.01. 2024	No clinical signs. Left hemithorax- irregularly pleura, comet tail, no pleural liquid. Right hemithorax - slightly irregularly pleura, comet tail, abscess cranial intercostal spaces 1-4, 1.68cm/2.10 cm, see figure 13	Clarithromycin & Rifampicin (30 days). Clinically sound at weaning
4	Foal out of brood mare 889	05.02. 2024	no clinical signs, negative nasal swab no ultrasound changes	No treatment. Clinical sound at weaning.
5	Foal out of brood mare 887, on fig. 5 and 6	05.02. 2024	nasal swab negative results, mild clinical signs (purulent nasal discharge). Left hemithorax - irregularly pleura, thickened, comet tails, abscess of 1.55/1.99 cm, pulmonary consolidation. Right hemithorax – hyperechoic pleura, thickened but smooth, comet tails (figure. 5, 6)	Clarithromycin & Rifampicin (30 days). Clinically sound at weaning
6	Foal out of 942 brood mares, fig. and 11,12	26.02. 2024	Mild cough, dyspnoea, nasal discharge. Left hemithorax - comet tails, small abscess, inflamed pleura. Right hemithorax – 2 abscesses of 1.37cm, respectively 2.67 cm, pulmonary consolidation, hyperechoic pleura, comet tail bilaterally	Clarithromycin & Rifampicin (30 days). Clinically sound at weaning
7	Foal out of 949 brood mare fig.14	28.02. 2024	Mild enteritis, slight submandibular lymphnodes inflammation. Left hemithorax- pleura is thickened, slightly irregularly, hypoechoic, comet tail, abscess in with area of pulmonary consolidation, subpleural anechoic line, due to a small liquid quantity (mild pleural effusion). Right hemithorax - 1 abscess, thickened, hypoechoic, irregularly pleura, pulmonary consolidation, micro abscesses in pulmonary parenchyma. (see figure 14).	Penicillin and gentamycin 3 days, then Clarithromycin and Rifampicin for 30 days. Clinically sound at weaning
8	Foal out of 939 brood mares	05.03. 2024	No clinical signs, nasal swabs negative. Left hemithorax comet tails, pleural inflammation, abscesses on pleural surface (not in pulmonary parenchyma). Right hemithorax- thickened pleura, comet tail.	Clarithromycin & Rifampicin (30 days). Clinically sound at weaning.

9	Foal out of 909 brood mare, fig.7	26.03. 2024	Pleura hyperechoic, slightly thickened, a pulmonary abscess with dimensions of 2.33/1.83 cm, no comet tails (see fig. 7).	Clarithromycin & Rifampicin (30 days). Clinically sound at weaning
10	Foal out of 938 brood mares	31.03. 2024	No pulmonary appearance, no inflammatory signs	No treatment. Clinical sound at weaning.
11	Foal out of 921 brood mare, fig. 9	12.03. 2024	septic arthritis on knee and hock. He is already under general treatment and also local intraarticular lavage with Gentamycin. Left hemithorax - irregularly, hypoechoic pleura, mild thickened areas, multiple comet tails small abscess. Right hemithorax with hypoechoic, thickened, irregularly pleura (fig.9)	Clarithromycin and Rifampicin for 30 days, intraarticular lavage, clinically sound at weaning
12	Foal out of 944 brood mare, fig. 3 and 4		Right hemithorax- hypoechoic pleura, comet tail Left hemithorax- comet tails, hyperechoic pleura, thickened areas, comet tail, (fig. 3, 4). See also fig. 1 and 2, for RX. He developed severe sing later, leading to death at 8 months	No early treatment, started treatment late, at the onset of clinical sings but he had poor prognosis
13	Foal out of 940 brood mare, fig. 10	02.04. 2024	Born with flexor tendons contractures. He received. Right hemithorax- pleura slightly thickened, comet tail bilateral, pleura is hypoechoic and irregularly. Left hemithorax - comet tails in moderate inflammation, suggesting bacterial interstitial pneumonia, 1 microabscessation (1cm) and pulmonary consolidation areas. (fig.10)	Cefquinome and Gentamycin postpartum, then Clarithromycin and Rifampicin for 30 days. Clinical sound at weaning.

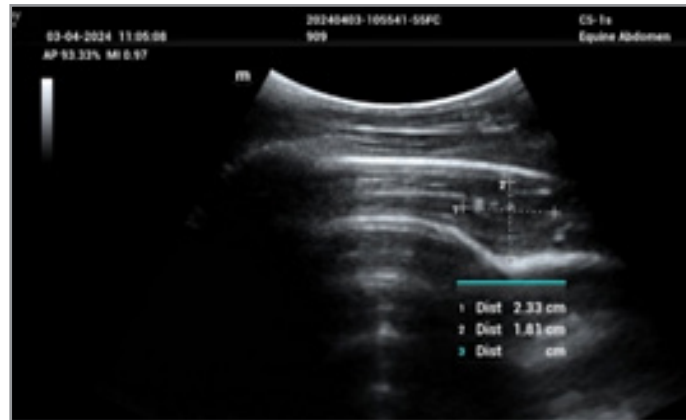


**Figure 5:** 887 foal – pulmonary abscess

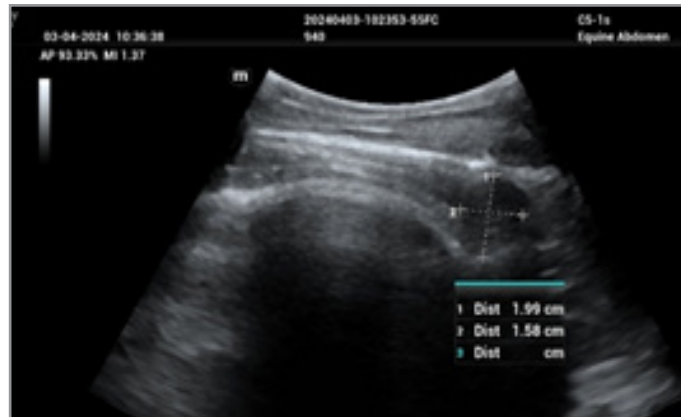

**Figure 6:** 887 foal – pulmonary B lines

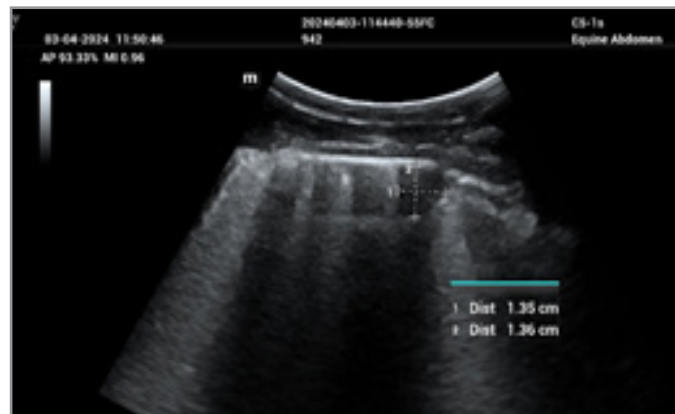




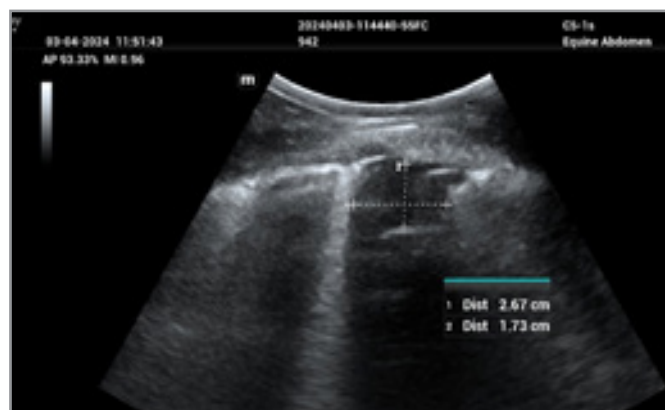
**Figure 7:** 909 foal – pulmonary abscess



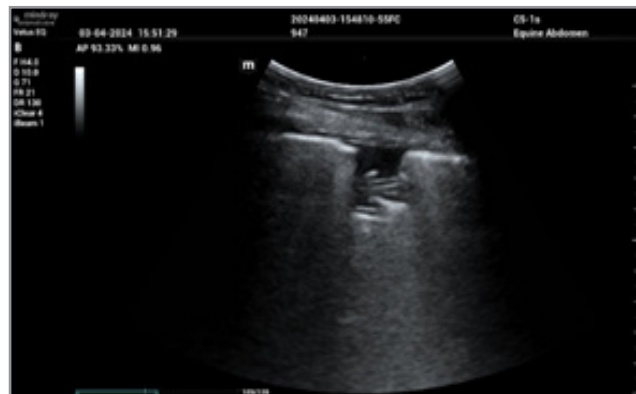**Figure 10:** 940 foal – pulmonary abscess



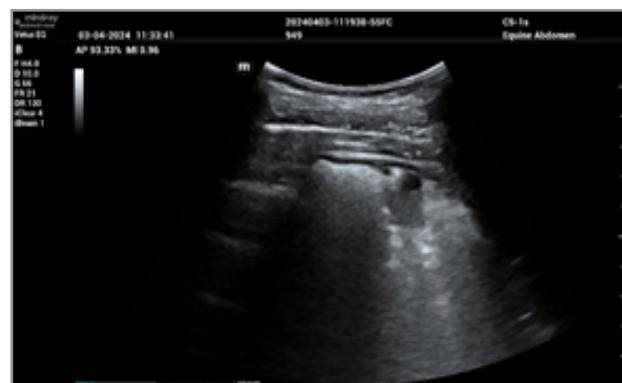**Figure 11:** 942 foal- comet tails, B lines



**Figure 12:** 942 foal – pulmonary abscess



**Figure 13:** 947 foal – pulmonary consolidation, gas points



**Figure 14:** 949 foal, pulmonary consolidation, pleural fluid line, gas points

## Conclusions

The ultrasound assessment proved crucial for diagnosing and monitoring this suspected infectious disease, offering major advantages such as safety for personnel, quick testing, and immediate data interpretation. It is particularly sensitive for detecting peripheral lung masses or lesions in areas difficult to assess radiologically [5].

As PCR tests and microbiological cultures from nasal discharge did not provide conclusive results, ultrasound remains the primary method for assessing pulmonary health in foals (2 days to 4 months old) on stud farms with outbreaks of infectious pneumonia. Early detection of subclinical changes and temporary antimicrobial treatment were effective in preventing severe clinical signs and mortality from *Rhodococcus pneumoniae*.

The prognosis depends on the severity of clinical signs when treatment begins, with a combination of ultrasound screening and antimicrobial prophylaxis proving effective in reducing morbidity and mortality. However, it remains unclear which foals require treatment, as some may regress spontaneously. For example, a foal from broodmare 944, which showed no significant ultrasound changes, developed severe clinical signs and died at 8 months, despite treatment, while foals from broodmares 938 and 889, without significant ultrasound changes and no antimicrobial treatment, reached weaning age in healthy condition [6, 7].

Foals born before or after the ultrasound assessment experienced significant mortality (3 before and 3 after) due to the lack of ear-

ly detection and timely treatment, demonstrating the importance of early intervention.

## References

1. Chaffin, M. K., Cohen, N. D., & Martens, R. J. (2003). Evaluation of equine breeding farm management and preventative health practices as risk factors for development of *Rhodococcus equi pneumoniae* in foals. *Journal of the American Veterinary Medical Association*, 222(4), 476–485. <https://doi.org/10.2460/javma.2003.222.476>
2. Pop, M., & Vasile, C. (1998). Infectious disease in equids (pp. 47–61). Bucharest, Romania: Ceres Publishing House.
3. Rakowska, A., Cywińska, A., & Witkowski, L. (2020). Current trends in understanding and managing equine *Rhodococcus*. *Animals*, 10(10), 1910. <https://doi.org/10.3390/ani10101910>
4. Reuss, S. M., Chaffin, M. K., & Cohen, N. D. (2009). Extrapulmonary disorders associated with *Rhodococcus equi* infection in foals: 150 cases (1987–2007). *Journal of the American Veterinary Medical Association*, 235(7), 855–863. <https://doi.org/10.2460/javma.235.7.855>
5. Robinson, N. E., & Sprayberry, K. A. (2009). *Current therapy in equine medicine* (6th ed.). Saunders/Elsevier.
6. Rose, R. J., & Hodgson, D. R. (2003). *Manual of equine practice* (2nd ed.). Saunders/Elsevier.
7. Witkowski, L. (2019). Treatment and prevention of *Rhodococcus equi* in foals. *Veterinary Record*, 185(1), 16–18. <https://doi.org/10.1136/vr.13736>