

# Effect of Administration of a Non-Selective NO Synthase Inhibitor During Pregnancy on Cortical Development in Newborn Rats

Rusak TS, Bon EI, \* Maksimovich N Ye and Martsun PV

Grodno State Medical University, 80, Gorkogo St., 230009, Grodno, Republic of Belarus

**\*Corresponding author:** Lizaveta I Bon, Candidate of biological science, assistant professor of pathophysiology department named D.A. Maslakov, Grodno State Medical University, 80, Gorky St, 230009, Grodno, Belarus. Tel: +375336878764

Submitted: 27 Mar 2023

Accepted: 05 Apr 2023

Published: 20 Apr 2023

**Citation:** Rusak TS, Bon EI, Maksimovich N Ye, et al. (2023) Effect of Administration of a Non-Selective NO Synthase Inhibitor During Pregnancy on Cortical Development in Newborn Rats. *J Psych and Neuroche Res* 1(1) 01-03.

## Abstract

Preeclampsia is a major cause of premature birth, intrauterine growth retardation and perinatal mortality. In developed countries, it is the cause of about 16-18% of maternal deaths and up to 40% of fetal and neonatal deaths [1]. Endothelial dysfunction can lead to the development of preeclampsia. The administration of the nonselective NOS inhibitor L-NAME to female rats during placenta caused morphological abnormalities in the frontal cortex neurons of rat offspring on day 1 of postnatal development, which were manifested by an increase in cell size and an increased proportion of hypochromic neurons.

**Keywords:** L-Name, Brain Cortex, Rat, Pregnancy

## Introduction

Preeclampsia is a major cause of preterm birth, intrauterine retardation and perinatal mortality. In developed countries, it accounts for about 16-18% of maternal deaths and up to 40% of fetal and neonatal deaths [2]. Endothelial dysfunction is one of the causes of gestosis [3]. The endothelium is actively involved in the regulation of vascular tone, and hence in the regulation of blood circulation, including placental circulation. Inhibition of the vasodilator properties of the endothelium of blood vessels is the cause of impaired uteroplacental circulation and intrauterine development of the offspring [4]. The main mechanism of endothelial dysfunction is impaired nitric oxide (NO) production [5]. NO in the brain is known to be formed in neuronal and extra-neuronal sources forming a 'nitroergic system'. In the nervous system, NO takes part in synaptic connections as a neurotransmitter, ensuring the efficiency of synaptic transmission (synaptic plasticity), plays a role in the regulation of synaptogenesis during the formation of the nervous system and cerebral blood flow, and provides antigen homeostasis [6, 7]. The use of the non-selective NO synthase inhibitor (NOS) N $\omega$ -nitro-L-Arginine Methyl Ester (L-NAME) is a model of experimental pre-eclampsia et al. [8]. Adverse effects of L-NAME on the cardiovascular system, decreased perfusion of the uterine-placental bed, reduced placental and offspring weight are known. However, changes in neuronal structure in the brain of the offspring under conditions of experimental NOS inhibition are poorly understood.

## Objective

To study the morphological features of neurons of the cerebral cortex of newborn rats under conditions of administration of a non-selective NO synthase inhibitor (L-NAME) during pregnancy.

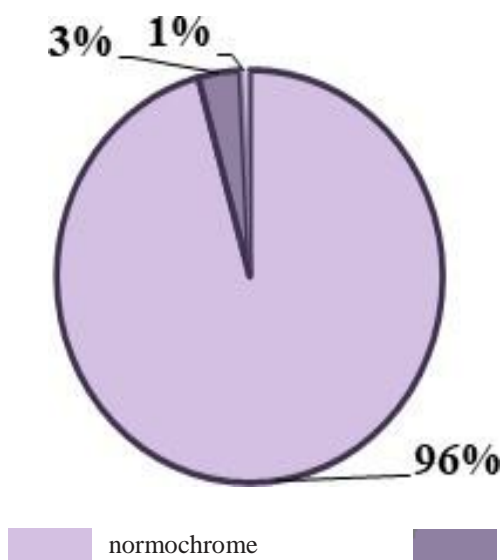
## Methods of Investigation

Experiments were carried out on 12 female outbred white rats weighing 300 $\pm$ 20 g and their offspring (n=12) kept on a standard vivarium diet, subject to the requirements of the European Parliament and Council Directive 2010/63/EU of 22.09.2010 on the protection of animals used for scientific purposes. The control group consisted of pregnant animals (n=6) receiving 0.9% NaCl solution once intramuscularly; the experimental group consisted of rats receiving L-NAME on the 11th day of pregnancy at a dose of 25 mg/kg once intramuscularly (n=6). Brain sampling of rats was performed on the 1st day of postnatal development. After the rats were decapitated, the brain was quickly extracted and pieces of the anterior cortex of the large hemispheres were fixed in Carnois fluid. Serial paraffin sections were prepared and stained with 0.1% toluidine blue according to the Nissl method [2]. Histological preparations were studied, microphotographed, and neuronal morphometry was performed using an Axioscop 2 plus microscope (Zeiss, Germany), a digital video camera (LeicaDFC 320, Germany), and ImageWarp image analysis software (Bitflow, USA). The location of the frontal cortex in histological preparations of rat brains was determined using a stereotactic atlas [9]. At least 30 neurons were evaluated in each animal, and 150 neurons of the fifth cortical layer in each experimental group, which provided a sufficient sample size for subsequent analysis. The neuronal size (mk $\mu$ m<sup>2</sup>), shape change (elongation factor, shape factor) and the degree of cytoplasm chromatophilia (normochromic, hypochromic, hyperchromic and hyperchromic wrinkled) [10]. Statistical processing was performed using non-parametric statistical methods.

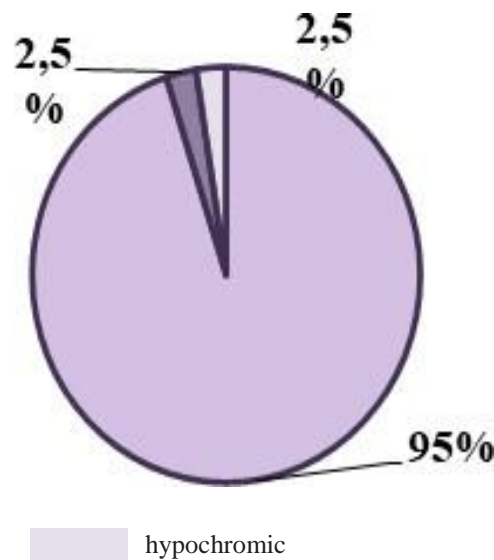
## Results and Discussion

In 1-day-old control rats, the fifth layer of the frontal cortex contained normochromic (96%), hyperchromic (3%) and hypochromic (1%) neurons (Fig. 1).

## Control group



## L-NAME



**Figure 1:** Ratio of neurons with different degrees of cytoplasmic chromatophilia in the fifth layer of the frontal cortex of newborn rats under conditions of N $\omega$ -nitro-L-Arginine Methyl Ester (L-NAME) administration during pregnancy.

In the experimental group rats, along with a decrease in the number of normochromic (by 8%) and hyperchromic neurons (by 33%), there was an increase in the number of hypochromic neurons by 68% ( $p < 0.05$ ).

There was a 49% increase in neuronal size ( $p < 0.05$ ), whereas the shape of neuronal pericaryons did not change ( $p > 0.05$ ), (Table 1).

**Table 1:** Size and shape of pericaryon neurons of the fifth layer of the frontal cortex of newborn rats under conditions of N $\omega$ -nitro-L-Arginine Methyl Ester (L-NAME) administration during pregnancy (Me, LQ; UQ)

Group	1 day
Square, mkm <sup>2</sup>	
Control	26,97 (23,07; 27,62)
L-NAME	40,30 (34,30; 44,20)*
Elongation factor	
Control	1,20 (1,20; 1,24)
L-NAME	1,24 (1,21; 1,30)
Form Factor	
Control	0,84 (0,82; 0,86)
L-NAME	0,87 (0,81; 0,88)

Note: \* -  $p < 0.05$  compared to control

## Conclusions

Thus, the administration of the nonselective NOS inhibitor L-NAME to female rats during placentation period caused morphological abnormalities in the neurons of frontal cortex in newborn rats, which were manifested by an increased cell size

and an increased proportion of hypochromic neurons. This effect of L-NAME administration may be due to a decrease in NO production in the neurons in brain cortex and in the cerebral vascular endothelium with consequent impairment of cerebral circulation and development of oxygen starvation. The observed change in the size of neurons in the form of their increase along with hypochromia may be a consequence of cell swelling caused by energy deficiency with the development of electrolyte imbalance [11, 12].

## References

1. Mary C Moran, Cecelia Mulcahy, Gergely Zombori, John Ryan, Paul Downey, et al. (2015) Placental volume, vasculature and calcification in pregnancies complicated by pre-eclampsia and intra-uterine growth restriction. *Eur J Obstet Gynecol Reprod Biol* 195: 12-17.
2. Merkulov G A (1961) Course of pathohistological technique. *MEDGIZ* 340.
3. Kiseleva NI (2006) Endothelial dysfunction in gestosis: pathogenesis, diagnosis and treatment. *Protection of motherhood and childhood* 7: 49-56.
4. Klimov VA (2008) Endothelium of the fetoplacental complex in the physiological and pathological course of pregnancy. *Obstetrics and gynecology* 2: 10-12.
5. Maija Dambrova, Stefan Chlopicki, Edgars Liepinsh, Olga Kirjanova, Olga Gorshkova, et al. (2004) The methylester of gamma-butyrobetaine, but not gamma-bu tyrobetaine itself, induces muscarinic receptor-dependent vasodilatation. *Naunyn Schmiedeberg's Arch Pharmacol* 369: 533-539.
6. Maksimovich N Ye, ZHurnal GrGMU, Maksimovich NE (2004) The concept of the nitroxidergic system of the brain. *Role extraneuronal sources* 3-5.
7. Maksimovich N Ye, Ponyatie O, ZH-I GrGMU, Maksimovich NE (2003) nitroxidergic system brain. *Role of neuronal sources* 7-11.
8. Herraiz S, Pellicer B, Serra V, Cauli O, Cortijo J, et al. (2012) Sildenafil citrate improves perinatal outcome in fetuses from pre-eclampsicrats. *BJOG* 119: 1394-1402.

9. Paxinos G, Watson C (1998) The Rat Brainstereotaxis coordinates. Academic Press, Australia 242.
10. Bon EI, Maksimovich NE, Zimatkin SM (2019) Morphological changes in the parietal cortex in rats after subtotal cerebral ischemia and after the administration of L-NAME. Vestnik VGMU 1: 14-20.
11. Herraiz S, Pellicer B, Serra V, Cauli O, Cortijo J, et al. (2012) Sildenafil citrate improves perinatal outcome in fetuses from preeclamptic rats. BJOG 119: 1394-1140.
12. Maksimovich N Ye, ZH-I GrGmu NE, Maksimovich (2003) The concept of the nitroxidergic system brain. Role of neuronal sources 4: 7-11.