

The Use of 10% Ambroxol Cream on Musculoskeletal Pain A Case Series

Rosalee E. Gonzales, MD¹, & Francis O. Javier, MD²

¹Principal Investigator; Emergency Medicine, Pain Medicine and Palliative Care; St. Luke's Medical Center-Quezon City, Philippines

²Consultant, Pain Medicine and Palliative Care; St. Luke's Medical Center-Quezon City, Philippines

***Corresponding author:** Rosalee E. Gonzales MD, Principal Investigator; Emergency Medicine, Pain Medicine and Palliative Care; St. Luke's Medical Center-Quezon City, Philippines

Submitted: 13 February 2025 **Accepted:** 17 February 2025 **Published:** 27 February 2025

Citation: Gonzales, R. E., & Javier, F. O. (2025). The Use of 10% Ambroxol Cream on Musculoskeletal Pain A Case Series. *Sci Set J of Med Cli Case Stu*, 4(1), 01-10.

Abstract

Multiple drugs have been available in the treatment of pain. However, despite the availability of pain medications in the market, half of the older population who are taking analgesics still report to suffer from debilitating types of pain. This has led medical practitioners to continuously search for more effective and safe adjuvant analgesics to offer to their patients.

This case series highlights the promising effect of Ambroxol 10% cream both on Somatic, Neuropathic and Nociceptive types of Chronic Pain. It also shows the efficacy of the drug on Acute types of pain in origin. The use of the cream can provide not just relief but also improvement of overall patient function.

Ambroxol, a mucolytic drug has been used to be re-purposed due to its potential usefulness in the treatment of neuropathic pain with blockage of voltage gated sodium channels particularly Nav1.7 and TTX-r 1.8 (Neuropathic and Inflammatory pain.) It has a complex mode of action through its antioxidant & anti-inflammatory properties which may be attributed to its effects in edematous and hyperemic tissues.

All patients in the case series showed immediate decrease in pain within 5 to 15 minutes from the time the cream (10% Ambroxol) was applied. 16 out of 23 patients are also taking co-analgesics weeks to months prior to the application of the cream.

Peak drug effect and maximum pain relief was noted at 120 minutes and lasted a duration of 240-600 minutes, with 1 patient reporting complete resolution with no recurrence of pain. Among the 26 patients, there were no noted side effects upon initial application of the cream. All patients were monitored for a span of 1-2 weeks from the initial time of application and reported varying degree of pain relief. One patient reported decreasing length of efficacy after a few days use of the cream.

Ambroxol 10% cream shows promising effect in both somatic, neuropathic and nociceptive types of Acute and Chronic Pain in origin. Its use provide not just relief but also improvement of overall patient function. This case series however did not show any side effects, hence we recommend more further studies on continuous application of the cream on the same group of patients.

Introduction

Pain can either be acute or chronic. Acute pain is sudden in onset and is usually a response from a noxious stimulus that lasts less than 7 days but may extend up to 30 days [1]. Although treatment of the initial injury tends to result in the resolution of pain, patients suffering from moderate to severe acute pain are at risk to develop chronic pain in the future [2].

Chronic pain on the other hand is described as pain lasting for more than 3 months is a common complaint among the adult population. Approximately 20% of the population do experience chronic pain causing limitation of activities of daily living [3]. This results to patients seeking for the best treatment strategy available.

Multiple drugs have been available in the treatment of pain. This consists of the conventional and adjuvant analgesics. However, despite the availability of pain medications in the market, it has been shown in the study of Nguyen et al., (2020) that half of the older population who are taking analgesics still report to suffer from debilitating types of pain [4]. This has led medical practitioners to continuously search for more effective and safe adjuvant analgesics to offer to their patients [5].

Objectives

1. To present 23 cases of patients coming in the Pain Management Center with both acute and/or chronic types of pain
2. To discuss the pathophysiology and etiology of Acute and Chronic pain
3. To discuss the use of Topical Ambroxol Cream 10% on patients presenting both with acute and chronic pain.

Significance

The persistence of inadequate pain management on patients with both acute and chronic pain has been a common problem [6]. Conventional and adjuvant analgesics have been available for several decades already. Despite this availability, the continuous search for more drugs is being encouraged due to the limited effectiveness and increased side effects observed in patients. The development of novel analgesic is encouraged but sparse due to the labor-intensive process of creating a new drug [7]. In the absence of novel drug production, physicians have found drug repurposing as an effective approach in looking for a new effective analgesic option [8].

Ambroxol is an old drug that has been re-purposed due to its potential usefulness in the treatment of neuropathic pain. Its analgesic mechanisms have been seen to be effective in blocking the tetrodotoxin resistant sodium channel 1.8 which is responsible for neuropathic pain and sodium channel 1.7, a targeted treatment for chronic pain [8].

This case series highlights the promising effect of Ambroxol 10% cream both on Somatic, Neuropathic and Nociceptive types of Chronic Pain. It also shows the efficacy of the drug on Acute types of pain in origin. The use of the cream can provide not just relief but also improvement of overall patient function.

Discussion

In the year 2020, the International Association for the Study of Pain (IASP) has redefined the definition of pain as an unpleasant sensory and emotional experience associated with or resembling that associated with, actual or potential tissue damage. Although

pain is being used as a tool to determine a new pathology or injury, treatment of the disease does not always result to resolution of pain [9].

Research and guidelines implemented for pain management has improved in the past decades. Evidence on effective pain control has been emerging and the World Health Organization (WHO) has been giving updates on the proper use of analgesia [7]. However, despite several journals published, there is still a high prevalence of inadequate pain management in a lot of patients. In the study of Majedi et al (2019), they elaborated that several risk factors are also associated with inadequate pain control. These include age, sex, education and body mass index (BMI) [6]. Analgesics are divided into those conventional and adjuvant analgesics.

Conventional analgesics are medications that are primarily designed to relieve pain, namely: nonsteroidal anti-inflammatory drugs (NSAIDs), acetaminophen and opioids. In contrast, adjuvant analgesics are a diverse group of drugs that were initially developed for a primary indication other than pain however was eventually found to have beneficial analgesic effects. These include antidepressants (Tricyclic Antidepressants, Serotonin Norepinephrine Reuptake Inhibitor, Selective Serotonin Reuptake Inhibitor), anticonvulsants, alpha 2 adrenergic corticosteroids, anesthetics, agents, N-methyl-D-aspartate (NMDA) antagonist, cannabinoids, bisphosphonates and calcitonin, GABA agonist and neuro immunomodulatory agents [5].

The use of adjuvant analgesics improves pain control by decreasing the dose and side effects of conventional analgesics. Another importance on the use of adjuvant analgesic is the decrease use of opioids in order to help with the opioid epidemic in the western country and undersupply in the developing countries.

In the past years, Ambroxol has been used to be re-purposed due to its potential usefulness in the treatment of neuropathic pain. Ambroxol an over-the-counter drug which involves stimulation of surfactant synthesis is currently being used as a mucolytic agent to treat both acute and chronic respiratory diseases [10]. Aside from its respiratory function, Ambroxol has been shown to have a complex mode of action. It acts as an antioxidant through direct scavenging and protects cellular structures from reactive oxygen species. As an anti-inflammatory agent it inhibits the generation of pro-inflammatory mediators. It acts as an anti-bacterial and anti-viral agent by increasing the concentrations of factors [surfactant proteins (SP-A) and immunoglobulins A and G] and suppresses virus multiplication and affect the bacterial biofilm structure and lastly, acts as a local anesthetic [11].

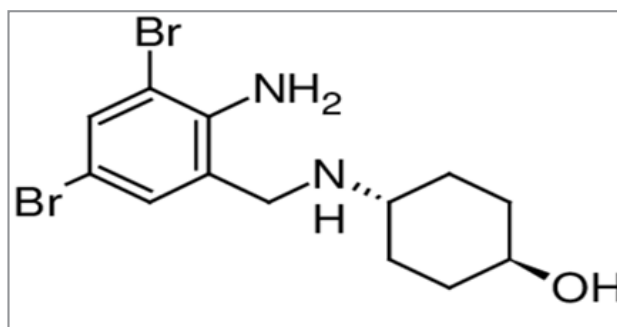


Figure: molecular formula: C₁₃H₁₈Br₂N₂O; IUPAC name: trans-4-(2-Amino-3,5-dibromobenzylamino)-cyclohexanol; typically administered as ambroxol hydrochloride.

Source: Isolation, Identification, and Characterization of One Degradation Product in Ambroxol by HPLC-Hyphenated Techniques

Due to its multiple mechanism of action, Ambroxol is a drug that has been recommended to be repurposed [8]. Several studies have used the topical form of the said drug in the treatment of different sources of neuropathic pain such as fibromyalgia, trigeminal neuralgia, complex regional pain syndrome (5), postherpetic neuralgia, mononeuropathy multiplex, phantom pain, deafferentation pain, post operative neuralgia and foot neuropathy [8, 12, 13, 14]. The primary mechanism involved in the analgesic effect of Ambroxol is the blockage of voltage gated sodium channels particularly Nav 1.8 which is involved in neuropathic and inflammatory pain; Nav 1.7 which is involved in the treatment of chronic pain [8].

These mechanisms function are particularly relevant to neuropathic pain because of Ambroxol's ability to block Nav channels and is structurally similar to known local anesthetic. It is 40 times more potent compared to lidocaine in inhibiting neuronal Nav channels, which in turn leads to a reduction of action potential frequency thus, intraneural signal transduction [15, 14]. There are nine subtypes of Nav channels (1.1 to 1.9). Nav 1.1, 1.2, 1.3, 1.5, and 1.6 are widely distributed in the CNS, whereas Nav 1.7, 1.8 and 1.9 are distributed in the PNS. In addition, Nav 1.1, 1.2, 1.3, 1.4, 1.6 and 1.7 are tetrodotoxin (TTX) sensitive, while Nav 1.5, 1.8 and 1.9 are TTX-resistant [16]. Ambroxol, specifically inhibits TTX-r Nav 1.8 channels, which are expressed in nociceptive sensory neurons. Moreover, Nav 1.8 is insignificantly expressed in both heart and CNS, which may account for the fact that Ambroxol has no notable side effects [17, 18, 15].

Nav 1.8 is expressed in C and A-delta as well as in A-beta fibers, which is associated with its anti-allodynic effects in animal models as well as humans [19, 12-14]. As previously discussed, Ambroxol has a complex mode of action through its antioxidant and anti-inflammatory properties which may be attributed to its effects in edematous and hyperemic tissues. This may explain its benefits in complex regional pain syndrome (CRPS) patients [13].

This case series was done in a span of months January to February of 2024. The authors of the paper used a compounded 10% Ambroxol cream (50g) made from Ambroxol 10 grams + Dimethyl Sulfoxide 5.0g made up to 100 grams with vehicle. The compounding was done by the local pharmacy in the country. Subjects were recruited through convenient sampling. Patients who came in the pain clinic were offered to try the cream. Each participant signed a general informed consent prior to application of the cream. There were no control subjects. The case series had a total of 23 cases presenting with somatic pain of musculoskeletal origin. 4 patients had acute pain while the remaining 19 patients all had chronic pain.

All 23 patients presented with pain characterize as either dull, aching or electric like in character. All of them showed immediate decrease in pain within 5 to 10 minutes from the time the cream (10% Ambroxol) was applied. Together with the decrease in pain, patients also reported a cooling sensation immediately and up to 3 minutes from the time of application. Among the 23 patients, 19 presented with chronic pain of either somatic or neuropathic in origin while 4 patients had an acute type of pain. 5 out of 23 patients are also taking co-analgesics weeks to months prior to the application of the cream. Maximum pain relief was

noted at 120 minutes and lasted a duration of 240-600 minutes. One patient reported pain relief which lasted for 1320 minutes while another patient reported total relief of pain even up to 1 week after follow-up. There were no noted side effects upon initial application of the cream. All patients were monitored for a span of 1-2 weeks from the initial time of application and reported varying degree of pain relief.

Case 1 is a 48-year-old hypertensive, non-diabetic female who came in with 2-month history of right shoulder pain secondary to supraspinatus tendinitis. Pain was described as intermittent, aching in character with numerical rating scale of 3/10. She has been taking Orphenadrine+ Paracetamol 50/650 milligram per tablet every 8 hours and Tramadol 50 milligram per tablet every 8 hours as needed for the pain. No consult or work-up was done to investigate the source of pain. Upon examination, there was tenderness on the bicipital tendon on the right shoulder. The patient applied the Ambroxol 10% cream and had immediate relief of pain from NRS 3 to 0 within 5 minutes from application. Drug effectivity was sustained up until the 360th minute when her pain recurred at numerical rating scale of 2/10. Aside from the pain relief, the patient also reported a cooling sensation 3 minutes from the time the cream was applied. Patient intermittently applied the cream usually after heavy work and noted the same effect even after 2 weeks of use.

Case 2 is a 51-year-old male, hypertensive, non-diabetic who has been with chronic continuous low back and right shoulder pain that is aching and tearing in character with NRS of 10/10 for more than 10 years. Pain is aggravated by shoulder flexion, abduction, and extension. Patient has been diagnosed with chronic pain secondary to supraspinatus tendinosis and partial tear, R Shoulder; Myofascial Pain Syndrome, upper back and has been on daily maintenance medication including Tramadol Retard 100mg, 1 tablet every 8 hours; Tramadol 50mg per capsule, 1 capsule every 4 hours as needed for pain with pain scale of more than equal to 4/10 (Maximum of 2 doses per day); Pregabalin 225 milligrams at 6 AM and 2 PM, 150 milligram at 10 PM; Baclofen 10 milligram every 8 hours; Orphenadrine Citrate + Paracetamol 50/650 milligrams, 1 tablet every 8 hours, Vitamin B Complex, 1 tablet once a day; Lidocaine 50 milligram per gram (5%) patch, 1 patch on right shoulder every 12 hours. Patient has also been on regular physical therapy and underwent 2 cycles of steroid injection and 1 cycle of platelet rich plasma injection on the right shoulder. Despite the medications, patient still complains of pain with NRS of 7/10. On examination, patient had tenderness on palpation of the right shoulder with associated limited range of motion of shoulder flexion and abduction to 60 degrees; shoulder extension of 20 degrees. Upon application of the Ambroxol 10% cream, patient showed decrease in pain of NRS 7 to 5 with associated increase in shoulder flexion and abduction to 100 degrees and shoulder extension to 50 degrees within 5 minutes from the time of the cream application. Further reduction of pain was observed after 60 minutes from application to NRS 3/10. At 240th minutes, patient underwent regular physical therapy which entailed strengthening and stretching of the left right shoulder. He reported an increase in pain scale to NRS 5/10 post physical therapy but also reported that he was able to tolerate therapy better than the previous days. Pain returned to NRS 7/10 after 6 hours from the time of cream application. After the third application of the cream, there was note of decrease in baseline pain to NRS 6/10 to 3/10 every

after-cream application. On the 9th day of application, patient noticed that there was decreasing effect of the ointment that he had to take his rescue doses of medications again. Patient was advised to rest from the ointment for 2 days. On re-application,

Case 3 is a 46-year-old female, hypertensive, diabetic and rheumatoid arthritis s/p 2 cycles of steroid injection of the right shoulder. She presented with a 3-year history of chronic aching and electric like right shoulder pain with NRS 8/10 and is maintained on the following medications: Methotrexate 25 milligrams, 4 tablets every Saturday, Folic Acid 5 milligram once a week, Orphenadrine + Paracetamol 50/650 milligrams/ tablet, 1 tablet as needed for severe pain and is on regular physical therapy. Patient also applies Indomethacin cream three times a day but offers minimal relief. Upon examination, patient has tenderness on right paracervical, trapezius and shoulder joint with associated limited active range of motion of shoulder flexion and abduction to 80 degrees; shoulder extension to 15 degrees. Patient showed decrease in pain of NRS 8 to 4 with increase in active range of motion on the right shoulder flexion and abduction to 120 degrees and shoulder extension to 40 degrees within 5 minutes from the application of the cream. However, 120 minutes from the time of cream application, the pain scale increased to NRS 5/10, which was sustained until 360 minutes prior to return of pain severity to NRS 8/10. Patient continuously applied the cream 3x a day and noted the same effect even after 2 weeks of application.

Case 4 is a 45-year-old female, hypertensive, non-diabetic who presented with intermittent bilateral paracervical pain for the past 2-years. Patient is diagnosed with myofascial pain syndrome and is maintained on Orphenadrine + Paracetamol 50/650 milligram per tablet as needed for severe pain. On examination, there is noted limitation of motion on cervical lateral flexion and rotation with tenderness and palpable taut bands on bilateral paracervical area. The patient applied the cream and reported decrease of pain from NRS 5 to 4 within 5 minutes from the time of application. Further decrease in pain to NRS 3 was observed 60 minutes after. The medication efficacy was sustained for 420 minutes from the time of application. Patient continuously applied the cream as needed for the pain and noted improvement from baseline pain to NRS 2 after the 3rd application. Patient was able to stop her as needed oral pain medication while using the cream.

Case 5 is a 40-year-old female, non-hypertensive, non-diabetic who presented with continuous, aching type of pain NRS 8/10 in the left parathoracic area for the past year. Patient is diagnosed with myofascial pain syndrome and is maintained on Tramadol 50 milligrams every 8 hours and Orphenadrine + Paracetamol 50/650 milligram per tablet as needed for the pain. Patient is also on regular physical therapy and underwent dry needling several times. On examination there was noted tenderness and palpable taut band on the left parathoracic area. Upon application of the cream, the patient reported decrease of pain from NRS 8 to 6 within 5 minutes and further reduction to NRS 4 within 30 minutes from the time of the cream application. The medication efficacy was sustained for 480 minutes from the time of application. Subsequent application noted the same effect after 2 weeks from the initial intervention.

Case 6 is a 40-year-old female, non-hypertensive, non-diabetic and known case of chronic supraspinatus tendinosis of the left

shoulder for the past 2 years. She presented with continuous, dull, and aching type of pain on the left shoulder NRS 6-7/10 aggravated by shoulder rotations. The patient is taking Paracetamol as needed for moderate to severe pain. Upon examination, there noted tenderness on the left shoulder but no limitation on active range of motion. minutes from the cream application, the patient observed a decrease of pain from NRS 6 to 3 which was sustained for 360 minutes from the initial application. No repeat application was done.

Case 7 is a 37- year- old female, non-hypertensive, non-diabetic with a 2-year history of plantar fasciitis, bilateral foot. The patient described the pain as continuous, throbbing and stretching in character NRS 7-8/10 at worst aggravated by walking. The patient is not on any medications but undergoes regular physical therapy and massage which temporarily relieved the pain to NRS 4/10. Upon seeing the patient, pain was at NRS 4/10 on bilateral sole of foot. Upon examination, there was noted tenderness on bilateral heel. 10 minutes from the time of the cream application, pain was decreased to NRS 0 on both feet. Pain on the right foot was sustained to 0 until more than 2 weeks while the one on the left foot returned to NRS 6/10 after 480th minutes from the time of application. The patient re applied the cream 2 more times on the left foot with 8 hours interval and reported continuous decrease in baseline pain scale to NRS 2/10. After the 3rd application on the left foot, the patient reported complete pain relief for 72 hours. When pain on the left foot recurred, the duration was now intermittent and less severe at NRS 5-6/10. Patient reapplied the cream one more time and pain decreased to 0/10, 15 minutes upon reapplication of the cream. The patient remained pain free on the left foot for more than 72 hours from the last application. Musculoskeletal ultrasound was done pre and 3 days post application of the cream which showed decrease in size of the right plantar fascia from 4cm to 2.9cm and left plantar fascia from 5.6 to 4.8 cm.

Case 8 is a 37 M, hypertensive, diabetic, obese class II and diagnosed with fallen arch of the right foot for the past 3 weeks. The patient described the pain as continuous, aching in character with NRS 5-6/10 aggravated by walking and minimally relieved by intake of Etoricoxib 90 milligram once a day with Eperisone 50 milligram every 8 hours, both prescribed by orthopedic doctor to be taken for 3 days. Upon examination, patient had antalgic gait and there was note flat foot on bilateral feet and valgus deformity on bilateral knee. There was note of tenderness on the right mid plantar foot. Patient applied the cream and noted decrease in pain scale from NRS 5 to 1 within 5 minutes from the time of cream application. Pain however increased to NRS 2 on the second hour but was maintained until the 360th minutes. Patient reapplied the cream 3x a day for 5 days together with the other analgesics which were taken for 3 days and noted complete resolution of the pain after.

Case 9 is a 34-year-old male with no known comorbidities, case of 1 week history of right ankle sprain. He described his pain as intermittent, aching in character of NRS 5/10 aggravated by walking. Upon examination, patient had no gait deformity but there was note of tenderness on the lateral calcaneofibular ligament area. Patient was taking etoricoxib which provides partial relief. Upon application of the cream, patient noted decrease in pain from NRS 5 to 2 within 5 to 10 minutes of application. The effectivity was observed for a span of 360-420 minutes. On repeat application, patient reported the same decrease in pain scale.

Case 10 is a 58-year-old female, known case of seronegative rheumatoid arthritis and fibromyalgia for the past 2 years. Patient works as a housewife who does baking at times. She complains of multiple joint and leg pains. The patient's condition does not allow her to bake and limits chores such as ironing clothes. She is maintained on Methotrexate 25 milligram, 5 tablets every Saturday, Folic Acid, Pregabalin 75 milligram, ½ tablet in the morning and 1 tablet at night and Orphenadrine + Paracetamol 50/650 milligram, 1 tablet every 8 hours as needed for pain. Upon examination, patient presents with tenderness on multiple joints and bilateral leg with limited rotational movements of the wrist, shoulders and ankle secondary to pain. Patient applied the cream and noted improvement of pain from NRS 6 to 4 then to 3 within the first hour. The effect was sustained for 4 hours prior to recurrence of pain and patient was able to go back to previous activities of specifically ironing of clothes and baking. Patient applied the cream 3x a day for 2 weeks and noted the same effect during the 2 weeks observation period.

Case 11 is a 68 year-old female, non-hypertensive, non-diabetic, known case of Chronic low back pain with sciatica right more than the left secondary to spinal stenosis, Degenerative disc disease, Herniated Nucleus Pulposus, Facet Arthrosis L3, L4, L5-S1, s/p Posterior decompression laminectomy with application of interspinous implant; Chronic Left shoulder pain s/p arthroscopic rotator cuff repair with biceps tendinosis, subacromial decompression, partial bursectomy synovectomy, L shoulder for the past 5 years. Patient is maintained on Morphine sulfate plain 60 milligrams every 8 hours, Rescue dose of Morphine Sulfate Plain 30 milligrams every 2 hours as needed for pain scale \geq 4/10. Pregabalin 150 milligrams during 6AM and 2PM while 200 milligrams at 10 PM. Eperisone 50 milligrams every 12 hours, Baclofen 10 milligrams, ½ tablet every 12 hours. Despite the medications, patient still complains of continuous pain on the left shoulder with NRS 8/10 on movement and pain on low back and bilateral knees of NRS 6/10 aggravated by shoulder movement and partially relieved by intake of maintenance medications. She would take approximately 3 rescue doses per day. This limits patient in doing her activities of daily living such as changing clothes and combing of hair. Upon examination, patient had antalgic gait, limited L shoulder flexion and abduction to 90 degrees, shoulder extension to 20 degrees. Patient also had difficulty doing hip flexion and extension. 10 minutes from the application of the cream, patient noted significant decrease in pain from NRS 8 to 4 on the left shoulder and NRS 6 to 3 on the back and bilateral knees. Maximum effectivity was observed at 120 minutes when pain on L shoulder decreased to NRS 2 while NRS 1 for low back and bilateral knees. Patient was able to comb her hair without difficulty and was able to do lumbar flexion and extension with less difficulty. Patient was able to skip her rescue doses, was able to sleep overnight and reported return of pain to baseline after 510 minutes. Repeat application showed similar efficacy.

Case 12 is a 51-year-old female, hypertensive and known case of osteoarthritis of the left knee for the past 2 years. Patient has been complaining of continuous left knee pain with NRS 8/10 aggravated by ambulation and knee flexion. Patient was previously maintained on Orphenadrine + Paracetamol 50/650 milligrams however due to minimal improvement, patient stopped intake of medication. Upon examination, patient is unable to bend her L knee and walks with antalgic gait described as dragging of the left lower extremity. 5 minutes from the time of the

cream application, pain decreased to NRS 0, there was noted improved knee flexion to 90 degrees and was able to ambulate without dragging the affected leg. After 120 minutes, there was noted recurrence of pain of NRS 1-2/10 which lasted until 480 minutes when the patient reported transient recurrence of pain of NRS 8/10 for 30 minutes. No reapplication of cream was done but pain decreased to 0/10 again for 24 hours prior to recurrence of pain. Upon return of pain, patient noted that pain became intermittent with baseline NRS of 4/10 compared to previous pain of continuous in duration. For 2 weeks, patient did not reapply the cream and there was no observed increase in pain severity from NRS 4/10.

Case 13 is a 50-year-old male, hypertensive, diabetic, known case of the right knee osteoarthritis for the past year. Patient has been having continuous right knee pain with NRS 7/10 aggravated by cold weather, ambulation, and knee flexion. Patient is maintained on Tramadol + Paracetamol 37.5/325 milligrams/ tablet, 1 tablet 2x a day as prescribed by the orthopedic doctor. Patient is also maintained on regular physical therapy of the right knee. Upon examination, patient had antalgic gait, extension lag on active range of motion and limited knee flexion to 20 degrees. 10 minutes from the time of cream application, pain decreased to NRS 7 to 3, and the patient was able to do active knee flexion up to 90 degrees. There was still note of extension lag, but the patient was able to ambulate with less difficulty. Maximal efficacy was observed at 150 minutes and lasted for 420 minutes. Subsequent application showed similar results.

Case 14 is a 37-year-old male, non-hypertensive, non-diabetic, case of degenerative osteoarthritis on the right knee. Patient has been complaining of intermittent right knee pain for the past 6 months of NRS 6/10 aggravated by ambulation. Patient has been taking Tramadol 50 milligrams/ tablet, 1 tablet as needed for severe pain and is on regular physical therapy 3x a week. Upon examination, patient walks with antalgic gait and is unable to bend his right knee beyond 10 degrees due to pain. 5 minutes from the time of cream application, pain decreased to NRS 6 to 0 and the patient was able to do active knee flexion up to 80 degrees. The patient was able to ambulate with less difficulty and less limp. The patient remained pain free until 600 minutes before recurrence of pain to NRS 6. Subsequent application showed similar results with decreasing baseline pain to NRS 3/10.

Case 15 is a 37-year-old female, non-hypertensive, non-diabetic who works as a janitor. Patient has been complaining of intermittent right parathoracic pain NRS 5/10 for the past 4 months. This is aggravated during mopping the floor. No medications taken and no consult done. Upon examination there was no deformity and no limitation of scapular or shoulder range of motion but there was note of tenderness on the right interscapular area. 5 minutes from the time of cream application, pain decreased from NRS 5 to 0 with associated resolution of tenderness. This was sustained until ___ minutes prior to recurrence of pain now with baseline NRS of...

Case 16 is a 56-year-old female, hypertensive and case of frozen shoulder of the right shoulder for the past 12 months. Patient has been complaining of right shoulder stiffness and pain NRS 6/10 aggravated by shoulder rotation. Patient is unable to do some basic activities of daily living such as hooking of her undergarments from the back. Patient is taking Orphenadrine + Paracetamol 50/650 milligram/ tablet, 1 tablet every 8 hours as

needed for severe pain. Upon examination there is limited shoulder abduction and flexion to 110 degrees and shoulder extension to 30 degrees. There is also tenderness on posterior glenohumeral joint. 5 minutes from the time of cream application, pain decreased from NRS 6 to 0 with associated resolution of tenderness and improvement of active range of motion of shoulder flexion and abduction to 160 degrees. Patient was able to reach the lock of her undergarment from the back. Pain relief was sustained until 240 minutes prior to recurrence of pain to NRS 2/10 then until 420 minutes prior to recurrence of pain to NRS 6/10.

Case 17 is a 55-year-old male, non-hypertensive, non-diabetic with history of supraspinatus tendinosis for the past 4 months. Patient has been complaining of intermittent right shoulder pain NRS 7/10 aggravated by shoulder rotations. Patient is not taking any medication but is undergoing regular physical therapy 3x a week and underwent platelet rich plasma injection 4 weeks prior. Upon examination, there is limited range of motion of right shoulder flexion and abduction to 90 degrees only. There is also tenderness on the supraspinatus tendon area. 10 minutes from the time of cream application, pain decreased from NRS 7 to 3 with associated resolution of tenderness and improvement of active range of motion of shoulder flexion and abduction to 180 degrees. Pain relief was sustained until 240 minutes prior to recurrence of pain to NRS 2/10 then until 420 minutes prior to recurrence of pain to NRS 6/10

Case 18 is a 72-year-old female, hypertensive, diabetic, case of frozen shoulder, right secondary to previous shoulder dislocation 2 years ago. Post dislocation, patient had continuous pain on the right shoulder with associated dull, aching like pain NRS 8/10 aggravated by shoulder rotation. There was also noted stiffness on the right shoulder which limits the movement. No maintenance medications taken however patient does regular physical therapy 3x a week. Upon examination there is limited range of motion of right shoulder flexion and abduction to 70 degrees only with no noted tenderness on the shoulder. 5 minutes from the time of cream application, pain decreased from NRS 6 to 2 with associated improvement of active range of motion of shoulder flexion and abduction to 110 degrees. Pain relief was sustained until 120 minutes prior to recurrence of pain to NRS 3/10 then until 480 minutes prior to recurrence of pain to NRS 5/10. Patient used the cream prior to every therapy for the first 2 weeks which makes her tolerate the therapy better.

Case 19 is a 25-year-old male, hypertensive, nondiabetic, case of 3 days history of acute left knee stain on valgus direction. He is complaining of continuous pain on the left knee, aching in character, aggravated by movement with NRS 10/10. Upon examination, there was note of swelling and tenderness on the medial aspect of left knee with limited knee flexion to 20 degrees and extension lag during active assisted range of motion. Patient has been taking Etoricoxib for the past 24 hours. 5 minutes upon application of the cream, there was note of improvement of pain from NRS 10 to 6. Patient was also able to bend the knee to 90-degree flexion and full knee extension using active range of motion.

Case 20 is a 60-year-old-male, non-hypertensive, non-diabetic, case of post herpetic neuralgia for the past 3 months. He has been complaining of chronic, intermittent, sharp and electric like

pain on the bilateral chest T8-T9 level. Pain would disappear at times but would have attacks with pain scale NRS 10/10 at any time of the day. Upon examination, there are no noted lesions but with allodynia on the affected area. 5 minutes from the time of application, there was note of improvement of pain scale from NRS 9 to 2. Pain relief was sustained until 120 minutes prior to recurrence of pain to NRS 7-9/10 again. Reapplication noted similar results.

Case 21 is a 34-year-old male, non-hypertensive, non-diabetic, case of 2 weeks history of cough. He was assessed to have community acquired pneumonia- low risk. He also developed right 5th intercostal intermittent sharp, shooting, chest pain NRS 8/10 aggravated by coughing. Upon examination, the patient was seen splinting on the right chest when coughing and noted direct tenderness on the 5th Intercostal space anterior axillary line, crackles on the right lung base and rhonchi on the right upper and mid lung. 5 minutes from the time of application, there was note of resolution of tenderness and decrease of pain scale to NRS 2/10 during coughing. The patient was prescribed with medications for pneumonia (Antibiotics, mucolytic and leukotriene inhibitor) and was advised to apply the cream 3x a day for 5 days. On the third day of application, there was note of resolution of pain with continuous improvement of symptoms. 1 week after, on follow-up, patient fully recovered from his illness.

Case 22 is a 45-year-old male, non-hypertensive, non-diabetic, case of 4 months history of plantar fasciitis on the left heel. He has been complaining of chronic, intermittent, sharp and tearing like pain on the left heel with NRS 8/10. Pain is aggravated by walking and relieved by rest. would disappear at times but would have attacks with pain scale NRS 10/10 at any time of the day. Upon examination, is noted tenderness on the lateral aspect of the left heel on palpation. There was no redness or swelling on the said area. 5 minutes from the time of application, there was note of improvement of pain scale from NRS 8 to 4. Pain relief was sustained until 600 minutes prior to recurrence of pain to NRS 8/10 again. Reapplication for the span of 2 weeks noted similar results.

Case 23 is a 58-year-old female, hypertensive, diabetic, chronic kidney disease stage V patient with non-healing wound on the left antero-medial leg first the past 5 months. Pain has been described as stinging, sharp and tearing in character and is aggravated by movement. Patient has been going through regular wound debridement every week and is maintained on Tramadol + Paracetamol 37.5/325 milligram every 8 hours, Tramadol + Paracetamol 18.75 +165 milligram every 4 hours as needed for breakthrough pain and Pregabalin 25 milligram every 12 hours. Upon examination, is noted 5x5 cm moist, erythematous, granulated wound on the anterior leg. The Ambroxol cream was applied on the proximal circumferential area and posterolateral aspect of the wound. 10 minutes from the time of application, there was note of improvement of pain scale from NRS 8 to 4. Pain relief was sustained until 240 minutes prior to recurrence of pain to NRS 8/10 again. Reapplication for the span of 2 weeks noted similar results.

Below shows a table with the summary of the patient profile and the duration of action of the Ambroxol 10% cream that was observed in the said patients.

Patient		Source of Pain	Area of Application	Medication Time of Onset	Numerical Rating Scale (NRS) after 5 minutes from application	NRS at 120 minutes from the time of application	NRS at 180 minutes from the time of application	NRS at 240 minutes from the time of application	NRS at 360 or more minutes from the time if application	Other ongoing treatment modalities
1 (E.E)	2 months tendinitis	Right Shoulder	5x5 cm	5 minutes	NRS 3 to 0	NRS 0	NRS 0	NRS 0	NRS 2 at 360 minutes	Paracetamol and Tramadol
2 (R.F)	10 years Partial tear supraspinatus	Right shoulder	5x5 cm	5 minutes	NRS 7 to 5	NRS 3	NRS 3	NRS 5 (post physical therapy which included stretching and strengthening)	NRS 7 at 360 minutes	Pregabalin, Orphenadrine, Paracetamol, Tramadol, Lidocaine patch 5%, Baclofen and Vitamin B Complex
3 (M.D)	3 years Rheumatoid arthritis	Right shoulder	5x5 cm	5 minutes	NRS 8 to 4	NRS 5	NRS 5	NRS 5	NRS 8 at 360 minutes	Indomethacin cream, Naproxen, Paracetamol s/p steroid injection on R shoulder x2
4 (E.C.)	2 years MPS	Bilateral paracervical area	3x3 cm	5 minutes	NRS 5 to 4	NRS 3	NRS 3	NRS 3	NRS 5 at 420 minutes	Orphenadrine + Paracetamol
5 (V.E)	1 year MPS	Left Parathoracic Area	3x3 cm	5 minutes	NRS 8 to 6	NRS 4	NRS 4	NRS 4	NRS 4 at 480 minutes	Tramadol, Orphenadrine +Paracetamol
6 (E.M)	2 years Supraspinatus tendinosis	Left Shoulder	3x3 cm	5 minutes	NRS 6 to 4	NRS 3	NRS 3	NRS 5	NRS 5 at the 360 minutes	None
7 (E.S) 37 F	2 years Plantar fasciitis	Bilateral Plantar pain	3x3 cm on Bilateral heel	5 minutes	NRS 4 to 0	NRS 0	NRS 0	NRS 2-3 (L foot) NRS 0 (R Foot)	NRS 6 (L Foot) at the 480th minutes NRS 0 @ Foot	Patient refuses to take oral medications for the past 2 years
8 (C.A) 37 M	3 weeks Fallen Arch	Right Plantar Pain	3x3 cm	5 minutes	NRS 5 to 1	NRS 2	NRS 2	NRS2	NRS 5 at 360 minutes	Eperisone, Etoricoxib
9 (C.H.) 34 M	1 week Ankle sprain	Right lateral ankle	2x2 cm	5-10 minutes	NRS 5 to 2	NRS 2	NRS 2	NRS 2	NRS 5	Etoricoxib
10 (L.M.) 58 F	2 years Rheumatoid arthritis and fibromyalgia	Foot, Leg, Knee, Upper extremity	3x3 cm per area	10 minutes	NRS 6 to 4	NRS 3	NRS2	NRS 6	NRS 6	Methotrexate 5 tabs Once a week, Folic Acid Norgescic Forte PRN Pregabalin 37 mg AM, 75 mg PM
11 (Y.W) 68 F	11 years Chronic low back pain with sciatica right more than the left secondary to spinal stenosis, Degenerative disc disease, Herniated Nucleus Pulposus, Facet Arthrosis L3, L4, L5-S1, s/p Posterior decompression laminectomy with application of interspinous implant; Chronic Left shoulder pain s/p arthroscopic rotator cuff repair with biceps tendinosis, subacromial decompression, partial bursectomy synovectomy, L shoulder	L shoulder, Back, Bilateral knees	Several areas	10 minutes	NRS 8 to 4 (L shoulder) NRS 6 to 3 (Back and bilateral knees)		NRS 2 (L shoulder) NRS 1 (Back and bilateral knees)		NRS 2 (L shoulder) NRS 1 (Back and bilateral knees)	Morphine Sulfate Plain, Pregabalin, Baclofen, Eperisone

12 (J.E.) 51 F	2 years Osteoarthritis	L knee	3x3 cm	5 minutes	NRS 8 to 0	NRS 1-2	NRS 1-2	NRS 1-2	NRS 8 at 360th minutes transiently (30 minutes). No reapplication done but became pain free for approximately 24 hours.	None
13 (L.C.) 50M	1 year Osteoarthritis	R Knee	4x4 cm	10 minutes	NRS 7 to 3	NRS 3	NRS 1	NRS 1	NRS 8 at 420 minutes	Tramadol + Paracetamol BID
14 (R.H.) 34 M	6 months Osteoarthritis	R Knee	4x4 cm	5 minutes	NRS 6 to 0	NRS 0	NRS 0	NRS 0	NRS 6 at 600 minutes	None
15 (M.U.) 37 F	3 months MPS	® Parathoracic	4x4 cm	5 minutes	NRS 7 to 0	NRS 0	NRS 0	NRS 0	NRS 5 at 1320 minutes	None
16 (A.B.) 56 F	12 months Frozen shoulder	R shoulder pain	5x5 cm	5 minutes	NRS 6-0	NRS 0	NRS 2	NRS 2	NRS 6 at 420 minutes	Orphenadrine + Paracetamol
17 (B.F.) 50 M	4 months Supraspinatus tendinosis	R shoulder pain	5x5 cm	10 minutes	NRS 7 to 3	NRS 3	NRS 3	NRS 7	-	None s/p PRP of R shoulder with regular physical therapy
18 72 F	2 years R shoulder	® Shoulder pain	4x4 cm	5 minutes	NRS 6 to 2	NRS 2	NRS 3	NRS 3	NRS 6 at 480 minutes	None
19 Left knee strain on valgus direction	3 days Knee strain	Left knee with limited knee flexion to 20 degrees and extension lag during active assisted ROM (Acute continuous)	3x3 cm	5 minutes	NRS 10 to 6	NRS 6	NRS 6	NRS8	NRS8	Celecoxib
20 60 M (R.C.)	1 year Post herpetic neuralgia	Bilateral chest T8 to T9 level	2x2 cm	5 minutes	NRS 9 to 2	NRS 2	NRS 7	-	-	Pregabalin 75 mg in the morning and noon; 150 mg milligram at bedtime. Tramadol retard 100mg every 12 hours
21 34 M (R.Y.)	2 weeks Costochondritis	Right 5th intercostal space anterior axillary line	2x2 cm	5 minutes	NRS 8 to 2	NRS 2	NRS 2	NRS 6	NRS 8	Paracetamol
22 41 M (A.A)	4 weeks Plantar fasciitis	Left heel	3x3 cm	5 minutes	NRS 6 to 2 and was able to ambulate	NRS 1	NRS 1	NRS 1	NRS 6 at 600 minutes	None
23 58 F (M.C)	5 months Non healing wound	Left anterior leg	5x5 cm posterior to the wound and circumferential proximal to the wound	10	NRS 8-4	NRS 4	NRS 4	NRS 8	-	Tramadol + Paracetamol 37.5/325 mg every 8 hours; Tramadol + Paracetamol 18.75 +165 mg q4 PRN, Pregabalin 25 mg q12

24 44 M	Chronic generalized eczema	Left upper extremity (within 1 week)	FIG	FIG	FIG	FIG	FIG	FIG	FIG	Multiple steroid use
25 37 F	Stasis Dermatitis	Right anterior leg	FIG	FIG	FIG	FIG	FIG	FIG	FIG	
26 38 F	Scald Burn	Bilateral Leg (day 1-3)	FIG	FIG	FIG	FIG	FIG	FIG	FIG	Flammazine on bullae area Ambroxol on area with no bullae
27 10 year old male	eczema	7 days	FIG	FIG	FIG	FIG	FIG	FIG	FIG	
28 85 F (shih)	Rheumatoid Arthritis	>10 years	Bilateral ankle and knee	10 minutes	NRS 9-7	6	6	7	9	Methotrexate, Hydroxychloroquine, Prednisone
29 34 M	Lateral epicondylitis	3 weeks	Right lateral elbow	5 minutes	NRS 4-0	0	0	0	4	None
30 40 F	Primary Dysmenorrhea	1 day	Hypogastric area	5 minutes	NRS 9-3	3	3	8	8	Norgesic Forte and Mefenamic Acid
31 59 M	Small cell neuroendocrine tumor of bladder and prostate	1 year	Right gluteal area and right lower extremity break through pains	5 minutes	NRS 8-4	4	4	4	6	Fentanyl, Abstral, baclofen, pregabalin, norgesic forte
32 65 F	Endometrial CA	1 year	Low back area	10-15 minutes	NRS 7-8	0	0	Used as Rescue dose for break through pains		Fentanyl PCA
33 60 F	Melanoma	4 years	L leg	7 minutes	NRS 10- 0					

Conclusion

In conclusion, Ambroxol 10% cream shows promising effect on both Somatic, Neuropathic and Nociceptive types of Acute and Chronic Pain in origin. Its use provide not just relief but also improvement of overall patient function. This case series however did not show any side effects, hence we recommend more further studies on continuous application of the cream on the same group of patients.

References

1. Chou, R., Wagner, J., Ahmed, A. Y., Blazina, I., Brodt, E., & Skelly, A. C. (2020). Treatments for Acute Pain: A Systematic Review. Agency for Healthcare Research and Quality (US). <https://pubmed.ncbi.nlm.nih.gov/33411426/>
2. Bonezzi, C., Fornasari, D., Cricelli, C., Magni, A., & Ventriglia, G. (2020). Not All Pain is Created Equal: Basic Definitions and Diagnostic Work-Up. *Pain and therapy*, 9(Suppl 1), 1–15. <https://doi.org/10.1007/s40122-020-00217-w>
3. S, M. Rikard., Andrea, E. Strahan., Kristine, M. Schmit., & Gery, P. Guy. (2023). Chronic Pain Among Adults — United States, 2019–2021. *Morbidity and Mortality Weekly Report*, 72(15): 379–385 <https://www.cdc.gov/mmwr/volumes/72/wr/pdfs/mm7215a1-H.pdf>
4. Nguyen, T. N. M., Laetsch, D. C., Chen, L. J., Haefeli, W. E., Meid, A. D., & Schöttker, B. (2020). Pain severity and analgesics use in the community-dwelling older population: a drug utilization study from Germany. *European journal of clinical pharmacology*, 76(12), 1695–1707. <https://doi.org/10.1007/s00228-020-02954-5>
5. Nwosu, A. D. G., Chukwu, L. C., Onwuasoigwe, O., Nweze, S. O., & Nwadike, K. (2023). Redefining the Role of Analgesic Adjuvants in Pain Management: A Narrative Review. *Indian Journal of Pain*, 37(2): 65. https://doi.org/10.4103/ijpn.ijpn_23_22
6. Majedi, H., Dehghani, S. S., Soleyman-Jahi, S., Tafakhori, A., Emami, S. A., & Hosseini, S. M. (2019). Assessment of Factors Predicting Inadequate Pain Management in Chronic Pain Patients. *Anesthesiology and pain medicine*, 9(6), e97229. <https://doi.org/10.5812/aapm.97229>
7. Anekar, A. A., Hendrix, J. M., & Cascella, M. (2023). WHO Analgesic Ladder. In *StatPearls*. StatPearls Publishing. <https://pubmed.ncbi.nlm.nih.gov/32119322/>
8. Russo, M. A., Baron, R., Dickenson, A. H., Kern, K. U., & Santarelli, D. M. (2023). Ambroxol for neuropathic pain: hiding in plain sight? *Pain*, 164(1), 3–13. <https://doi.org/10.1097/j.pain.0000000000002693>
9. Definitions of chronic pain syndromes. (2022). International Association for the Study of Pain (IASP). <https://www.iasp-pain.org/advocacy/definitions-of-chronic-pain-syndromes/>
10. Kantar, A., Klimek, L., Cazan, D., Sperl, A., Sent, U., & Mesquita, M. (2020). An overview of efficacy and safety of ambroxol for the treatment of acute and chronic respiratory diseases with a special regard to children. *Multidisciplinary respiratory medicine*, 15(1), 511. <https://doi.org/10.4081/mrm.2020.511>
11. Cazan, D., Klimek, L., Sperl, A., Plomer, M., & Kölsch, S. (2018). Safety of ambroxol in the treatment of airway diseases in adult patients. *Expert opinion on drug safety*, 17(12), 1211–1224. <https://doi.org/10.1080/14740338.2018.1533954>
12. Kern, K. U., Schwickert-Nieswandt, M., Maihöfner, C., & Gaul, C. (2019). Topical Ambroxol 20% for the Treatment of Classical Trigeminal Neuralgia - A New Option? Initial Clinical Case Observations. *Headache*, 59(3), 418–429. <https://doi.org/10.1111/head.13475>
13. Maihöfner, C., Schneider, S., Bialas, P., Gockel, H., Beer, K. G., & Kern, K. U. (2018). Successful treatment of complex regional pain syndrome with topical ambroxol: a case series. *Pain management*, 8(6), 427–436. <https://doi.org/10.2217/pmt-2018-0048>
14. Kern, K., & Weiser, T. (2015). Topical ambroxol for the treatment of neuropathic pain. *Der Schmerz*, 29(S3), 89–96. <https://doi.org/10.1007/s00482-015-0060-y>
15. Weiser T. (2006). Comparison of the effects of four Na⁺ channel analgesics on TTX-resistant Na⁺ currents in rat sensory neurons and recombinant Nav1.2 channels. *Neuroscience letters*, 395(3), 179–184. <https://doi.org/10.1016/j.neulet.2005.10.058>
16. Wang, J., Ou, S. W., & Wang, Y. J. (2017). Distribution and function of voltage-gated sodium channels in the nervous system. *Channels (Austin, Tex.)*, 11(6), 534–554. <https://doi.org/10.1080/19336950.2017.1380758>
17. Zhao, P., Barr, T. P., Hou, Q., Dib-Hajj, S. D., Black, J. A., & Waxman, S. G. (2008). Voltage-gated sodium channel expression in rat and human epidermal keratinocytes: evidence for a role in pain. *Pain*, 139(1), 90–105. <https://doi.org/10.1016/j.pain.2008.03.016>
18. Akopian, A. N., Sivilotti, L., & Wood, J. N. (1996). A tetrodotoxin-resistant voltage-gated sodium channel expressed by sensory neurons. *Nature*, 379(6562), 257–262. <https://doi.org/10.1038/379257a0>
19. Gaida, W., Klinder, K., Arndt, K., & Weiser, T. (2005). Ambroxol, a Nav1.8-preferring Na⁺ channel blocker, effectively suppresses pain symptoms in animal models of chronic, neuropathic and inflammatory pain. *Neuropharmacology*, 49(8), 1220–1227. <https://doi.org/10.1016/j.neuropharm.2005.08.004>