

Overall Survival and Local Control of Hepatic Metastatic Lesions Treated with Stereotactic Body Radiotherapy

Figón Muñoz Crhys Erendira^{1*}, Lozaon Ruíz Francisco Javier², and Poitevin Chacón María Adela³

¹Resident, Radiotherapy, UMAE 25

²Radiation Oncologist, Radiotherapy, INCAN

³Radiation Oncologist, Radiotherapy, Medica Sur

*Corresponding author: Figón Muñoz Crhys Erendira, Resident, Radiotherapy, UMAE 25.

Submitted: 29 April 2024 Accepted: 03 May 2024 Published: 27 May 2024

doi <https://doi.org/10.63620/MKSSJR.2024.1006>

Citation: Figón Muñoz, C., Lozaon Ruíz, F. J., & Poitevin Chacón, M. A. (2024). Overall survival and local control of hepatic metastatic lesions treated with stereotactic body radiotherapy. *Sci Set Journal of Radiology*, 1(2), 01-03.

Abstract

Background: Although surgery remains the standard of treatment, Stereotactic Body Radiotherapy (SBRT) is an effective and safe alternative for the management of liver oligometastases. However, it is a technique that is little available in Mexico and requires strict patient selection.

Objective: Determine the local control (LC) and overall survival (OS) rate in patients treated with hepatic SBRT from 2017 to 2022.

Methods: A retrospective review was performed from January 2017 to August 2022 of the 68 SBRT cases identified. Eleven patients were included in the analysis with: 1-5 metastases, unresectable, maximum diameter of 6 cm in single lesion or ≤ 10 cm in combination, oligometastatic or oligo progressive disease, adequate liver function (Child Pugh A-B), life expectancy > 6 months and KPS 80-100.

Results: 11 patients with 19 hepatic metastases were included, with an average age of 66 years old. Median follow-up was 13 months. The mean number of lesions per patient was 2 (1-3) with a mean PTV of 45.5cc. The most commonly used scheme was 50 Gy in 5 sessions of 10 Gy each, with a median BED of 87.3 Gy. OS at 1 and 2 years was 75%. LC at 1 and 2 years was 83% and 42%, respectively.

Keywords: Radiotherapy, Stereotactic body radiation therapy (SBRT), Overall Survival (OS), Local Control (LC)

Background

Stereotactic body radiation therapy (SBRT) is a treatment modality for metastatic liver lesions, with a high degree of precision, which uses high doses of ionizing radiation generating ablation due to necrosis of the radiated tissue, with severe vascular endothelial damage, tumor hypoperfusion and hypoxia [1, 2], leading to apoptosis. A high dose per fraction can damage radioresistant stem cells. There are also immunostimulatory effects that result in immunogenic death. Massive release of tumor antigens causes cytotoxic T cell presentation through dendritic cells and results in activation of the CD8 T cell-mediated anti-tumor response. The high precision of this technique allows for reduced margins by minimizing dose to nearby critical normal tissues and dose escalation for better responses.

Surgery remains the standard of care for malignant liver lesions with a 5-year survival rate of 30 to 60%. However, only 0 to 20% of these patients can be operated on for comorbidities, inadequate hepatic functional reserve, uncontrolled primary tumor, lesion location, tumor contiguity to vessels, extrahepatic disease [3].

SBRT is an effective and safe alternative for the management of liver oligometastases [4]. However, it is a technique that is little available in Mexico and requires strict patient selection.

Objective

Determine the local control (LC) and overall survival (OS) rate in patients treated with hepatic SBRT from 2017 to 2022 in a private radiotherapy center in Mexico City.

Methods

A retrospective review was performed from January 2017 to August 2022 of the 68 SBRT cases identified. Eleven patients were included in the analysis with: 1-5 metastases, unresectable, maximum diameter of 6 cm in single lesion or ≤ 10 cm in combination, oligometastatic or oligoprogressive disease, adequate liver function (Child Pugh A-B), life expectancy >6 months and KPS 80-100.

The treatments were administered in a Truebeam system (Varian, Palo Alto, CA, USA) with 6 MV photons and FFF modality. A simulation tomography scan for planning was performed on a dedicated 16-slice CT scanner for General Electric radiation therapy. 4D CT imaging was used to capture the full motion cycle associated with breathing.

The GTV and CTV were the same taking into account MRI or PET/CT images according to availability and the placement of fiducials by interventional radiology. The PTV had a 3 to 5 mm margin over the ITV or CTV. The organs at risk included were the disease-free liver, kidneys, spinal cord, stomach, duodenum, chest wall, and small intestine.

The prescription dose and fractionation were decided following the published data and the preference of the treating physician according to radio-sensitivity of the primary tumor, tumor volume, location and distance from critical structures.

Results

Eleven patients with 19 hepatic metastases were included, with an average age of 66 years old

Table 1: Clinical and tumoral features.

Features	Mean (range)
Gender	
Male	5
Female	6
Age (years)	66 (51-82)
Number of lesions	2 (1-3)
GTV (cc)	18.3 (1.3-109.3)
PTV (cc)	45.5 (12.6-191.6)
Liver volume (cc)	1372.6 (826-1939)
Primary tumor	
Pancreatobiliar	5
Colorectal	3
Breast	1
Gastric	1
Unknown	1
Dose (Gy)	42.4 (36-50)
Dose per fraction (Gy)	10.96 (8-16.6)
BED1o (Gy)	87.3 (72-133.3)

The mean number of lesions per patient was 2 (1-3) with a mean PTV of 45.5cc.

The most used scheme was 50 Gy in 5 sessions of 10 Gy each, with a median BED of 87.3 Gy.

OS at 1 and 2 years was 75% (Fig1). LC at 1 and 2 years was 83% and 42% (Fig2), respectively.

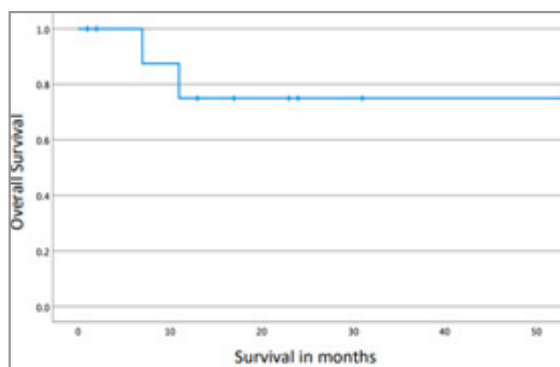


Figure 1: Overall Survival (Months)

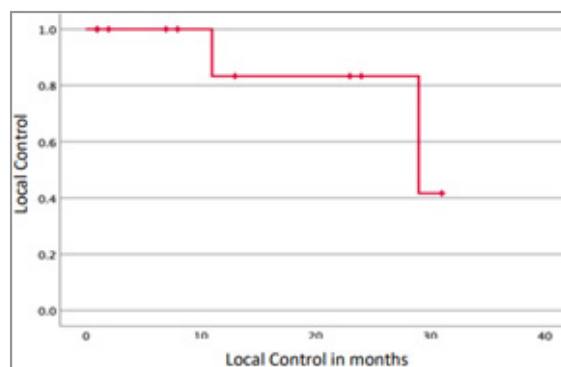


Figure 2: Local Control (Months)

Discussion

Metastatic lesions to the liver from other primary sites are common [4].

Metastasectomy remains the gold standard for resectable liver metastases [5]. However, only 10-20% of liver metastases are amenable to resection. Since most patients with liver metastases are not eligible for surgery, alternative therapies targeting the liver, such as SBRT, have shown some benefit, with 1-year LC rates of 84% and median survival of 27.6 months [6, 7].

Although the majority (63%) correspond to pathologies with short OS in metastatic stages (pancreatobiliary, stomach), the results obtained in LC and OS are consistent with what has been published in the literature [4]. This could also be explained by the strict selection of patients and their low tumor burden (2 average lesions), the higher effective biological doses (BEDs) (≥ 100 Gy) and smaller tumor volumes (< 40 cm³) [8].

Fiducial placement is suggested as it represents a reliable way to assess respiratory movement during planning and treatment, as well as the use of positron emission tomography with computed tomography (PET/CT) and contrasted magnetic resonance imaging (MRI) to delineate treatment volumes [9].

Conclusion

The study confirms that SBRT in liver metastases is a safe and effective treatment with high control rates higher than 80% at one year with SBRT, so we believe it should be promoted in our environment in properly selected patients and with centers that have the technology to perform it.

Reference

1. American Society for Radiation Oncology. (2020, June). ASTRO Model Policies.
2. Burkoň, P., Slavik, M., Kazda, T., Pospíšil, P., Prochazka, P., Vrzal, M., & et al. (2019). Stereotactic Body Radiotherapy - Current Indications. *Klinická Onkologie*, 32(Winter), 10-24.
3. Robin, T. P., Raben, D., & Schefter, T. E. (2018). A Contemporary Update on the Role of Stereotactic Body Radiation Therapy (SBRT) for Liver Metastases in the Evolving Landscape of Oligometastatic Disease Management. *Seminars in Radiation Oncology*, 28(4), 288-294.
4. Mahadevan, A., Blanck, O., Lanciano, R., Peddada, A., Sundararaman, S., Attia, A., & et al. (2018). Stereotactic Body Radiotherapy (SBRT) for liver metastasis clinical outcomes from the international multi-institutional RSSearch® Patient Registry. *Radiation Oncology*, 13, 26.
5. Robin, T. P., Raben, D., & Schefter, T. E. (2018). A Contemporary Update on the Role of Stereotactic Body Radiation Therapy (SBRT) for Liver Metastases in the Evolving Landscape of Oligometastatic Disease Management. *Seminars in Radiation Oncology*, 28(4), 288-294. (Note: This is a duplicate of reference 3)
6. Hellman, S., & Weichselbaum, R. R. (2005). Importance of local control in an era of systemic therapy. *Nature Clinical Practice Oncology*, 2(2), 60-61.
7. Scorsetti, M., Comito, T., Clerici, E., Franzese, C., Tozzi, A., Navarria, P., & et al. (2018). Phase II trial on SBRT for unresectable liver metastases: long-term outcome and prognostic factors of survival after 5 years of follow-up. *Radiation Oncology*, 13, 234.
8. Robin, T. P., Jones, B. L., & Goodman, K. A. (2017). Fiducial markers are necessary for accurate delivery of liver SBRT. *International Journal of Radiation Oncology, Biology, Physics*, 99(2, Supplement), S222.
9. Riou, O., Llacer Moscardo, C., Fenoglietto, P., Deshayes, E., Tetreau, R., Castelli, J., & et al. (2017). SBRT planning for liver metastases: A focus on immobilization, motion management and planning imaging techniques. *Reports of Practical Oncology & Radiotherapy*, 22(2), 103-110.