

# Breast Granulocytic Sarcoma: A Rare Presentation of Acute Myeloid Leukemia - A Case Report

Bouguerra F<sup>1\*</sup>, Dhouib F<sup>1</sup>, Ajengui F<sup>1</sup>, Boudwara T<sup>2</sup>, Khanfir A<sup>3</sup>, Fourati N<sup>1</sup>, and Daoud J<sup>1</sup>

<sup>1</sup>Radiotherapy Oncology department, Habib Bourguiba University-hospital, Sfax-Tunisia

<sup>2</sup>Pathology department, Habib Bourguiba University-hospital, Sfax-Tunisia

<sup>3</sup>Medical Oncology department, Habib Bourguiba University-hospital, Sfax-Tunisia

\*Corresponding author: Fadoua Bouguerra, Av Paul Vaillant Couturier Villejuif 94800 France.

Submitted: 04 April 2024 Accepted: 08 April 2024 Published: 02 May 2024

 <https://doi.org/10.63620/MKSSJMCCS.2024.1038>

**Citation:** Bouguerra, F., Dhouib, F., Ajengui, F., Boudwara, T., Khanfir, A., & Daoud, J. (2024). Breast Granulocytic Sarcoma: A Rare Presentation of Acute Myeloid Leukemia - A Case Report. *Sci Set J of Med Cli Case Stu* 3(3), 01-03.

## Abstract

**Background:** Breast extramedullary myeloid sarcoma is a rare tumor that represents 0.12% of all acute myeloid leukemia cases. Diagnosis can be a real challenge due to the non-specific clinical and radiological features.

**Reported Case:** We report a case of a 25-year-old woman who had a painful breast lump. Breast ultrasound revealed an irregular bilateral suspicious mass, and the biopsy confirmed the diagnosis of breast granulocytic sarcoma (GS). The evolution was marked by a dorsal spinal cord compression. A chemotherapy was indicated but refused by the patient. The patient was finally treated with palliative radiotherapy, and chemotherapy.

**Conclusion:** Breast myeloid sarcoma is a rare entity with symptoms reminiscent of those of primary breast cancer making its diagnosis so difficult. Treatment typically involves surgery, chemotherapy, and radiotherapy. Although the poor prognosis of breast GS, detecting the signaling pathways associated with myeloid cell migration to extra-medullary tissues may improve outcomes in the future.

**Keywords:** Extramedullary Myeloid Sarcoma, Breast Cancer, Acute Myeloid Leukemia, Surgery, Chemotherapy, Radiotherapy.

## Introduction

Breast extramedullary myeloid or breast granulocytic sarcoma (GS) is a rare tumor that belongs to the group of acute myeloid leukemias (AML). It accounts for only 0.12% of all AML cases and its diagnosis can be a real challenge due to its non-specific clinical and radiographic features.

We report a case of extramedullary myeloid sarcoma of the breast treated at the oncology radiotherapy department of Habib Bourguiba University Hospital in Sfax.

We will discuss the clinical, radiographic, anatomopathological and therapeutic characteristics of this rare tumor. Understanding the features of breast GS is crucial for an accurate diagnosis and for developing appropriate treatment strategies for patients with this rare malignancy.

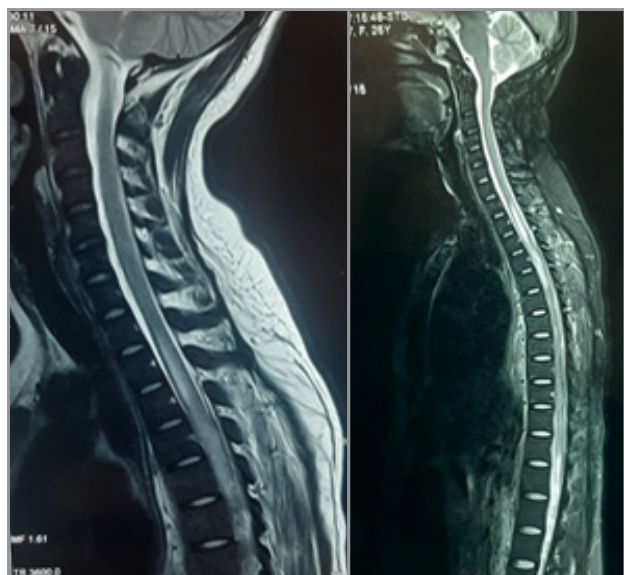
## Reported Case

We report the case of a 25-year-old pregnant woman who was diagnosed with AML through a bone marrow biopsy. A chemo-

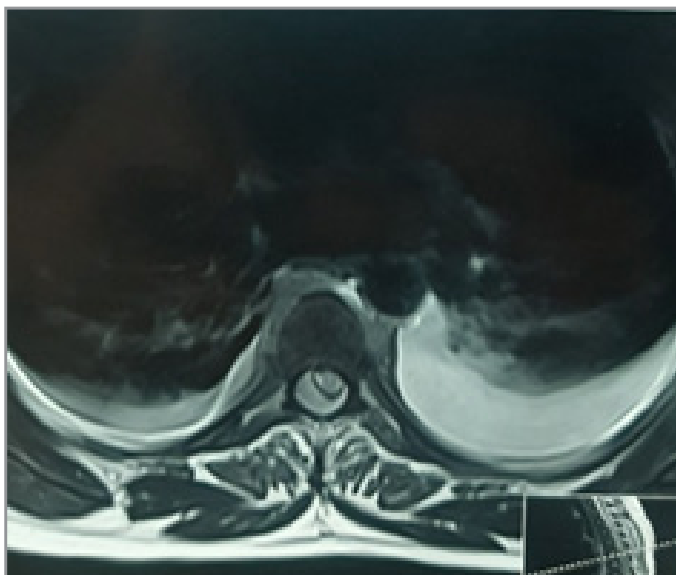
therapy was indicated but refused by the patient. Three months after giving birth, she consulted again with a flaccid paraplegia, abolished reflexes in both lower limbs, and a sensory level with functional signs of spinal pain and urinary incontinence.

Further investigations revealed a posterior epidural infiltration from D3 to D11, with a spinal cord compression. (Figure 1) In addition, the patient had mastodynia with painful and tight breasts with no inflammatory signs neither palpable nodules on axillary lymph nodes in the physical examination. Breast ultrasound revealed irregular hypoechoic areas of both breasts suggestive of granulomatous mastitis. The ultrasound examination was graded ACR 4 bilaterally. A complementary breast biopsy concluded to a diagnosis of bilateral GS.

The patient underwent palliative decompressive radiotherapy on D1-D12 level at a dose of 20 Gy in 10 fractions with a good tolerance.



(a)



(b)

**Figure 1:** Spinal cord MRI showing posterior epidural infiltration with spinal cord compression. a: sagittal sections b: coronal section

The patient was treated according to the adult AML protocol for favorable group. She received 6 cycles of Cytarabine-Idarubicin CT with clinical improvement and complete disappearance of echogenic areas on breast ultrasound. The myelogram showed a complete remission with only 3% of blasts. The treatment was complicated by febrile aplasia and atypical germs infection.

For the spinal cord compression, the patient did not report any clinical neurologic improvement after radiotherapy. She kept a complete paraplegia but with disappearance of the spinal cord compression.

After a follow-up of 9 months the patient died from a respiratory failure caused by pneumonia.

### Discussion

GS is a rare extramedullary tumor characterized by the presence of malignant myeloid precursor cells and it is commonly associated with AML. Though rare, associations with other myeloid malignancies have been reported [1-4].

The prevalence rate of GS is about 2.5-9.1% of all AML cases, and it has a slight predilection toward males. GS can occur at any age but typically in very old people [1].

The disease can affect any part of the body, but commonly lymph nodes, soft tissue, testis, skin, and the mammary gland. Breast involvement is rare, and clinical signs are often non-specific, reminiscent of those of primary breast cancer [5].

The most common symptom is palpable breast lumps, which can be either painful or not and involve both breasts. Skin involvement and enlarged axillary lymph adenopathy can also be present, increasing the risk of misdiagnosis. In the present case, only mastodynia was noted [3-6].

Radiographic features are also non-specific, making positive diagnosis so difficult [7, 8].

It is therefore essential to consider GS as a differential diagnosis of breast tumors [6, 9].

On breast ultrasound, the lesions are generally hypoechoic, microlobulated with spiculated contours and without areas of calcification. Magnetic resonance imaging using T2-weighted coronal images may show GS as multiple, irregular, heterogeneous and hyperintense masses [3, 10]. In our case, the breast ultrasound revealed irregular hypoechoic masses of both breasts [6].

Final diagnosis confirmation is based on histological analysis, which shows tumor cells with variable degrees of myeloid infiltration. Usually GS infiltrates breast tissue, preserving the tissue architecture without extensive destruction and tumor necrosis. [2, 5].

GS is frequently misdiagnosed as sarcoma, lymphoma (especially large-cell and Burkitt lymphomas), or primary breast carcinoma (especially infiltrating lobular carcinoma), then a broad panel of immunohistochemical markers is essential for accurate diagnosis [9, 11].

The therapeutic management of breast GS is still debated due to the rarity of this entity. Surgical excision, radiotherapy, and chemotherapy are the treatment modalities reported in the literature. Most studies have recommended that patients with breast GS must be treated by mastectomy or lumpectomy and chemotherapy [4, 12-14].

Imrie et al reported that patients with breast GS who received chemotherapy had a significantly longer overall survival than those who didn't. Survival was longer in patients treated with chemotherapy (> 50% alive with a median follow-up of 25 months compared with a median survival of 13 months for those initially untreated;  $p = 0.001$ ). However, there is no clear consensus regarding the impact of bone marrow transplantation on the outcomes, although recent studies have shown a significant survival benefit [9, 15-17].

Targeted therapies that are currently being tested for the treatment

of AML, such as FMS-like tyrosine kinase 3 inhibitors (FLT3 inhibitors) and farnesyl-transferase inhibitors, may also be a promising option for breast GS. However, more researches are needed to establish the efficacy and safety of these therapies [18].

The prognosis of breast GS is generally poor, with a high risk of recurrence and leukemia transformation. It is crucial to detect the signaling pathways associated with the migration of myeloid cells to extramedullary tissues to identify potential therapeutic targets. Further researches and clinical trials are necessary to improve the management and outcomes of patients with breast GS [14].

## Conclusion

Breast GS is a rare entity and its diagnosis can be a real challenge due to its non-specific clinical and radiological features. It is crucial to be aware of the main radiological and anatomopathological characteristics of this pathology, and to report local experiences to better assist clinicians in their therapeutic management. Treatment strategies, including surgical excision, radiotherapy, and chemotherapy, remain controversial. However, studies have suggested that patients with breast GS should be treated by mastectomy or lumpectomy plus chemotherapy. Targeted therapies currently in trial for AML may also be effective in breast GS treatment. Although the poor prognosis of breast GS, detecting the signaling pathways associated with myeloid cell migration to extra-medullary tissues may improve outcomes in the future.

## Conflicting Interests

The Authors declare that there is no conflict of interest

## Funding

No funding was required as the data collection was done freely and for patients included in the study. This work was not supported by any specific grants from public, commercial or non-profit funding organizations.

## Ethical Approval

Our work was conducted in accordance with ethical guidelines and obtained the necessary ethical approvals. This study was approved by the Reviewer Board of our Faculty of Medicine of Sfax; this approval includes ethical consideration.

## Informed Consent

Written informed consent was obtained from a legally authorized representative for anonymised patient information to be published in this article. Clear and appropriate information was communicated, including a description of the survey process and its scientific purpose. They indicated their willingness to participate to this study.

## References

- Vieira, V. F., Vo, Q. D., de la Jolinière, J. B., Khomsi, F., Feki, A., et al. (2017). Granulocytic sarcoma presenting as a palpable breast lump. *Frontiers in Surgery*, 3, 67. <https://doi.org/10.3389/fsurg.2016.00067>
- Zhai, J., Kong, X., Yang, X., Gao, J., Xuan, L., et al. (2018). An uncommon granulocytic sarcoma of the breast: A case report and literature review. *OncoTargets and Therapy*, 11, 3685–3690. <https://doi.org/10.2147/OTT.S165242>
- Fu, J., & Luo, J. (2014). Granulocytic sarcoma of the breast in acute myeloid leukemia: Two case reports. *Oncology Letters*, 7(1), 145–147. <https://doi.org/10.3892/ol.2013.1670>
- Huang, X. E., Li, Y. J., & Zhou, X. D. (2015). Granulocytic sarcoma of the breast: A case report. *Oncology Letters*, 10(4), 2447–2449. <https://doi.org/10.3892/ol.2015.3537>
- Joo, M., Lee, H. K., Kang, Y. K., & Kim, J. H. (2009). Granulocytic sarcoma of the breast preceding acute myelogenous leukemia: A case report. *Journal of Korean Medical Science*, 15, 457–459. <https://doi.org/10.3346/jkms.2000.15.4.457>
- Thachil, J., Richards, R. M., & Copeland, G. (2007). Granulocytic sarcoma – a rare presentation of a breast lump. *Annals of the Royal College of Surgeons of England*, 89(1), 7–9. <https://doi.org/10.1308/003588407X155568>
- Park, J. W., Ko, K. H., Kim, E. K., Kuzmiak, C. M., & Jung, H. K. (2017). Non-mass breast lesions on ultrasound: Final outcomes and predictors of malignancy. *Acta Radiologica*, 58(9), 1054–1060. <https://doi.org/10.1177/0284185116682907>
- Basara, I., & Orguc, S. (2012). Giant breast involvement in acute lymphoblastic leukemia: MRI findings. *Journal of Breast Cancer*, 15(2), 258–260. <https://doi.org/10.4048/jbc.2012.15.2.258>
- Delporte, F., Voorhoof, L. J. B., Lodewyck, T., & De Paepe, P. (2011). Primary granulocytic sarcoma of the breast: A case report and review of the literature. *European Journal of Gynaecological Oncology*, 32, 435–438.
- Yang, W. T., Muttarak, M., & Ho, L. W. C. (2000). Non-mammary malignancies of the breast: Ultrasound, CT, and MRI. *Seminars in Ultrasound, CT and MRI*, 21(4), 375–394. <https://doi.org/10.1053/uctm.2000.9020>
- Valbuena, J. R., Admirand, J. H., Gualco, G., & Medeiros, L. J. (2005). Myeloid sarcoma involving the breast. *Archives of Pathology & Laboratory Medicine*, 129(1), 32–38. <https://doi.org/10.5858/2005-129-32-MSITB>
- Ngu, I. W. Y., Sinclair, E. C., Greenaway, S., & Greenberg, M. L. (2001). Unusual presentation of granulocytic sarcoma in the breast: A case report and review of the literature. *Diagnostic Cytopathology*, 24(1), 53–57. [https://doi.org/10.1002/1097-0339\(200101\)24:1<53::AID-DC13>3.0.CO;2-L](https://doi.org/10.1002/1097-0339(200101)24:1<53::AID-DC13>3.0.CO;2-L)
- Barloon, T. J., Young, D. C., & Bass, S. H. (1993). Multicentric granulocytic sarcoma (chloroma) of the breast: Mammographic findings. *American Journal of Roentgenology*, 160(5), 963–964. <https://doi.org/10.2214/ajr.160.5.8470582>
- Paydas, S., Zorludemir, S., & Ergin, M. (2006). Granulocytic sarcoma: 32 cases and review of the literature. *Leukemia & Lymphoma*, 47(12), 2527–2541. <https://doi.org/10.1080/10428190600990396>
- Imrie, K. R., Kovacs, M. J., Selby, D., Lipton, J., & Patterson, B. J., et al. (1995). Isolated chloroma: The effect of early antileukemic therapy. *Annals of Internal Medicine*, 123(5), 351–353. <https://doi.org/10.7326/0003-4819-123-5-199509010-00003>
- Antic, D., Elezovic, I., Milic, N., Suvajdzic, N., & Vidovic, A., et al. (2013). Is there a “gold” standard treatment for patients with isolated myeloid sarcoma? *Biomedicine & Pharmacotherapy*, 67(1), 72–77. <https://doi.org/10.1016/j.biopha.2012.10.001>
- Avni, B., Rund, D., Levin, M., Grisariu, S., Ben-Yehuda, D., et al. (2012). Clinical implications of acute myeloid leukemia presenting as myeloid sarcoma. *Hematological Oncology*, 30(1), 34–40. <https://doi.org/10.1002/hon.996>
- Yilmaz, A. F., Saydam, G., Sahin, F., & Baran, Y. (2013). Granulocytic sarcoma: A systematic review. *American Journal of Blood Research*, 3(3), 265–270.