

# Traditional Chinese Medicine Herbal Treatment of COVID-19-Related Psoriasis: An Observational Success in Alternative Therapy

Po-Hsuan Chiu<sup>1,2</sup>, Ta-Chen Chen<sup>1,3</sup>, Hui-Yu Chung<sup>1</sup>, Peng-Yuan Li<sup>1</sup>, Shigeharu Tanei<sup>1</sup>, Ichiro Arai<sup>1</sup>, & Fu-Shih Chen<sup>1\*</sup>

<sup>1</sup>Graduate School of Pharmaceutical Sciences, Nihon Pharmaceutical University, Tokyo, Japan

<sup>2</sup>Dr. Syuan Chinese Medicine Clinic, Kaohsiung, Taiwan

<sup>3</sup>Department of Pharmacy, Chia Nan University of Pharmacy & Science, Tainan, Taiwan

\*Corresponding author: Fu-Shih Chen, Graduate School of Pharmaceutical Sciences, Nihon Pharmaceutical University, Tokyo, Japan.

Submitted: 17 January 2024 Accepted: 23 January 2024 Published: 29 January 2024

doi <https://doi.org/10.63620/MKWJMHHC.2024.1004>

**Citation:** Chiu, P.-H., Chen, T.-C., Chung, H.-Y., Li, P.-Y., Tanei, S., Arai, I., & Chen, F.-S. (2024). Traditional Chinese Medicine Herbal Treatment of COVID-19-Related Psoriasis: An Observational Success in Alternative Therapy. *Wor Jour of Medic and Heal Care* 2(1), 01-05.

## Abstract

This report describes a 37-year-old male who developed severe psoriasis after being diagnosed with COVID-19 in March 2023. Western medicine treatment proved ineffective over six months. In September, he switched to Traditional Chinese Medicine (TCM) treatment. At the initial assessment, psoriasis affected 22% of his Body Surface Area (BSA), with a Psoriasis Area Severity Index (PASI) score of 12.6. TCM diagnosis indicated a predominance of dampness and spleen deficiency. The treatment plan included Chai Hu Gui Zhi Gan Jiang Tang, Wu Ling San, and topical application of Indigo Naturalis gel, among other Chinese herbal therapies. One week later, there was improvement with a decrease in BSA to 17% and a PASI score of 3.9. Three weeks into treatment, the psoriasis disappeared, and no relapse occurred during the three-month follow-up period.

Globally, psoriasis affects approximately 0.5-11.4% of adults, with increased cases of worsening or new-onset psoriasis following COVID-19. TCM has emerged as a new option for treating psoriasis, especially in cases where Western medicine has proven ineffective. This case demonstrates the effectiveness of TCM in treating COVID-19-related psoriasis, offering a research opportunity for the modern application of traditional Chinese medicine in healthcare.

**Keywords:** Psoriasis, COVID-19, Traditional Chinese Medicine (TCM), Alternative Therapy, Indigo Naturalis

## Introduction

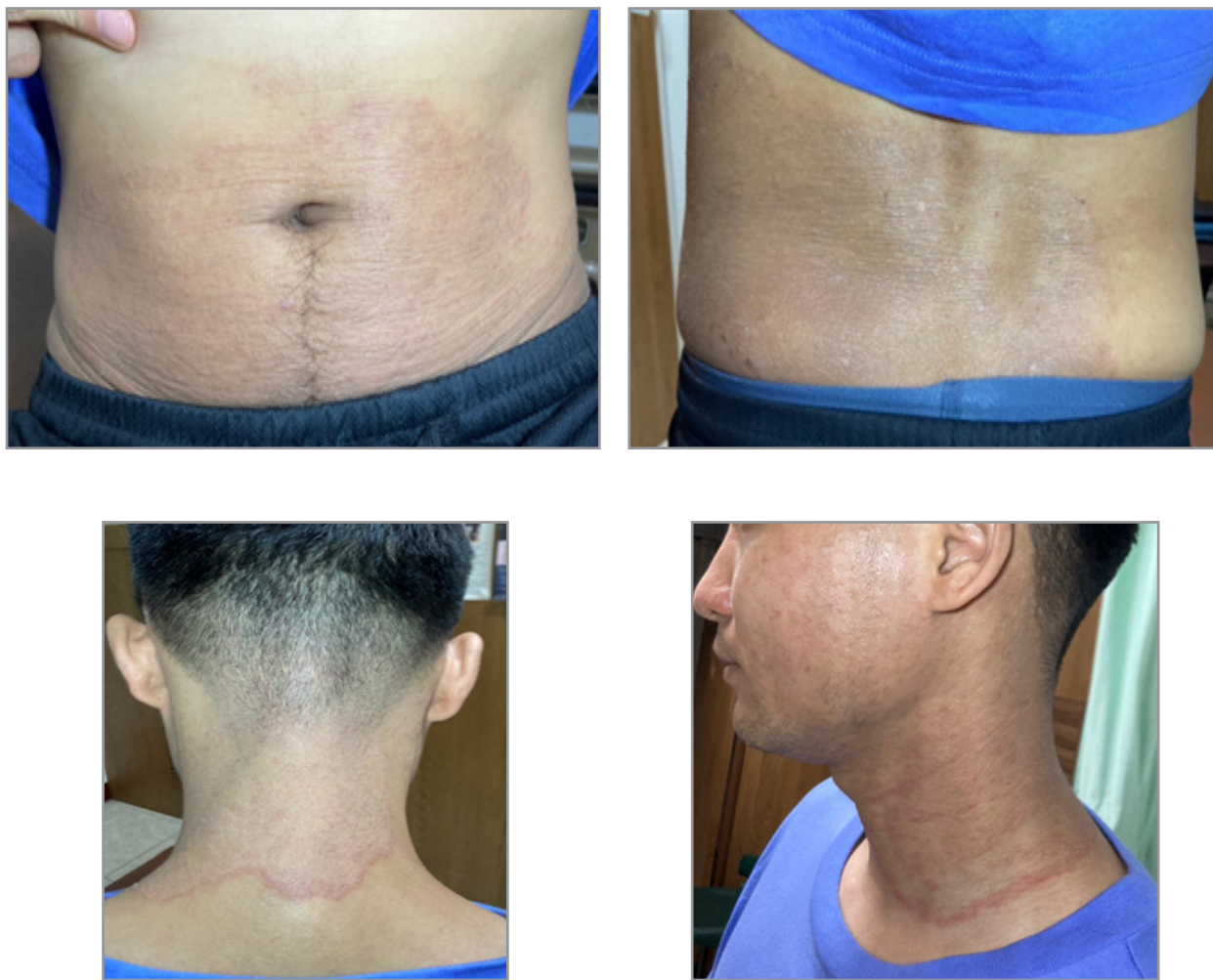Psoriasis is a common inflammatory disease, affecting 0.5-11.4% of the global population [1]. Psoriasis is associated with a decrease in quality of life, emotional stress, and major health conditions: including psoriatic arthritis, cardiovascular diseases, and obesity [2]. Since the outbreak of COVID-19 in 2019, there have been some reports of psoriasis flare-ups following a confirmed diagnosis, as well as cases of psoriasis emerging after receiving the COVID-19 vaccine [1]. Although most reports indicate that these COVID-related psoriasis cases can be successfully treated, many patients still show poor responses to Western medicine treatments.

Traditional Chinese Medicine (TCM) provides a theoretical basis for treating psoriasis, offering significant benefits and low toxicity, which enhances its safety for clinical application in psoriasis [3, 4]. In Taiwan, China and South Korea, clinical practitioners prescribe medication based on the patient's constitution, following a pattern differentiation and treatment approach [5, 6]. According to the theory of internal and external treatment in TCM, the etiology of psoriasis is attributed to long-standing pathogenic wind-heat, which may arise from external factors such as wind, dampness, and heat, or internal causes like emo-

tional distress and stagnation of qi (energy) [7]. Adjusting the Chinese herbal medicine formulation according to the patient's clinical condition can achieve better results. We introduce a case where psoriasis occurred after a COVID-19 diagnosis, with steroid treatment proving ineffective, and a significant improvement was observed following the switch to TCM treatment. The Global Assessment (GA) and the Psoriasis Area Severity Index (PASI) are physician-assessed indicators of skin disease activity, widely used in real-world practice and clinical trials, and recommended in treatment guidelines [2].

## Case Report

A 37-year-old male with no history of chronic illness developed widespread psoriasis on his skin after being diagnosed with COVID-19 in March 2023. The condition primarily affected his head, neck, and trunk. After initially undergoing Western medical treatment with steroids and antihistamines for six months without success, he sought treatment from a traditional Chinese medicine practitioner in Taiwan on September 11, 2023. At the time of consultation, extensive skin redness and swelling were observed on his face, neck, and back, along with thickened, keratinized, itchy skin covering about 22% of BSA and a PASI score of approximately 12.6 (FIG 1).



**Figure 1:** First consultation on September 11, 2023. A) The abdomen and B) the back displayed extensive psoriasis with noticeably thickened, red, keratinized skin and clear borders. C) The posterior neck and D) the face and left side of the neck showed extensive skin redness and swelling, with increased thickening and keratinization of the skin, significantly thicker at the borders. The body surface area (BSA) affected was approximately 22%, with a PASI score of around 12.6.

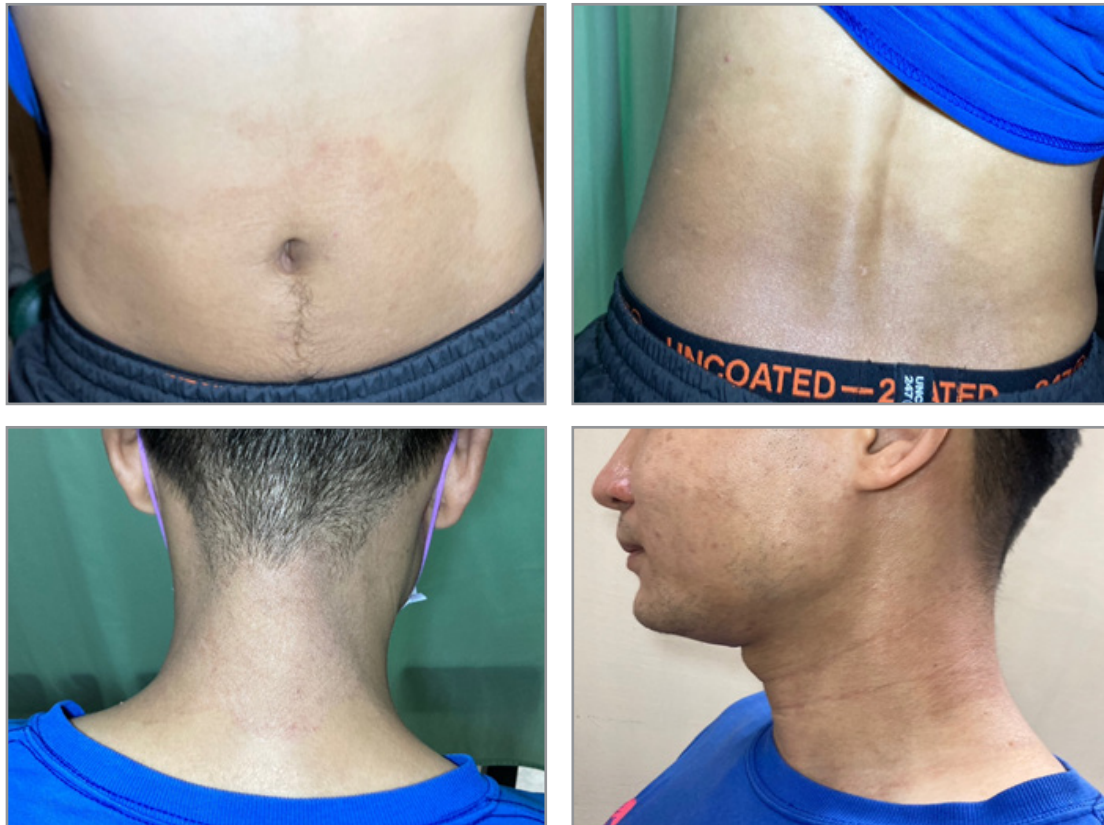Abdominal examination revealed a soft abdomen. Pulse diagnosis showed deep and slippery pulses in both hands. Tongue diagnosis revealed a pale red tongue with a slippery coating. The patient did not smoke or drink alcohol. He experienced frequent bloating, a sensation of heaviness in the body and head, soft stools, and was prone to tension, anxiety, diarrhea, and abdominal pain.

On September 11, 2023, the initial prescription plan was as follows: Oral intake of scientifically formulated Chinese herbal powder throughout the treatment using Chuang Song Zong Pharmaceutical Co., Ltd products. The daily dosage included: 10g of Chaihu Guizhi Ganjiang Tang, 10g of Wuling San, 5g of Dandelion (*Taraxacum officinale*.), 3g of Ji Xue Teng (*Spatholobus suberectus*), and 2g of Indigo Leaf (*Isatis indigotica*). These were to be taken twice daily, morning and evening, with a one-week

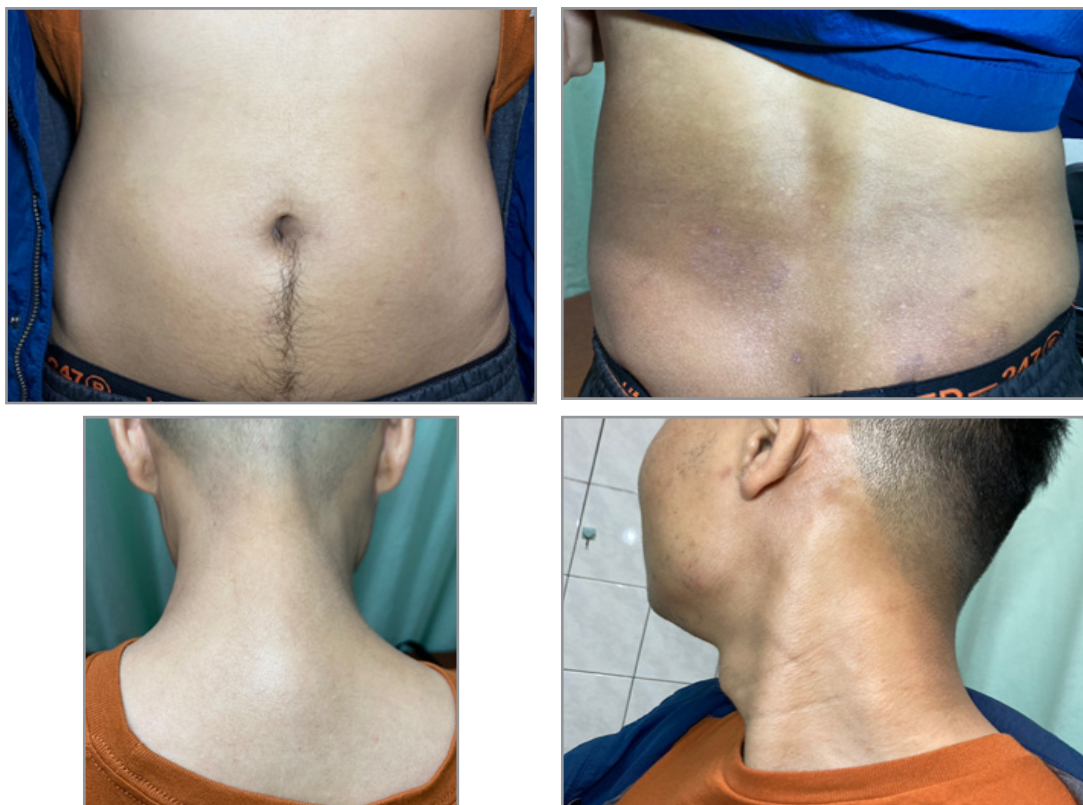
supply of medication prescribed. Topical application of Chinese herbal ointment on psoriasis lesions: Indigo Naturalis gel will be applied twice daily, using approximately 1 gram for every 100 square centimetres of the affected area.

On the follow-up visit on September 18, 2023, there was a significant fading of the erythematous psoriasis patches on the neck and abdomen, with thinning of the keratin layer. The BSA affected decreased to 17%, and the PASI score dropped to 3.9. The patient continued the prescribed medication for an additional two weeks, after which psoriasis on the skin completely disappeared, with the PASI score dropping to 0, leaving only slight pigmentary changes. Symptoms like heaviness in the body and head, tension, diarrhea, and bloating related to the gastrointestinal tract are also completely resolved. As of November 23, 2023, there was no recurrence (FIG 2, 3).





**Figure 2:** On September 18, 2023, A) the abdomen and B) the back showed significant fading of the erythematous psoriasis patches, with the keratin layer becoming thinner and the borders less distinct. C) The posterior neck and D) the face and left side of the neck showed a substantial reduction in skin redness and swelling, with the thickened, keratinized layer becoming thinner and the most noticeable changes at the borders. The BSA decreased to 17%, and the PASI score dropped to 3.9.



**Figure 3:** Follow-up photos taken on November 23, 2023, showing complete recovery from psoriasis with no recurrence. In the A) abdominal, C) posterior neck, and D) facial photos, there are no visible traces of psoriasis. Only on the B) back can a small amount of post-psoriasis pigmentary changes and spots be seen.

## Discussion

Psoriasis is a complex immune-mediated inflammatory skin disease [8]. Its development primarily involves genetic factors, the immune system, and environmental elements [9]. Diagnosing psoriasis mainly relies on clinical presentation and the patient's medical history. Psoriasis can manifest in various clinical presentations, including plaque psoriasis, inverse psoriasis, guttate psoriasis, and erythrodermic psoriasis [10-12]. In this case, the patient exhibits common plaque psoriasis characterized by salmon-pink patches with silvery-white scales, distributed on the extensor surfaces, trunk, scalp, and neck [13].

Infection with the COVID-19 virus and certain medications used to treat COVID-19 have been reported to be associated with psoriasis flare-ups. Viral infection and medications used for treatment, such as hydroxychloroquine, are potential causes for triggering psoriasis outbreaks [1]. In our case, the likely causes are viral infection and emotional stress, leading to an abnormal immune response [8].

Psoriasis has a long-recorded history in China [7]. According to traditional Chinese medicine's classification of disease constitutions, they can be categorized as follows: heat toxins, dampness, wind pathogens, liver fire, excess conditions, liver depression, spleen deficiency, blood deficiency, and yin deficiency [14]. In this case, the pulse diagnosis for both hands indicates a deep and smooth pulse, while the tongue examination reveals a pale red tongue body with a slippery tongue coating. The patient experiences frequent bloating, a sensation of heaviness in the body and head, and has slightly soft stools. This condition falls into the category of predominant dampness and belongs to the spleen deficiency type. Therefore, using the "Wu Ling San" formula to strengthen the spleen and eliminate dampness is recommended [15]. Furthermore, due to the patient's tendency towards nervousness, anxiety, diarrhea, and abdominal pain, reports suggest that the "Chai Hu Gui Zhi Gan Jiang Tang" formula has shown significant effectiveness in treating irritable bowel syndrome [16]. Therefore, this formula suits patients with liver stagnation, tension, and spleen deficiency. Because psoriasis is a chronic inflammatory, immune-mediated disease associated with many other immune-related clinical conditions, often coexisting, including those affecting the gastrointestinal tract, it is crucial to use traditional Chinese herbal medicine to regulate gastrointestinal function [17].

In this case, Indigo Leaf (*Isatis indigotica*) and Dandelion (*Taraxacum officinale*) possesses antipyretic and detoxifying properties and treats psoriasis [18]. Ji Xue Teng (*Spatholobus suberectus*) is a commonly used Chinese herbal medicine for psoriasis [4]. In traditional Chinese medicine, when treating psoriasis, the focus is addressing symptoms and restoring inner balance [19]. Therefore, in this case, the "Wu Ling San" formula and "Chai Hu Gui Zhi Gan Jiang Tang" are used to strengthen gastrointestinal and immune functions. Moreover, in combination with Chinese herbs like Indigo Leaf and Dandelion, which have heat-clearing and detoxifying properties, it alleviates the skin's inflammatory response. Regarding the external use of Chinese herbs, Indigo Naturalis has been widely used for local treatment of psoriasis [20, 21]. It can effectively treat psoriasis by regulating the proliferation and differentiation of keratinocytes, controlling inflam-

mation infiltration of the cell immune system, and improving microvascular dilation and proliferation in skin lesions [22]. The topical application of Indigo Naturalis ointment is a novel, safe, and effective therapy for treating psoriasis [23, 24]. This Indigo Naturalis gel consists of 5% Indigo Naturalis powder and 95% matrix (containing 5% Carbomer and 95% aloe vera gel). Indigo Naturalis is supplied by the Chinese pharmacy affiliated with our clinic.

TCM has unique advantages in treating psoriasis, including symptom-based classification, a rich and flexible treatment philosophy, and numerous treatment methods and prescriptions proven highly effective and safe through years of clinical practice [25]. Treatment aims for symptom relief and emphasizes achieving stable therapeutic outcomes by adjusting visceral functions and overall constitution [19]. This approach believes skin health directly reflects the balance of internal organs and energy flow within the body, thus achieving therapeutic goals through comprehensive regulation.

## Conclusion

This case demonstrates a significant improvement in psoriasis outbreak following the use of traditional Chinese herbal medicine after Western medical treatment proved ineffective post-COVID-19 infection. It highlights the potential of TCM in treating skin conditions. TCM addresses the skin symptoms and recovers rapid psoriasis by regulating the constitution and inner balance.

It provides new insights for clinicians and researchers, particularly in refractory skin diseases where conventional treatments fail. It showcases the effectiveness of TCM in treating psoriasis, especially COVID-19-related psoriasis. The internal and external treatment methods of TCM can serve as a relatively cost-effective and efficient alternative therapy.

## Acknowledgments

We want to thank the patients and their families who participated in this study. Their trust and support have enabled the smooth progress of this report, contributing significantly to the advancement of medical knowledge and patient care.

## Ethical Considerations

The authors of this article confirm no direct financial conflicts of interest. They have not received financial support from pharmaceutical companies or healthcare organizations related to this research. There are no affiliations or involvement with any institutions with financial interests. Personal interests that could influence the research content are absent. The research method does not involve any patents or proprietary knowledge. Additionally, this case is original and has not been published elsewhere, and the data supporting the conclusions will be publicly available. The authors understand the importance of disclosing potential conflicts of interest and ensure that the provided information is accurate and based on the best knowledge available.

## Reference

1. Wu, P.-C., Huang, I.-H., Wang, C.-W., Tsai, C.-C., Chung, W.-H., & others. (2022). New onset and exacerbations of psoriasis following COVID-19 vaccines: A systematic review. *American Journal of Clinical Dermatology*, 23, 775-

2. Carr, E., Mahil, S. K., Brailean, A., Dasandi, T., Pink, A. E., & others. (2021). Association of patient mental health status with the level of agreement between patient and physician ratings of psoriasis severity. *JAMA Dermatology*, 157(4), 413-420.
3. Yang, D., Guo, Y., Wu, J., Qin, J., Wu, J., & others. (2022). Chinese herbal medicine Jia Wei Jing Xie Yin (JWJXY) ameliorates psoriasis via suppressing the Th17 cell response. *Annals of Translational Medicine*, 10, 332.
4. Luo, Y., Chen, J., Kuai, L., Zhang, Y., Ding, X., & others. (2021). Chinese herbal medicine for psoriasis: Evidence from 11 high-quality randomized controlled trials. *Frontiers in Pharmacology*, 11, 599433.
5. Lee, S. Y., Seo, Y. M., Oh, E. S., Ha, D. L., Kim, D. Y., & others. (2021). A case report with long-term Korean medical treatment of systemic psoriasis patient. *Herbal Formula Science*, 29, 311-319.
6. Dou, Z., Xia, Y., Zhang, J., Li, Y., Zhang, Y., & others. (2021). Syndrome differentiation and treatment regularity in traditional Chinese medicine for type 2 diabetes: A text mining analysis. *Frontiers in Endocrinology*, 12, 728032.
7. Liu, C.-T., Chang, C.-C., Yang, Y.-H., Wu, B.-Y., Chen, P.-C., & others. (2020). Investigation of Chinese herbal products prescribed to patients with psoriasis of outpatient service from the National Health Insurance Research Database in Taiwan. *Journal of Chinese Medicine*, 31, 70-85.
8. Kamiya, K., Kishimoto, M., Sugai, J., Komine, M., & Ohtsuki, M. (2019). Risk factors for the development of psoriasis. *International Journal of Molecular Sciences*, 20(18), 4347.
9. Roszkiewicz, M., Dopytalska, K., Szymanska, E., Jakimiuk, A., & Walecka, I. (2020). Environmental risk factors and epigenetic alterations in psoriasis. *Annals of Agricultural and Environmental Medicine*, 27(3), 335-342.
10. Rendon, A., & Schäkel, K. (2019). Psoriasis pathogenesis and treatment. *International Journal of Molecular Sciences*, 20(6), 1475.
11. Raharja, A., Mahil, S. K., & Barker, J. N. (2021). Psoriasis: A brief overview. *Clinical Medicine*, 21(2), 170-173.
12. Sarac, G., Koca, T. T., & Baglan, T. (2016). A brief summary of clinical types of psoriasis. *Northern Clinics of Istanbul*, 3(1), 79-82.
13. Mason, A. R., Mason, J., Cork, M., Dooley, G., & Hancock, H. (2013). Topical treatments for chronic plaque psoriasis. *Cochrane Database of Systematic Reviews*, 28, CD005028.
14. Zhou, D., Chen, W., Li, X., Deng, B., Xu, W., Qu, J., ... & Liu, J. (2014). Evidence-based practice guideline of Chinese herbal medicine for psoriasis vulgaris (Bai Bi). *European Journal of Integrative Medicine*, 6(2), 135-146.
15. Ren, Y., Wang, Z., Li, H., & Ma, Y. (2022). Analysis of Wuling Powder in the treatment of renal edema. *MEDS Chinese Medicine*, 4, 14-21.
16. Li, M., Zhu, J., Liu, X., Dong, Z., Tang, J., Zhang, C., ... & Chen, W. (2022). Chaihu-Guizhi-Ganjiang Decoction is more efficacious in treating irritable bowel syndrome than Dicetel according to metabolomics analysis. *Chinese Medicine*, 17, 139.
17. Pietrzak, D., Pietrzak, A., Krasowska, D., Borzęcki, A., Franciszkiewicz-Pietrzak, K., Polkowska-Pruszyńska, B., ... & Reich, K. (2017). Digestive system in psoriasis: An update. *Archives of Dermatological Research*, 309(9), 679-693.
18. Yu Y, Wang L (2023) Study on the Rule of Traditional Chinese Medicine in Treating Psoriasis with Blood Heat Syndrome Based on Data Mining. *MEDS Chinese Medicine* 5: 42-49.
19. Yingshuai, L., & Yan, L. (2023). Progress in the study of Yang-deficiency constitution in terms of traditional Chinese medicine: A narrative review. *Journal of Traditional Chinese Medicine*, 43, 409-416.
20. Lin, Y. K., See, L. C., Huang, Y. H., Chang, Y. C., Tsou, T. C., Lin, T. Y., & Lin, N. L. (2014). Efficacy and safety of Indigo naturalis extract in oil (Lindioil) in treating nail psoriasis: A randomized, observer-blind, vehicle-controlled trial. *Phytomedicine*, 21(8-9), 1015-1020.
21. Wang, P., Gao, J., Guo, S., Liu, H., Cao, C., Hong, S., ... & Xu, R. (2023). Benefits of topical indigo naturalis nanofibrous patch on psoriatic skin: A transdermal strategy for botanicals. *Materials Today Bio*, 22, 100756.
22. Zhang, Q., Xie, J., Li, G., Wang, F., Lin, J., Yang, M., ... & Han, L. (2022). Psoriasis treatment using Indigo Naturalis: Progress and strategy. *Journal of Ethnopharmacology*, 297, 115522.
23. Lin, Y. K., Wong, W. R., Chang, Y. C., Chang, C. J., Tsay, P. K., Chang, S. C., & Pang, J. H. S. (2007). The efficacy and safety of topically applied indigo naturalis ointment in patients with plaque-type psoriasis. *Dermatology*, 214, 155-161.
24. Lin, Y. K., Chang, C. J., Chang, Y. C., Wong, W. R., Chang, S. C., & Pang, J. H. S. (2008). Clinical assessment of patients with recalcitrant psoriasis in a randomized, observer-blind, vehicle-controlled trial using indigo naturalis. *Archives of Dermatology*, 144, 1457-1464.
25. Su, Y., Qin, W., Wu, L., Yang, B., Wang, Q., Kuang, H., & Cheng, G. (2021). A review of Chinese medicine for the treatment of psoriasis: Principles, methods and analysis. *Chinese Medicine*, 16, 138.