

Invasive Stratified Mucin-Producing Carcinoma of Cervix: A Case Report

Xuechuan Han, Yan Yu, & Yang Fan*

Department of Obstetrics and Gynecology, People's Hospital of Ningxia Hui Autonomous Region, Ningxia Medical University, Yinchuan, China
(301 Zhengyuan North Street, Yinchuan, Ningxia 750002, China)

***Corresponding author:** Yang Fan, Department of Obstetrics and Gynecology, People's Hospital of Ningxia Hui Autonomous Region, Ningxia Medical University, Yinchuan, China.

Submitted: 02 June 2025 Accepted: 11 June 2025 Published: 16 June 2025

doi <https://doi.org/10.63620/MK.SSJMCCS.2025>.

Citation: Han, X., Yu, Y., & Fan, Y. (2025). Invasive Stratified Mucin-Producing Carcinoma of Cervix: A Case Report. *Sci Set J of Med Cli Case Stu*, 4(3), 01-03.

Abstract

Invasive stratified mucin-producing carcinoma (ISMC) of the cervix is a rare and recently classified subtype of human papillomavirus (HPV)-associated mucinous adenocarcinoma. First described in 2016 and later included in the WHO classification of tumors of the female reproductive system, ISMC is characterized by unique histological and immunohistochemical features and is considered to be potentially more aggressive than other adenocarcinoma subtypes. We report a case of a 51-year-old menopausal woman who presented with unexplained vaginal bleeding. Imaging and biopsy confirmed cervical cancer, and she underwent laparoscopic radical hysterectomy with bilateral salpingo-oophorectomy and pelvic lymph node dissection. Histopathological evaluation revealed ISMC with distinctive features including papillary and nested patterns, presence of mucin, and a specific immunoprofile. Postoperative radiotherapy and chemotherapy were administered, and no recurrence was observed during a 12-month follow-up. This case highlights the clinical and pathological characteristics of ISMC, its diagnosis, differential considerations, and treatment strategy, emphasizing the importance of recognizing this rare and potentially aggressive cervical carcinoma variant.

Keywords: Invasive Stratified Mucin-Producing Carcinoma (ISMC), cervical cancer, HPV-Associated Adenocarcinoma

Introduction

Cervical cancer is the third most common malignant cancer in women. With an incidence of approximately 661,021 new cases and 348,189 new deaths each year (1, 2). The squamous cell carcinoma is the most common cervical cancer, but the incidence of cervical adenocarcinoma has increased in recent years. The cervical adenocarcinoma accounts for approximately 25% of cervical carcinomas. The cervical adenocarcinoma has been classified into HPV-associated adenocarcinoma (HPVA) and HPV-independent adenocarcinoma (NHPVA). Invasive stratified mucin-producing carcinoma (ISMC) of the cervix is a special subtype of HPV-related invasive mucinous adenocarcinoma (3). It first described by Lastra et al in 2016(4). The fifth edition

of the World Health Organization (WHO) classification of tumors of the female reproductive system in 2020 included ISMC (5). Here, we report a case of ISMC in our hospital.

Case Representation

A 51-year-old female menopausal patient was hospitalized in our department with unexplained vaginal bleeding for more than 20 days. Specialist examination showed cauliflower-like bloody lesions with size as 2.5 cm in diameter on the cervix. She was positive for type 45 HPV. Both transvaginal ultrasound and pelvic magnetic resonance imaging showed a cervical mass and cervical cancer was considered.

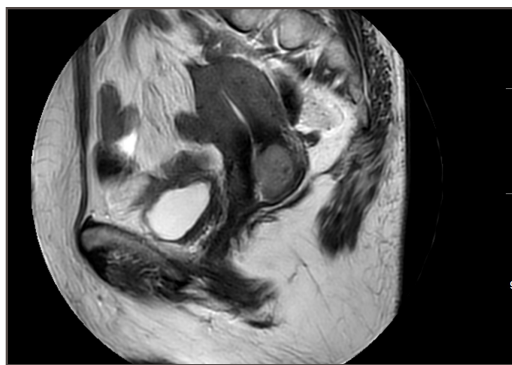


Figure 1

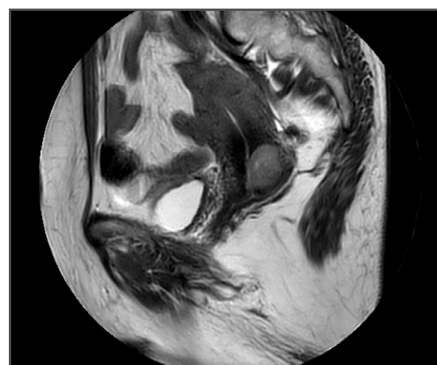


Figure 2

The biopsy of the cervix was done. The pathology demonstrated cervical undifferentiated adenocarcinoma. There were no surgical contraindications. The patient had undergone laparoscopic radical hysterectomy + bilateral salpingo-oophorectomy + pelvic lymph node dissection under general anesthesia. In the final pathology, microscopically, the tumor cells were arranged in papillary, nested and diffuse patchy patterns and mainly distributed in the background of lymphocytes and neutrophils. Inflammatory cells were located around the tumor or in the tumor cell nests. The tumor cells lined the edge of nests in a palisade

form. There were many myxoid sacs and intracellular mucus in the nest. The tumor cells were obviously heteromorphic. The mitosis and apoptotic bodies were easily detected. Immunohistochemical staining showed tumor cells were strongly positive for CAM5.2, CK7, p16 and CEA, while negative for ER, PR, p40, p53, p63 and PAX8. The positive index of Ki67 was about 50%. Periodic acid-schiff (PAS) staining indicated presence of mucus both inside and outside tumor cells. The final pathological diagnosis of invasive stratified mucin-producing carcinoma of cervix.

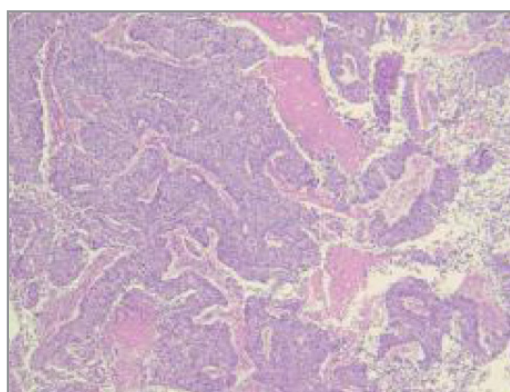


Figure 3

Postoperative radiotherapy and chemotherapy were performed. The patient's general condition was good. There was no tumor recurrence or metastasis was observed for more than 12 months.

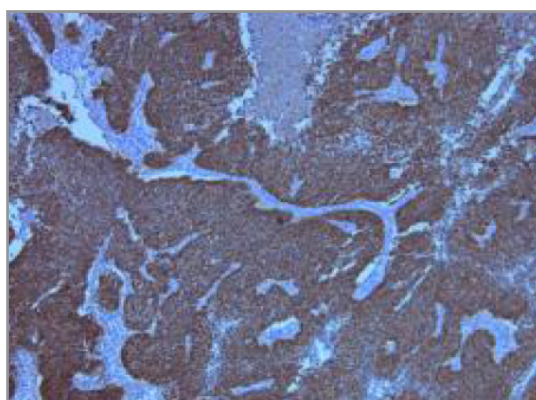


Figure 4

Discussion

Invasive stratified mucin-producing carcinoma (ISMC) was described in 2016 by Lastra et al (4).as a morphologic variant of endocervical adenocarcinoma (ECA), with similar morphology to stratified mucin-producing intraepithelial lesion of the cervix (SMILE), its putative precursor. There were some studies evaluating ISMC have suggested that this tumor subtype is potentially more aggressive and with worse outcomes compared to usual-type endocervical adenocarcinoma (6). The type of ISMC with a substantial risk of distant metastatic disease, especially to the lungs.ISMC was considered to be similar to SMILE according to histological characteristics and immunophenotype. ISMC was regarded as the invasive component of SMILE. Both ISMC and SMILE originate from stem cells with multi-directional differentiation potential in the transformation zone. Under the action of high-risk HPV, they appeared as stratified and immature epithelial cells containing different amounts of mucus in the cytoplasm. Electron microscopy could show that mucus can be seen in both of them. Like myxoid vacuoles and mitochondria, they lacked tension filaments and it further demonstrates their glandular properties.Morphologically, ISMC should be differentiated from squamous cell carcinoma, adenosquamous carcinoma, mucoepidermoid carcinoma and adenoid cystic carcinoma, mainly based on morphological features and cellular components. If necessary, additional immunohistochemical or molecular detection should be performed. Correlative studies had shown ISMC has a worse clinical prognosis, which associated with larger tumor size, more frequent lymph node metastasis and higher FIGO stage. Surgery was the main treatment.It was supplemented by postoperative radiotherapy and chemotherapy. The latest research shows some patients may benefit from PD-L1 immunotherapy (7). But the specific immune therapy efficacy needs to be further studied.

Pure ISMC classically shows nests of stratified columnar cells with nuclear palisading along the periphery of the nests, with variable amounts of intracytoplasmic mucin ranging from mucin-rich to mucin-poor; nuclei were unifrom, small, round-to-ovoid with inconspicuous nucleoli.

Conclusion

Invasive stratified mucin-producing carcinoma (ISMC) is a rare and newly classified subtype of HPV-associated cervical adenocarcinoma with distinctive morphological and immunohistochemical features. This case highlights the importance of recognizing ISMC as a distinct entity, given its potential for aggressive behavior and poor prognosis compared to more common cervical carcinomas. Accurate histopathological diagnosis, supported by appropriate immunostaining, is essential for proper classification and management. Surgical intervention combined with adjuvant therapy remains the mainstay of treatment, while emerging evidence suggests potential benefit from immunotherapy. Continued documentation and reporting of ISMC cases will be crucial to deepen our understanding of its clinical behavior and guide future therapeutic strategies.

Funding

This study was funded by the National Key R&D Program of Ningxia Hui Autonomous Region (grant 2022BEG01003).

Ethics Approval

This case report was written with Ning xia people hospital of Medical sciences Ethics Committee approval.

Consent for Publication

Hereby, authors declare no conflict of interest

Authors' Contribution

All of the authors contributed to writing and preparing the manuscript.

Ethical Statement

Written consent form was obtained from the patient.

References

1. Bray, F., Laversanne, M., Sung, H., Ferlay, J., Siegel, R. L., Soerjomataram, I., & Jemal, A. (2024). Global cancer statistics 2022: GLOBOCAN estimates of incidence and mortality worldwide for 36 cancers in 185 countries. *CA: A Cancer Journal for Clinicians*, 74(3), 229–263. <https://doi.org/10.3322/caac.21790>
2. Siegel, R. L., Giaquinto, A. N., & Jemal, A. (2024). Cancer statistics, 2024. *CA: A Cancer Journal for Clinicians*, 74(1), 12–49. <https://doi.org/10.3322/caac.21763>
3. Stolnicu, S., Barsan, I., Hoang, L., Park, K. J., Oliva, E., Soslow, R. A., ... & Ronnett, B. M. (2018). International endocervical adenocarcinoma criteria and classification (IECC): A new pathogenetic classification for invasive adenocarcinomas of the endocervix. *American Journal of Surgical Pathology*, 42(2), 214–226. <https://doi.org/10.1097/PAS.0000000000000986>
4. Lastra, R. R., Park, K. J., & Schoolmeester, J. K. (2016). Invasive stratified mucin-producing carcinoma and stratified mucin-producing intraepithelial lesion (SMILE): 15 cases presenting a spectrum of cervical neoplasia with description of a distinctive variant of invasive adenocarcinoma. *American Journal of Surgical Pathology*, 40(2), 262–269. <https://doi.org/10.1097/PAS.0000000000000530>
5. Kurman, R. J., Carcangiu, M. L., Herrington, S. C., & Young, R. H. (Eds.). (2020). WHO classification of tumors of female reproductive organs (5th ed., pp. 367–371). Lyon, France: International Agency for Research on Cancer.
6. Onishi, J., Sato, Y., Sawaguchi, A., Tanaka, M., Inoue, T., & Kudo, R. (2016). Stratified mucin-producing intraepithelial lesion with invasive carcinoma: 12 cases with immunohistochemical and ultrastructural findings. *Human Pathology*, 55, 174–181. <https://doi.org/10.1016/j.humpath.2016.04.018>
7. Choi, S., Kim, S. W., & Kim, H. S. (2021). Invasive stratified mucin-producing carcinoma (ISMC) of the uterine cervix: Clinicopathological and molecular characteristics with special emphasis on the first description of consistent programmed death-ligand 1 (PD-L1) overexpression. *Cancer Genomics & Proteomics*, 18(5), 685–698. <https://doi.org/10.21873/cgp.20290>