

Management of a Large Radicular Cyst in the Maxillary Anterior Region Using Decompression: A Case Report

Jaspreet Kaur¹, Navjot Singh Khurana², Jagvinder Singh Mann³, Naveen Prasath D⁴, Tamanna⁵ & Prajjawal Gahlot^{6*}

¹PG Student, Department of Conservative Dentistry and Endodontics, Government Dental College and Hospital, Patiala, Punjab, India.

²Assistant Professor, Department of Conservative Dentistry and Endodontics, Government Dental College and Hospital, Patiala, Punjab, India

³Professor and Head, Department of Conservative Dentistry and Endodontics, Government Dental College and Hospital, Patiala, Punjab, India

⁴PG Student, Department of Conservative Dentistry and Endodontics, Government Dental College and Hospital, Patiala, Punjab, India

⁵PG Student, Department of Conservative Dentistry and Endodontics, Government Dental College and Hospital, Patiala, Punjab, India

⁶Intern, Government Dental College and Hospital, Jaipur, Rajasthan, India

***Corresponding author:** Dr. Prajjawal Gahlot, Intern Government Dental College Hospital, Jaipur, Rajasthan, India. Email: prajjwal.gahlot@gmail.com

Submitted: 24 September 2025 **Accepted:** 30 September 2025 **Published:** 06 October 2025

doi <https://doi.org/10.63620/MKJCDOC.2025>.

Citation: Kaur, J., Khurana, N. S., Mann, J. S., Prasath, N. D., Bhagat, T., & Gahlot, P. (2025). Management of a Large Radicular Cyst in the Maxillary Anterior Region Using Decompression: A Case Report. *J of Clin Den & Oral Care*, 3(5), 01-05.

Abstract

Radicular cysts are the most common odontogenic cysts of inflammatory origin and are frequently associated with non-vital teeth. While many resolve with conventional root canal therapy, larger lesions may require surgical intervention. Decompression is a conservative alternative to enucleation that reduces intracystic pressure, promoting gradual shrinkage and bone regeneration. This case report describes the management of a large radicular cyst in the maxillary anterior region of a 29-year-old male with a history of trauma and previously initiated root canal therapy. Clinical and radiographic findings revealed non-vital teeth (#11, #12, #13) and a well-defined periapical radiolucency (~13 mm) with labial cortical plate perforation. Persistent exudation despite multiple intracanal medicaments suggested a true cystic lesion. Decompression was performed using a Foley catheter, maintained with daily irrigation until progressive regression was achieved. Definitive treatment included apexification of tooth #12 with Mineral Trioxide Aggregate (MTA) and thermoplasticized gutta-percha obturation. Given the extensive coronal loss, tooth #12 was restored using fiber-reinforced composite (Ribbond) for improved strength. At 12-month follow-up, clinical and radiographic evaluation confirmed resolution of the lesion and re-establishment of normal trabecular architecture. This case demonstrates decompression as a simple and effective conservative technique for large radicular cysts, enabling lesion regression and successful healing while avoiding enucleation.

Keywords: Radicular Cyst, Decompression, Periapical Lesion, Cone-Beam Computed Tomography (CBCT), Mineral Trioxide Aggregate (MTA), Fiber-Reinforced Composite.

Introduction

Radicular cysts are the most common odontogenic cysts of inflammatory origin. Histologically, they are characterized by an epithelium-lined cavity and are typically associated with one or more non-vital teeth. Lesions exceeding 1.5 cm in diameter are often identified radiographically as well-defined radiolucent areas with thin radiopaque borders. These cysts arise secondary to pulpal necrosis and subsequent periapical inflammation, typically of infectious etiology. Non-surgical healing of large periapical

lesions is possible when the source of infection is thoroughly eliminated, allowing the body's natural reparative mechanisms to restore the affected tissues. Accordingly, non-surgical root canal therapy (RCT) remains the first-line treatment modality for radicular cysts, frequently resulting in resolution of the periapical pathology [1].

However, in cases where conservative endodontic therapy fails to induce regression of the lesion, surgical intervention may be necessary. Surgical options include decompression, enucleation,

or incision and drainage [2]. Among these, decompression is a minimally invasive surgical technique often employed in the management of large periapical cysts. It involves the creation of a small window in the cyst wall and the placement of a stent-like device—such as a polyethylene drain, rubber dam segment, or metal tube—to maintain patency. This allows for gradual decompression by reducing the internal hydrostatic pressure, thereby promoting shrinkage of the cystic cavity and encouraging bone regeneration.

If decompression alone fails to achieve adequate resolution, surgical enucleation is generally indicated as a definitive treatment to fully remove the cystic lesion and minimize the risk of recurrence [3]. This article presents a case report of a radicular cyst involving the maxillary anterior teeth that was successfully treated with decompression alone, without the need for enucleation.

Case Report

A 29-year-old male patient with no relevant medical history presented to the Department of Conservative Dentistry and Endodontics with a complaint of swelling in the maxillary right anterior region. The patient reported a history of dental trauma approximately 20 years prior and a previously initiated root canal treatment performed at a private clinic.

Clinical Examination

Intraoral examination revealed obliteration of the labial vestibule and a fluctuant swelling in relation to tooth #12 (maxillary right lateral incisor) [fig.1(b)]. Teeth #11 (central incisor), #12 (lateral incisor), and #13 (canine) were non-responsive to cold pulp testing and exhibited tenderness on percussion. Mild mobility was noted with tooth #12, while periodontal probing depths remained within normal limits.

Radiographic And Cbct Assessment

Radiovisiographic (RVG) imaging indicated evidence of a prior root canal treatment in tooth #12, with an immature apex and a well-defined periapical radiolucency suggestive of a chronic periapical lesion as visible in fig.1a. Further evaluation using cone-beam computed tomography (CBCT) revealed a unilocular, well-demarcated periapical radiolucency measuring $12.5 \times 13.3 \times 13.1$ mm, extending from tooth #11 to #13 and involving the nasal floor. Erosion of the labial cortical plate and expansion of the palatal cortical plate were noted. No root resorption was observed. [Fig. 1 c&d]

A diagnosis of pulpal necrosis with chronic periapical abscess was established, and non-surgical root canal treatment was planned for teeth #11, #12, and #13.

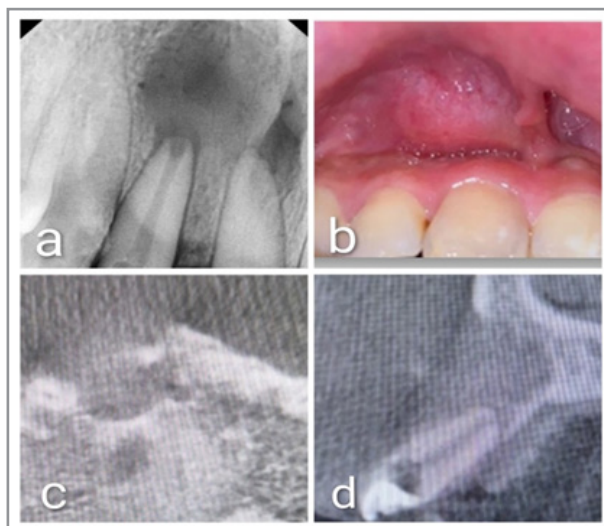


Figure 1 a) Radiograph of 11, 12 regions which reveal radiolucency involving periapical region b) Picture showing swelling in labial vestibule region c) Cbct image axial view showing bone loss d) Cbct image Saggital view showing bone loss involving labial plate

Endodontic Procedure

Following administration of local anesthesia, working length was determined for tooth #12, and access openings were completed for teeth #11 and #13. Biomechanical preparation was carried out for all three teeth using the following irrigation protocol:

- Initial irrigation with sodium hypochlorite, activated ultrasonically for 20 seconds
- Intermediate rinse with normal saline
- Irrigation with 17% EDTA, followed by ultrasonic activation for 20 seconds
- Final rinse with normal saline

An exudative discharge from the canals indicated persistent intracanal infection. Aspiration using a sterile syringe yielded purulent fluid, further confirming the presence of an active in-

fection.

Intracanal Medicament Protocol

A calcium hydroxide intracanal dressing was placed, using 2% chlorhexidine as the vehicle to enhance antimicrobial efficacy. The medicament was replaced weekly for two sessions. At the third visit, persistent exudation was still noted. As a result, a Double Antibiotic Paste (DAP) comprising 500 mg ciprofloxacin and 500 mg metronidazole was introduced and retained in the canal for 21 days. Despite this, clinical signs of infection persisted at the fourth visit.

Surgical Intervention – Decompression

Given the persistence of symptoms, two surgical options—enucleation and decompression—were discussed with the patient. After being informed of the benefits and limitations of each, the

patient opted for decompression due to its conservative nature and lower postoperative morbidity.

Under local anesthesia, a vertical incision was made at the most dependent point of the swelling. Serosanguinous fluid was drained, and the cystic cavity was irrigated with 50 mL of sterile saline. A trimmed, sterile segment of a Foley catheter was inserted into the lesion to facilitate continuous decompression. The catheter was stabilized by suturing the surrounding soft tissue to

form a collar-like seal. Postoperative instructions included daily irrigation of the cavity using 0.2% chlorhexidine and a 5cc syringe [4]. Sutures were removed after one week.

During follow-up visits, the catheter was gradually trimmed and withdrawn as clinical and radiographic evidence indicated progressive lesion regression. By the two-month follow-up, the catheter was completely removed, leaving a small residual mucosal defect.

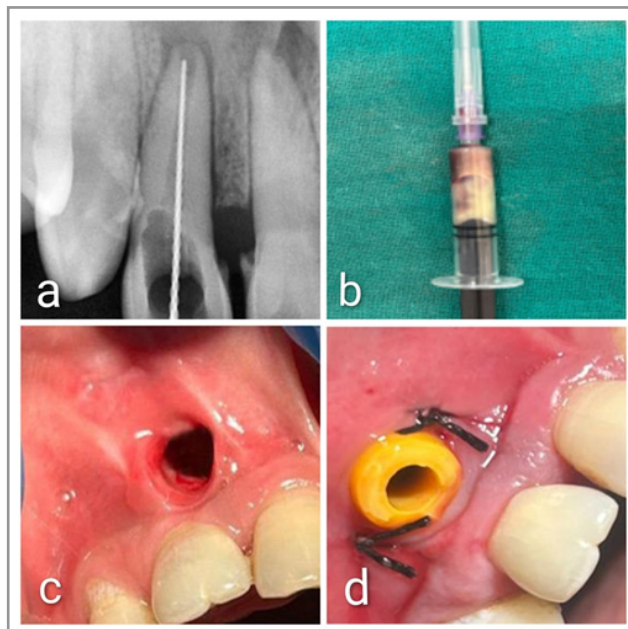


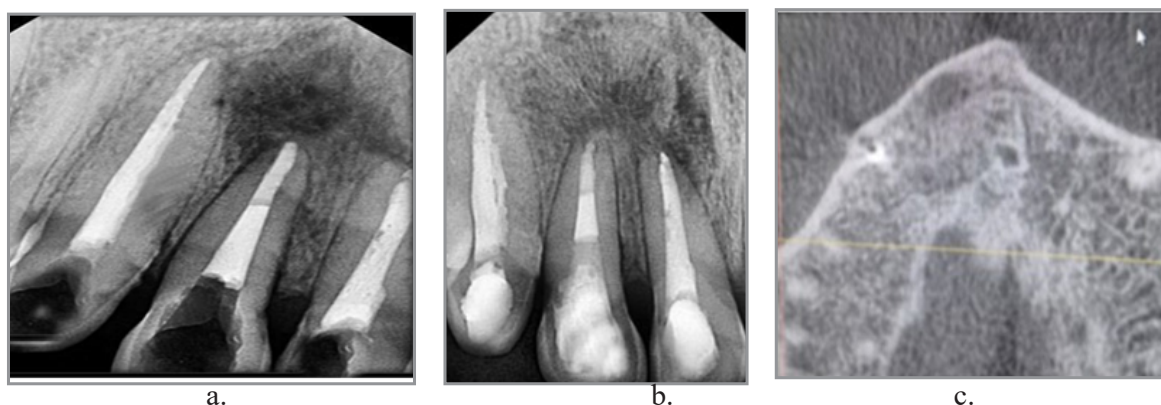
Figure 2: a) working length determination b) syringe filled of pus drained from sinus c) Picture of the clinical appearance of the channel d) Insertion and stabilization of drain by interrupted suture

Definitive Root Canal Treatment and Restoration

With the resolution of active infection and the absence of purulent discharge, obturation was performed. An apical barrier was established in tooth #12 using Mineral Trioxide Aggregate (MTA), followed by thermoplasticized gutta-percha obturation to ensure a hermetic seal. Tooth #12 was restored using a fibre-reinforced composite (FRC) technique employing Ribbond fibres, given the extensive loss of tooth structure due to the large access preparation. The use of polyethylene fibre reinforcement was chosen to enhance fracture resistance and improve the structural integrity of the restored tooth [5-6].

Follow-Up and Outcome

At the 1-month post-decompression recall, soft tissue healing was clinically evident. A CBCT scan at 6 months demonstrated significant reduction in lesion size and improved trabecular bone density surrounding the involved teeth. At the 12-month follow-up, radiographic evaluation confirmed further resolution of the lesion, with the formation of well-organized bone architecture and complete clinical healing, leaving behind a residual soft tissue scar.



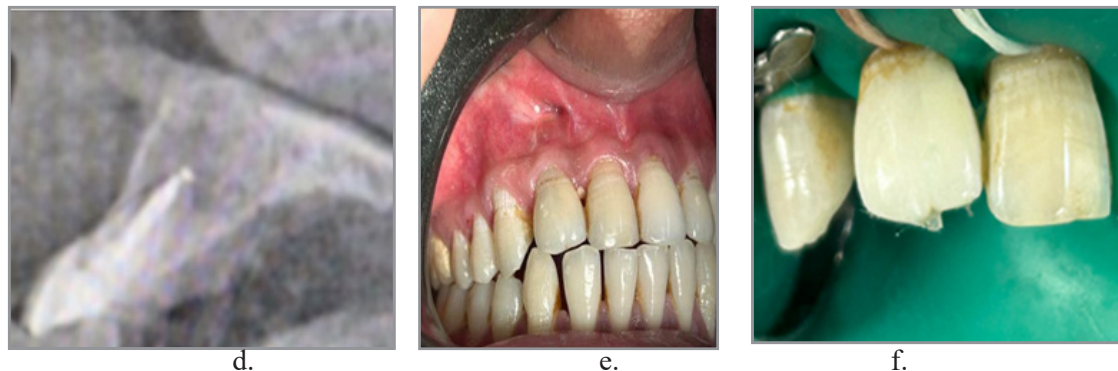


Figure 3: a) apical barrier of MTA, followed by thermoplasticized gutta-percha obturation b) 12 month follow up c&d) CBCT scan after 6 month showing healing e) Postoperative photograph showing healing with scar formation at the decompression site f) restored tooth

Discussion

Radicular cysts represent the most common type of inflammatory odontogenic cysts, typically developing as a chronic consequence of pulpal necrosis and periapical inflammation. While smaller lesions often resolve following conventional non-surgical root canal treatment, larger or persistent cystic lesions may necessitate adjunctive surgical intervention for complete resolution [7].

In the present case, the patient exhibited a large periapical radiolucency associated with an immature maxillary lateral incisor and persistent exudation despite multiple sessions of intracanal medicaments, including calcium hydroxide with chlorhexidine and a double antibiotic paste (DAP). This clinical presentation strongly indicated the presence of a true cystic lesion unlikely to resolve with non-surgical measures alone. As supported by current literature, periapical lesions exceeding a critical size or demonstrating resistance to conservative intracanal disinfection may be best managed through decompression or surgical enucleation [8].

In this case, decompression was chosen due to its conservative nature and lower postoperative morbidity compared to enucleation. The technique facilitates a gradual reduction in cyst size by relieving intracystic pressure, thereby promoting bone regeneration while preserving adjacent anatomical structures [9]. A Foley catheter was utilized as the decompression device, in accordance with existing literature supporting its effectiveness in maintaining patency, promoting drainage, and improving patient compliance [10].

The mechanism of decompression involves reducing internal pressure within the cystic cavity, thereby inhibiting further expansion. Once the stimulatory factors for cyst growth are eliminated, the epithelial lining undergoes atrophy, osteoclastic activity subsides, and bone regeneration is initiated [11].

Over a two-month period, progressive reduction in lesion dimensions was observed, allowing for removal of the decompression device and completion of endodontic therapy. Mineral Trioxide Aggregate (MTA) was selected for apexification in tooth #12 due to its superior sealing ability, biocompatibility, and ability to induce hard tissue formation in immature teeth with open apices [12]. Thermoplasticized obturation was then employed to ensure

a homogenous, three-dimensional seal of the root canal system. Given the significantly compromised coronal tooth structure, a fiber-reinforced composite (FRC) restoration incorporating Ribbond fibres was utilized to enhance fracture resistance and provide structural reinforcement. This approach is supported by evidence suggesting improved mechanical strength in endodontically treated teeth restored with fiber reinforcement.

Follow-up CBCT evaluation at 12 months demonstrated a marked reduction in lesion size with improved trabecular bone density and re-establishment of normal periapical architecture. Continued bone maturation and radiographic healing were evident at the 26-month review, confirming the long-term success of the decompression technique.

This case underscores the clinical efficacy of decompression as a minimally invasive treatment modality for large radicular cysts. Success is contingent on proper case selection, patient compliance, and regular follow-up. Additionally, integration of effective disinfection protocols and the use of biocompatible materials such as MTA significantly contribute to favorable treatment outcomes.

Conclusion

Decompression is a simple, conservative, and effective surgical technique that can facilitate the healing of large periapical cystic lesions while preserving surrounding anatomical structures. By reducing lesion size and internal pressure, it can either lead to complete resolution or create favorable conditions for less invasive surgical management, if necessary. In select cases, as demonstrated here, decompression may eliminate the need for surgical enucleation altogether. Careful monitoring, adherence to disinfection protocols, and appropriate restorative strategies are essential for long-term clinical success.

Declarations

Consent for Publication

Not applicable

Funding

This research received no external funding.

Conflict of Interests

The authors declare that they have no conflict of interests.

Acknowledgements

The authors express their sincere gratitude to the patient for his cooperation and compliance, which greatly contributed to the successful completion of this study. We extend our special thanks to the staff of the Department of Endodontics for their invaluable assistance throughout the treatment process. We are also deeply appreciative of the Department of Oral Medicine and Radiology for their guidance and support in providing the CBCT scans essential to this case.

References

1. Nair, P. N. (1998). New perspectives on radicular cysts: Do they heal? *International Endodontic Journal*, 31(3), 155–160.
2. Shear, M., & Speight, P. M. (2007). *Cysts of the oral and maxillofacial regions* (4th ed.). Blackwell Munksgaard.
3. Tandri, S. B. (2010). Management of infected radicular cyst by surgical decompression. *Journal of Conservative Dentistry*, 13(3), 159–161.
4. Umer, F., & Javed, F. (2021). Decompression strategy for critical-sized lesions: A case series and literature review. *Australian Endodontic Journal*, 47(3), 731–740.
5. Belli, S., Erdemir, A., Ozcopur, M., & Eskitascioglu, G. (2005). The effect of fibre insertion on fracture resistance of root filled molar teeth with MOD preparations restored with composite. *International Endodontic Journal*, 38(2), 73–80.
6. Garoushi, S., Lassila, L. V., Tezvergil, A., & Vallittu, P. K. (2006). Load bearing capacity of fibre-reinforced and particulate filler composite resin combination. *Journal of Dentistry*, 34(3), 179–184.
7. Ricucci, D., & Siqueira, J. F., Jr. (2010). Biofilms and apical periodontitis: Study of prevalence and association with clinical and histopathologic findings. *Journal of Endodontics*, 36(8), 1277–1288.
8. Neaverth, E. J., et al. (1982). [Full details missing—please provide article title, journal, volume, issue, and pages for APA formatting].
9. Nakamura, N., Higuchi, Y., Mitsuyasu, T., Sandra, F., & Ohishi, M. (2002). Comparison of long-term results between different approaches to ameloblastoma. *Oral Surgery, Oral Medicine, Oral Pathology, Oral Radiology, and Endodontics*, 93(1), 13–20.
10. Tian, F. C., Bergeron, B. E., Kalathingai, S., Morris, M., Wang, X. Y., Niu, L. N., & Tay, F. R. (2019). Management of large radicular lesions using decompression: A case series and review of the literature. *Journal of Endodontics*, 45(5), 651–659.
11. Rowe, P., Koller, A., & Sharma, S. (2023). Physiology, bone remodeling. In *StatPearls*. StatPearls Publishing. <https://www.ncbi.nlm.nih.gov/books/NBK499879/>
12. Torabinejad, M., & Chivian, N. (1999). Clinical applications of mineral trioxide aggregate. *Journal of Endodontics*, 25(3), 197–205.